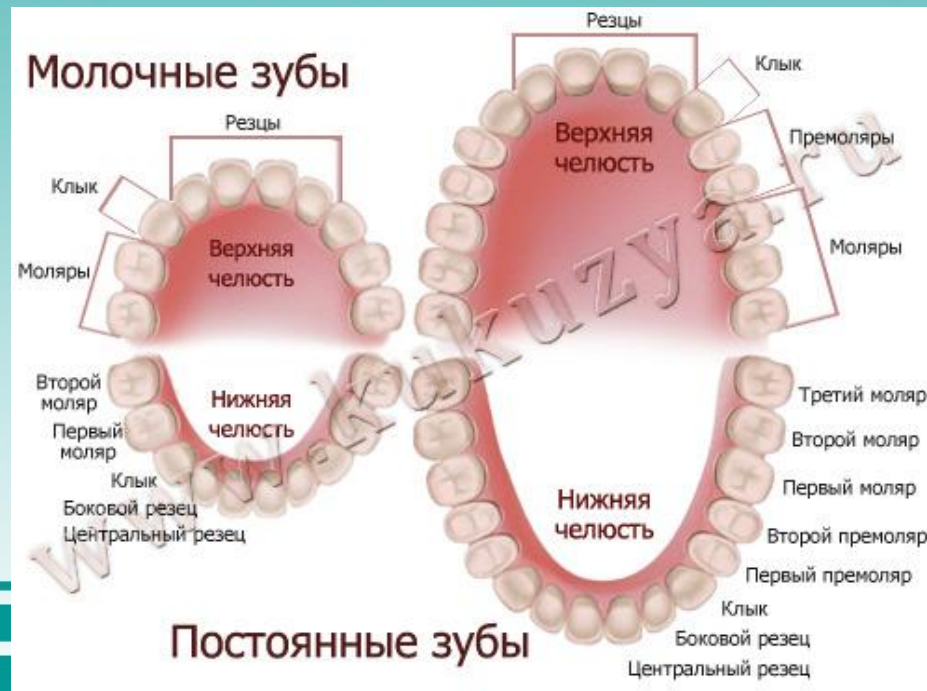


*The classification of the tooth .  
Согласование времен*



Подготовила: Утебаева А.М.  
2-007стом

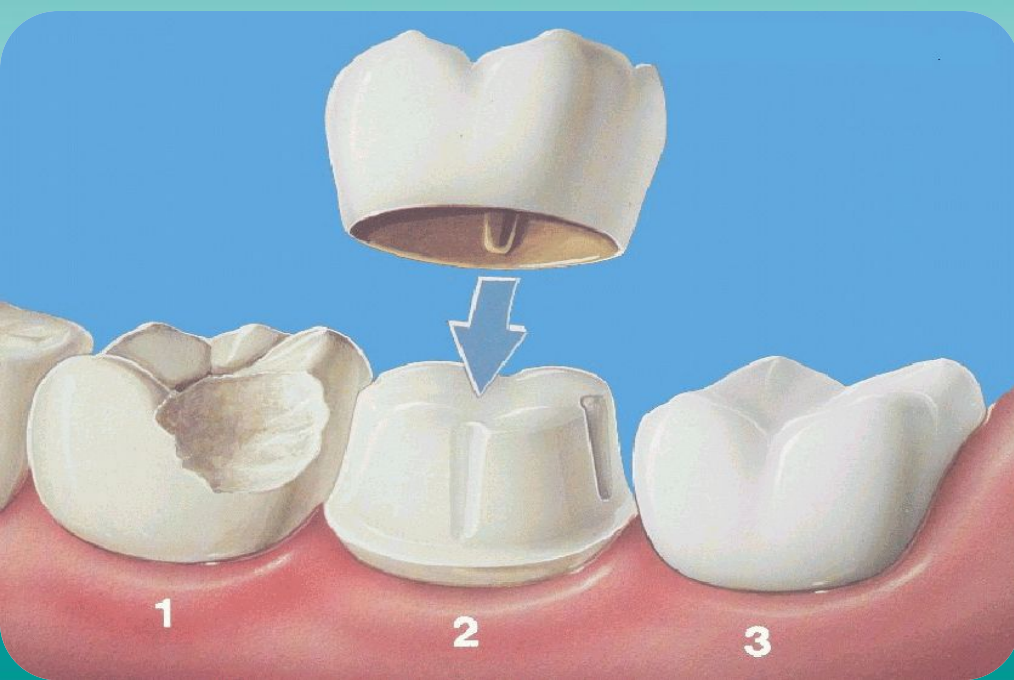
❖ Teeth of humans are small, calcified, whitish structures found in the mouth that are used to break down food. The roots of teeth are embedded in the maxilla (upper jaw) or the mandible (lower jaw) and are covered by gums. Teeth are made of multiple tissues of varying density and hardness.



- ❖ Teeth are among the most distinctive (and long-lasting) features of mammal species. Humans, like other mammals, are diphyodont, meaning that they develop two sets of teeth. The first set (also called the "baby", "milk", "primary", and "deciduous" set) normally starts to appear at about six months of age, although some babies are born with one or more visible teeth, known as neonatal teeth. Normal tooth eruption at about six months is known as teething and can be painful.



- ❖ The anatomic crown of a tooth is the area covered in enamel above the cemento-enamel junction (CEJ) or "neck" of the tooth. Most of the crown is composed of dentin (dentine in British English) with the pulp chamber inside. The crown is within bone before eruption. After eruption, it is almost always visible. The anatomic root is found below the CEJ and is covered with cementum. As with the crown, dentin composes most of the root, which normally have pulp canals. A tooth may have multiple roots or just one root (single-rooted teeth).



- Canines and most premolars, except for maxillary first premolars, usually have one root. Maxillary first premolars and mandibular molars usually have two roots. Maxillary molars usually have three roots. Additional roots are referred to as supernumerary roots. Humans usually have 20 primary (deciduous or "baby") teeth and 32 permanent (adult) teeth.



- Teeth are classified as incisors, canines, premolars, and molars. Incisors are primarily used for biting pieces from foods such as raw carrots or apples and peeled but uncut bananas, while molars are used primarily for grinding foods after they are already in bite size pieces inside the mouth. Most teeth have identifiable features that distinguish them from others. There are several different notation systems to refer to a specific tooth. The three most common systems are the FDI World Dental Federation notation, the universal numbering system, and Palmer notation method. The FDI system is used worldwide, and the universal is used widely in the United States.





- *Если глагол в главном предложении стоит в одном из прошедших времен, то и глагол придаточного предложения должен стоять в одном из прошедших времен.  
Пользуйтесь следующей схемой:*



*Время в прямой речи*

*Время в косвенной речи*

Present Indefinite



Past Indefinite

Present Continuous



Past Continuous

Present Perfect



Past Perfect

Past Indefinite



Past Perfect

Past Perfect



Past Perfect

Future Indefinite



Future Indefinite in the  
Past





*Глагол в прямой речи*

*Глагол в косвенной речи*

Am , is



Was

Are



Were

Have, has



Had

Can



Could

Will



Would

Do, does



Did

Look



Looked

Tell



Told

В подобных случаях возможны три основных варианта:

1 . Действие придаточного предложения происходит одновременно с действием главного предложения: в этих случаях глагол придаточного предложения стоит в Simple Past либо в Past Continuous. (одновременность)

*Я знал, что он каждый год ходит к стоматологу.  
I knew (that) he went to dentist every year.*



2. Действие придаточного предложения предшествует действию главного предложения: в подобных случаях в придаточном предложении употребляется Past Perfect. (предшествование)

Например:

*Я знал, что Билл ещё не успел прочесть моё письмо.*

*I knew (that) Bill had not time to read my letter.*



- . Действие придаточного предложения относится к будущему времени, а действие главного предложения - к прошедшему; при наличии подобной ситуации в придаточном предложении употребляется т.н. будущее в прошедшем Future in the Past. (следование)

Например:

*Я знал, что Билл придёт ко мне в поликлинику.*

*I knew (that) Bill would come to see me to hospital.*



*Thank you!!!*

