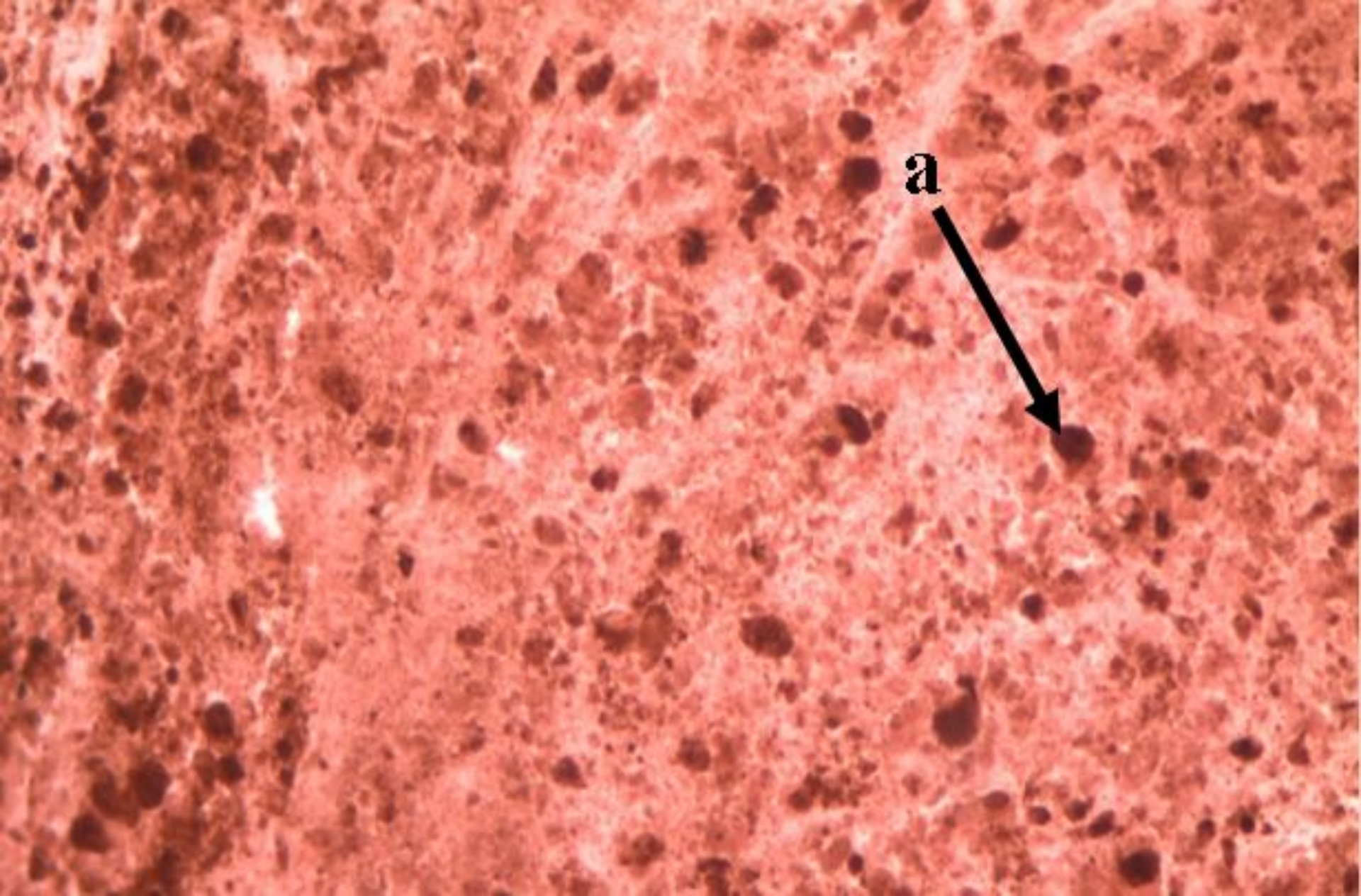


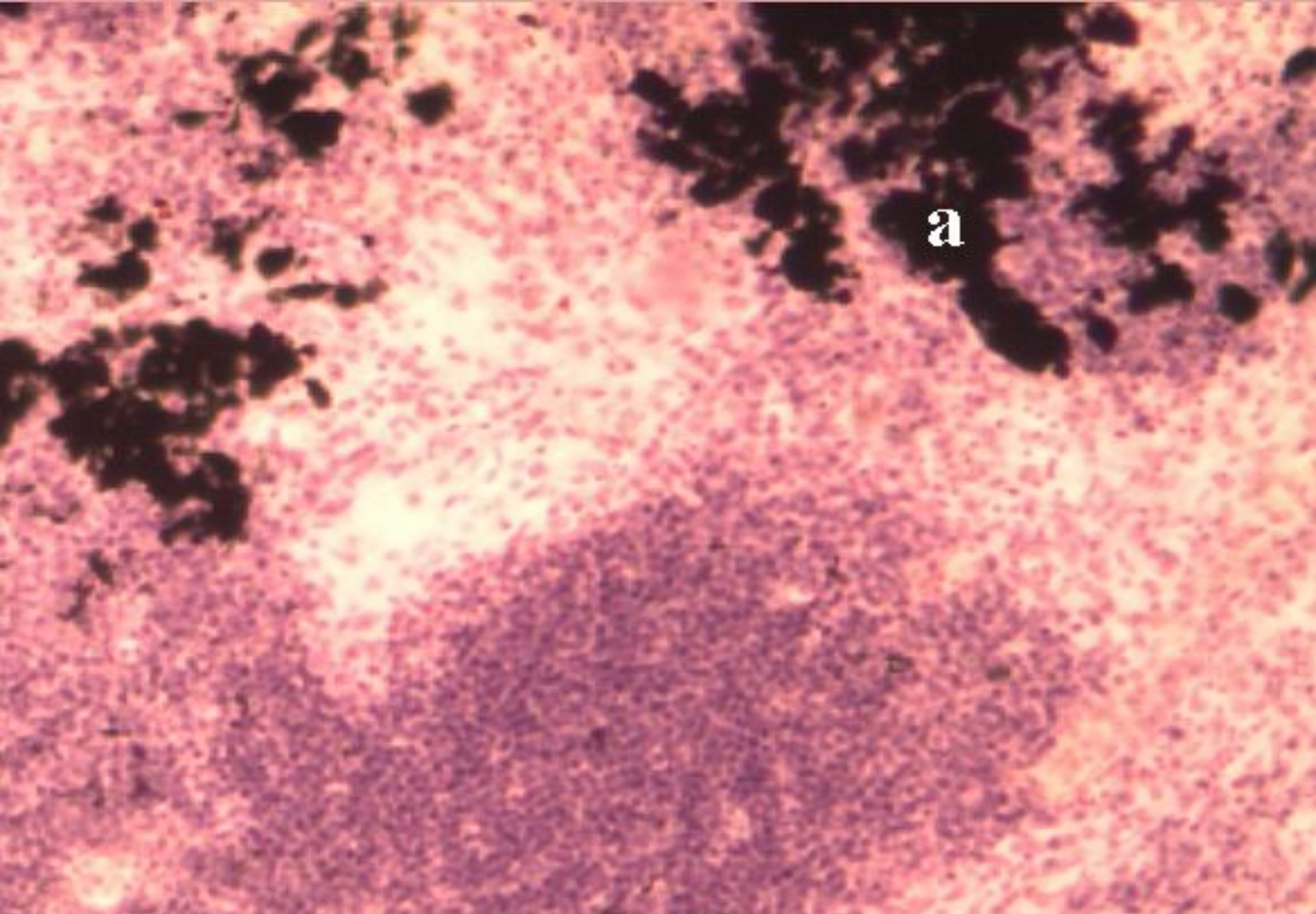
**Topic № 4. Disorders of nucleoproteids metabolism. Disorder of metabolism of haemoglobinogenic pigments. Disorder of metabolism of prtoteinonogenic pigments. Disorder of metabolism of lipidogenic pigments.**

**Prepared by  
d.m.s. Shabdarbaeva D.M.**



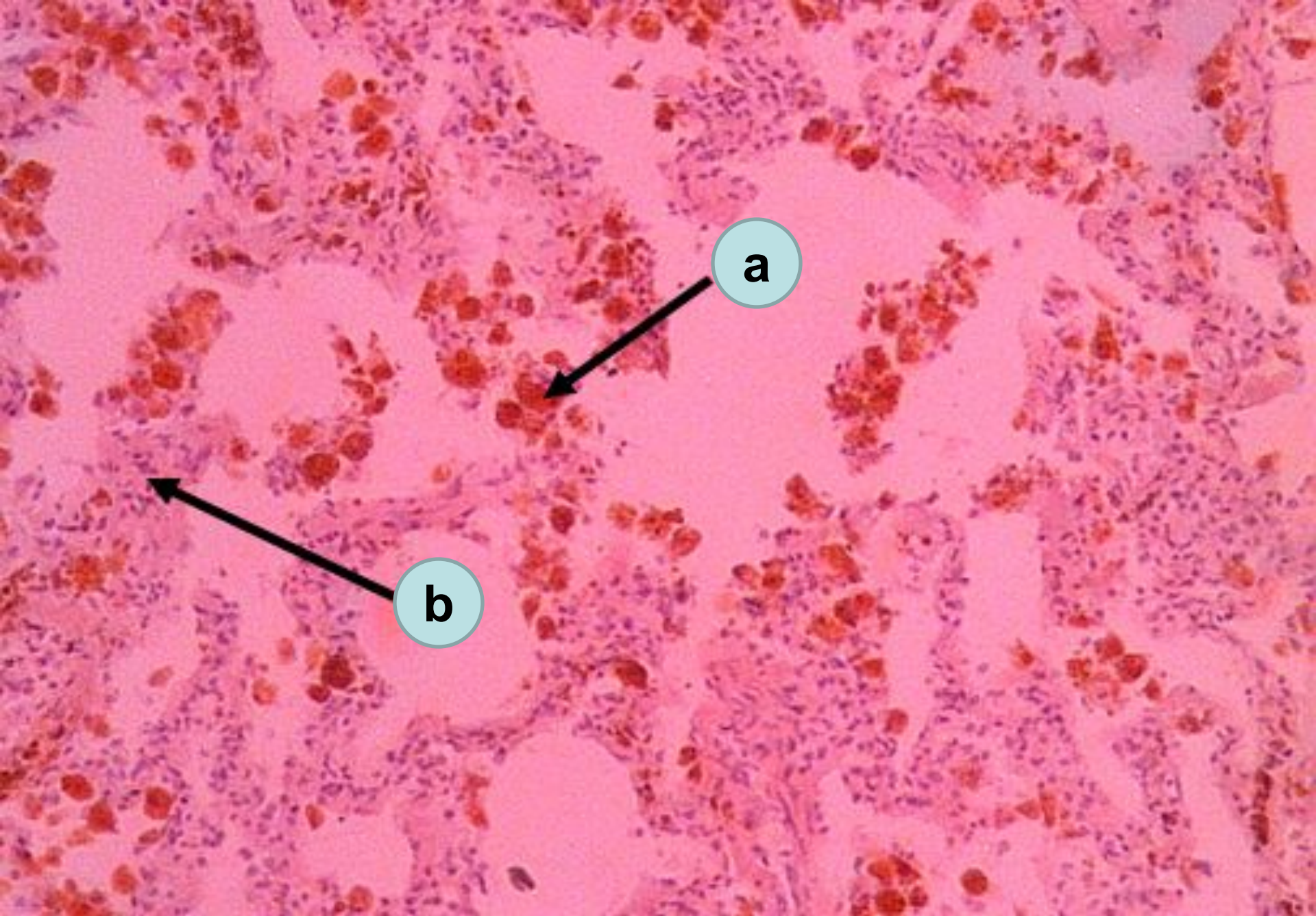
Melanoma  
a – granules of melanin





Anthracosis of lymph node  
a – black pigment (coal) in tissue of lymph node

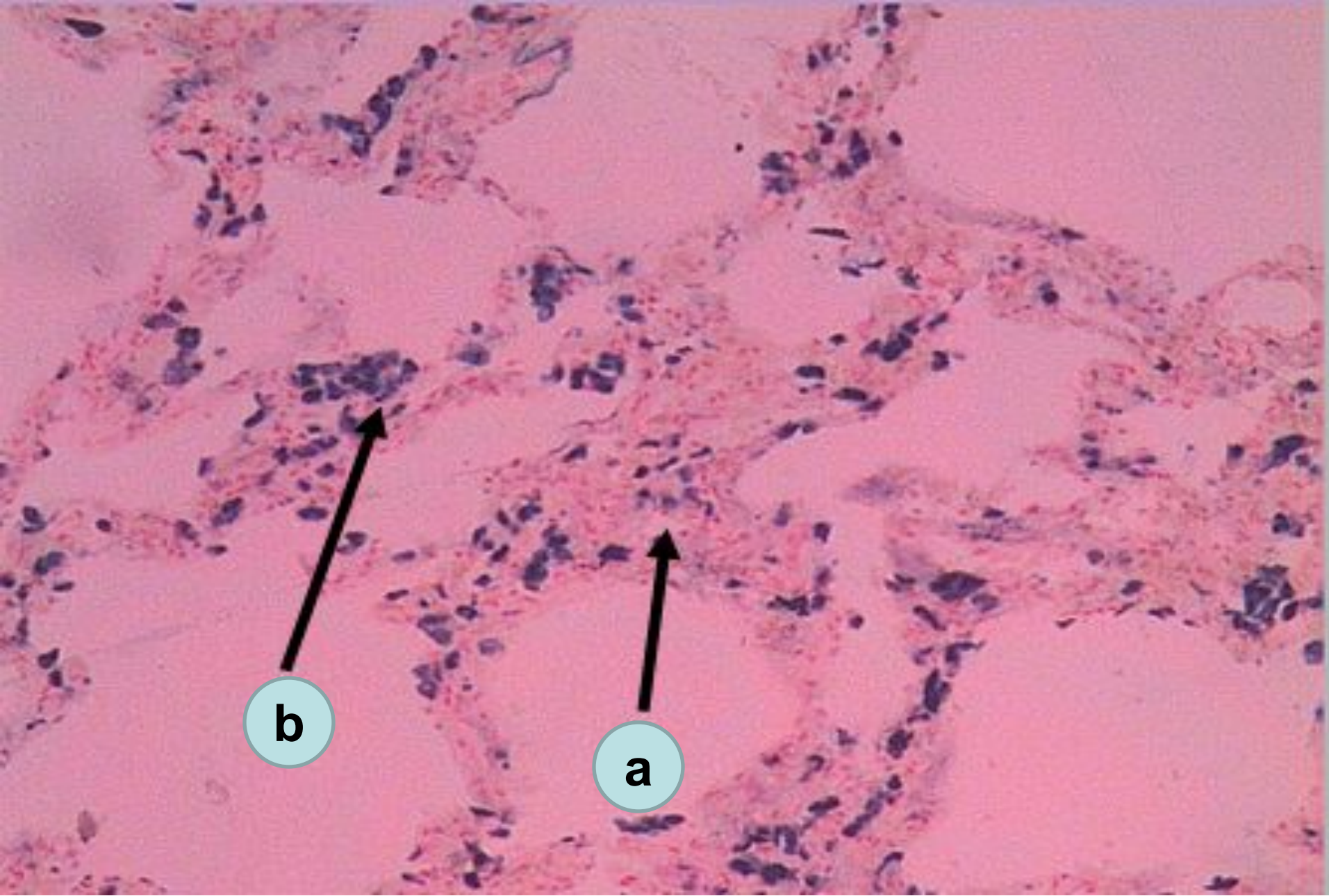




Brown induration of lungs

a – sideroblasts & siderophages; b – thickened interalveolar septa

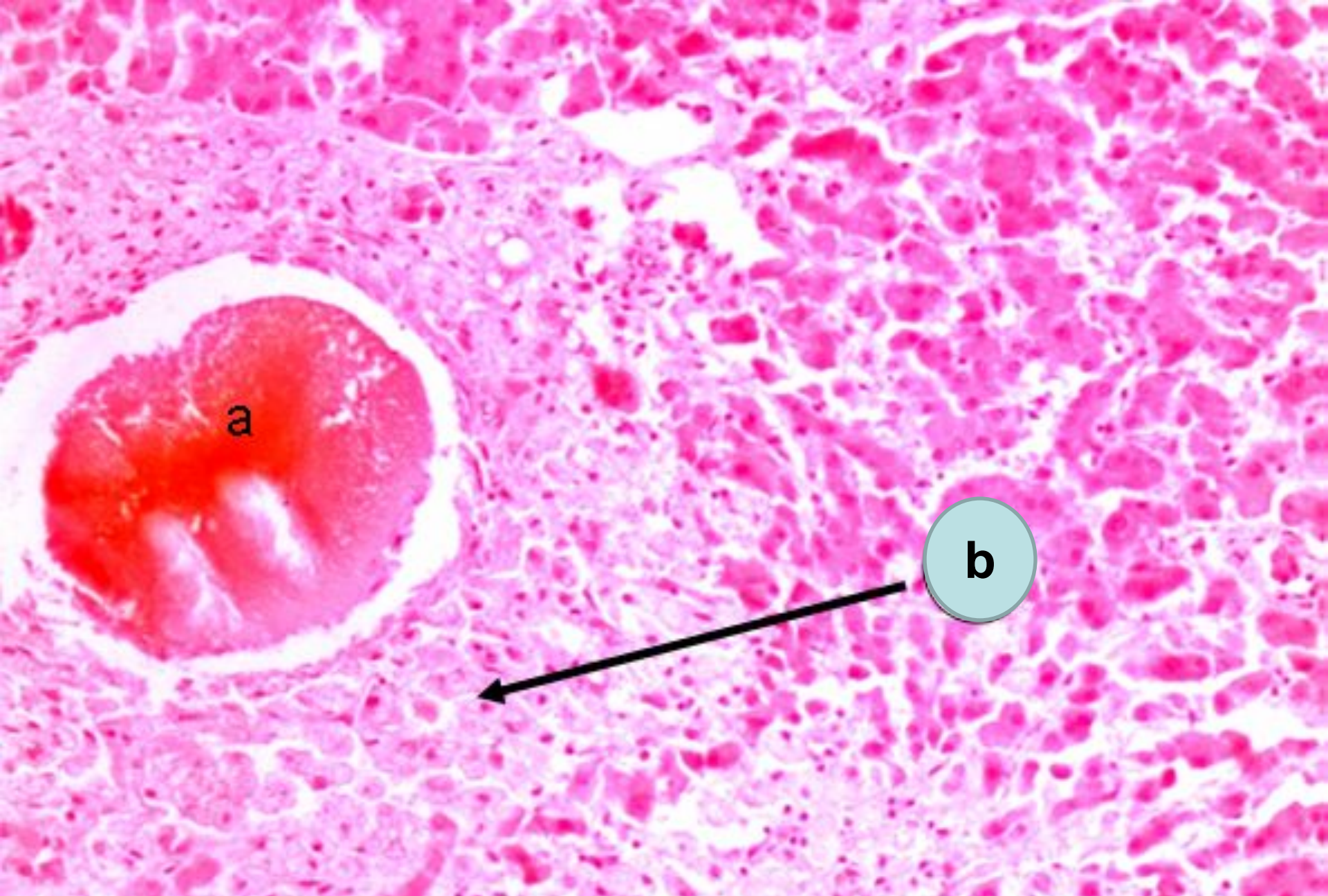




Brown induration of lungs (staining by Pearls)

a – thickened interalveolar septi; b – granules of hemosiderin (blue color)





**Liver in mechanical jaundice**  
**a – biliary thrombus; b – growth of connective tissue**