

# GI Hemorrhage

**Michael Libes, MD**

Senior Physician, Carmel Medical  
Center, Haifa



# LOWER GI BLEEDING

- Definition: LGIB is defined as bleeding from a source distal to the ligament of Treitz
- Incidence rate: 20.5 patients/ 100000/year

# LGI hemorrhage

- Sites
  - Colon – 95-97%
  - Small bowel – 3-5%
- Only 15% of massive GI bleeding
- Finding the site
  - Intermittent bleeding common
  - Up to 42% have multiple sites

# LGI hemorrhage

- Etiology
  - Diverticulosis – 40-55%
    - Right sided lesions > left
    - 90% stop spontaneously
    - 10% rebleed in 1<sup>st</sup> year and 25% at 4 years
  - Angiodysplasia – 3-20%
    - Most common cause of SB bleeding in >50 y/o
    - >50% are in right colon
  - Neoplasia
    - Typically bleed slowly
  - Inflammatory conditions
    - 15% of UC patients, 1% of chron's patients
    - Radiation, infectious, AIDS rarely
  - Vascular
  - Hemorrhoids
    - >50% have hemorrhoids, but only 2% of bleeding attributed to them
  - Others

# LGI hemorrhage diagnostics

Large caliber NGT on admission

- Colonoscopy

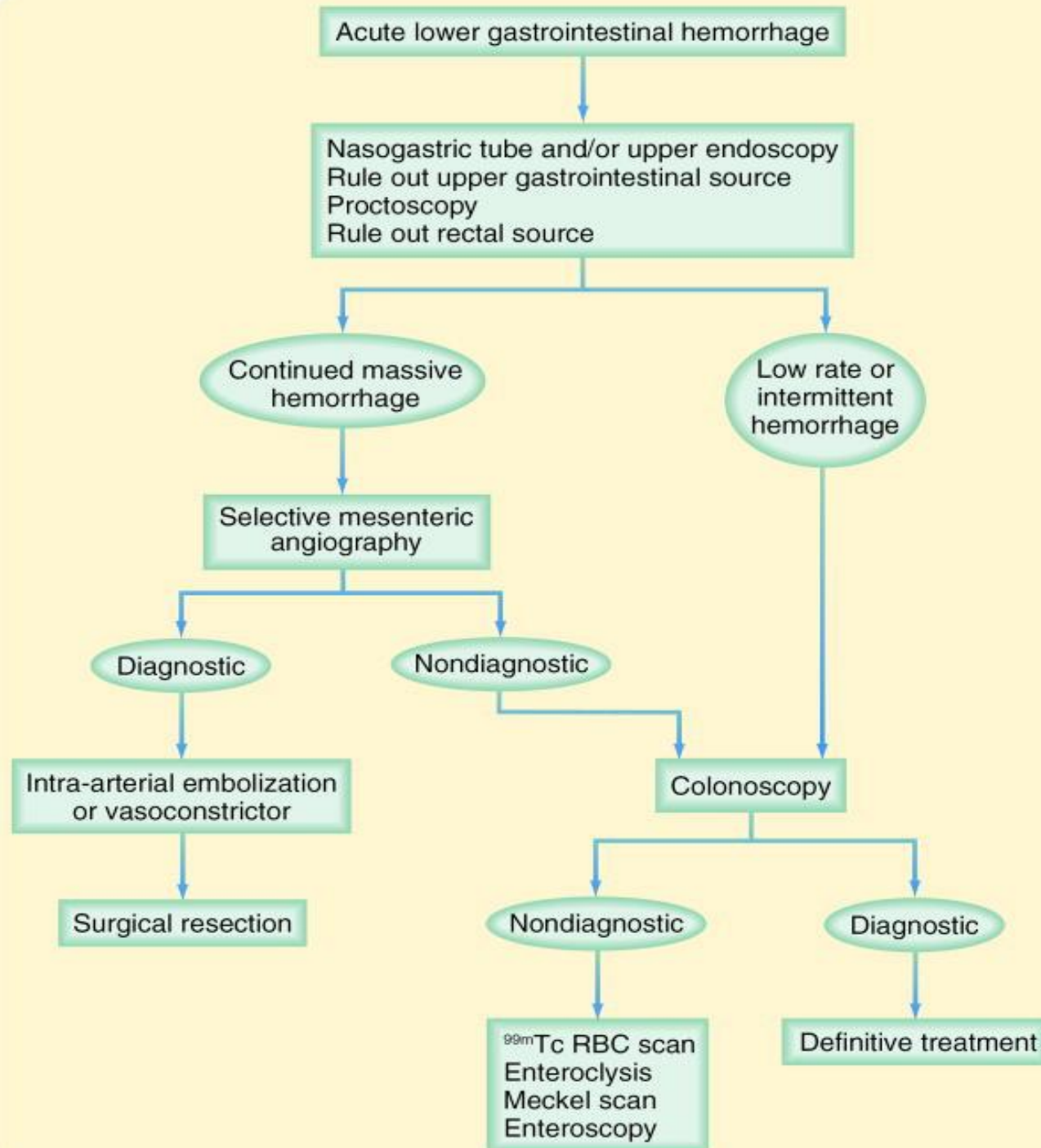
- Within 12 hours in stable patients without large amounts of bleeding

- Selective visceral angiography

- Need  $>0.5$  ml/min bleeding
- 40-75% sensitive if bleeding at time of exam

- Tagged RBC scan

- Can detect bleeding at 0.1 ml/min
- 85% sensitive if bleeding at time of exam
- Not accurate in defining left vs right colon



# CONCLUSION

- LGIB requires pre op localization to detect the bleeding source , including rectoscopy, colonoscopy, angography and nuclear scan.
- Interventional treatment by colonoscopy and selective angiographic catheterization and embolization shows good results and low bleeding rates.
- If an interventional therapy is not possible, a directed limited colonic or small bowel resection should be considered.

# CONCLUSION

- Positive pre op localization of bleeding results in limited colonic or small bowel resection when interventional therapy failed to stop bleeding.
- Negative pre op localization of bleeding site results in subtotal/total colectomy in massive low GI BLEEDING.