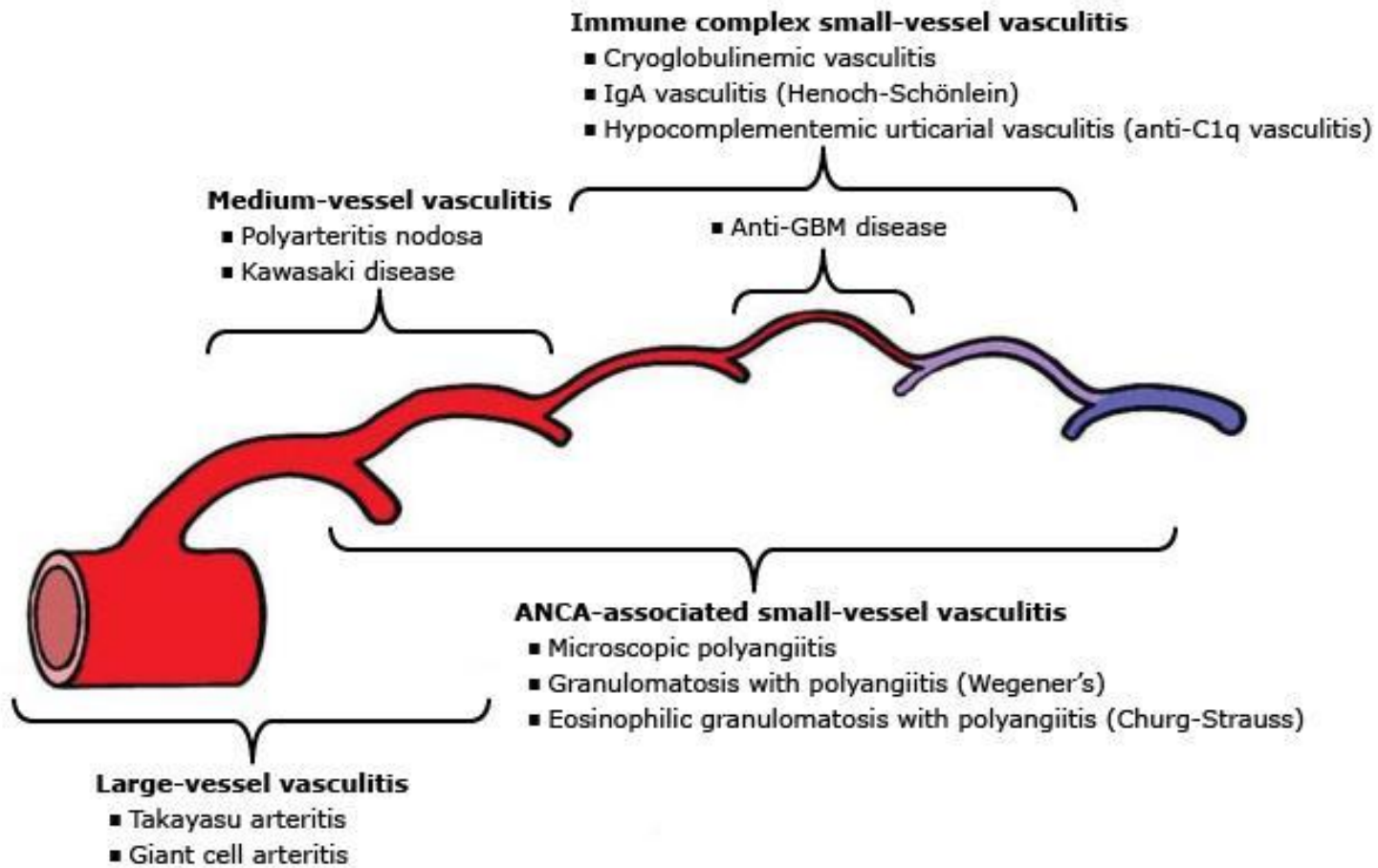


Giant cell arteritis

Dr Katya Dolnikov

D_katya@rambam.health.gov.il

2017



Introduction

- Giant cell arteritis (GCA) is categorized as a vasculitis of large- and medium-sized vessels
- Systemic symptoms are common in GCA and vascular involvement can be widespread
- Targeting of the muscular arteries from cranial branches of the aortic arch gives rise to the most characteristic symptoms of GCA
- The most feared complication of GCA, visual loss, is one potential consequence of such cranial arteritis



Epidemiology

- GCA is the most common systemic vasculitis
- The lifetime risk of developing GCA is ~1% in women and 0.5% in men
- The greatest risk factor for developing GCA is aging
- The disease almost never occurs before age 50
- Over 80 percent of patients are older than 70 years
- Ethnicity is a major risk factor for GCA. The highest incidence figures are found in Scandinavian countries
- F>M

Clinical findings

- The onset of symptoms tends to be subacute
- Abrupt presentations occurs less frequently
- Systemic symptoms are frequent and include fever, fatigue, and weight loss
- Fever occurs in up to one-half of patients with GCA and is usually low-grade
- In ~ 10% of patients constitutional symptoms and/or laboratory evidence of inflammation dominate the clinical presentation and can be the only clues to the diagnosis

Giant cell arteritis: clinical findings in 100 patients

Finding	Number
Sex (female/male)	69/31
Duration of manifestations before diagnosis	7*
Onset (gradual/sudden)	64/36
Weight loss or anorexia	50
Malaise, fatigue, or weakness	40
Fever	42
Polymyalgia rheumatica	39
Other musculoskeletal pains	30
Synovitis	15
Sore throat	9
Symptoms related to arteries	83
Headache	68
Visual symptoms	
Transient	16
Fixed	14
Jaw claudication	45
Swallowing claudication or dysphagia	8
Tongue claudication	6
Limb claudication	4
Signs related to arteries	66
Artery tenderness	27
Decreased temporal artery pulsations	46
Erythematous, nodular, or swollen scalp arteries	23
Large artery bruits	21
Decreased large artery pulses	7
Visual loss	14
Ophthalmoscopic abnormalities	18
Extraocular muscle weakness	2
Raynaud's phenomenon	3
Central nervous system abnormalities	15

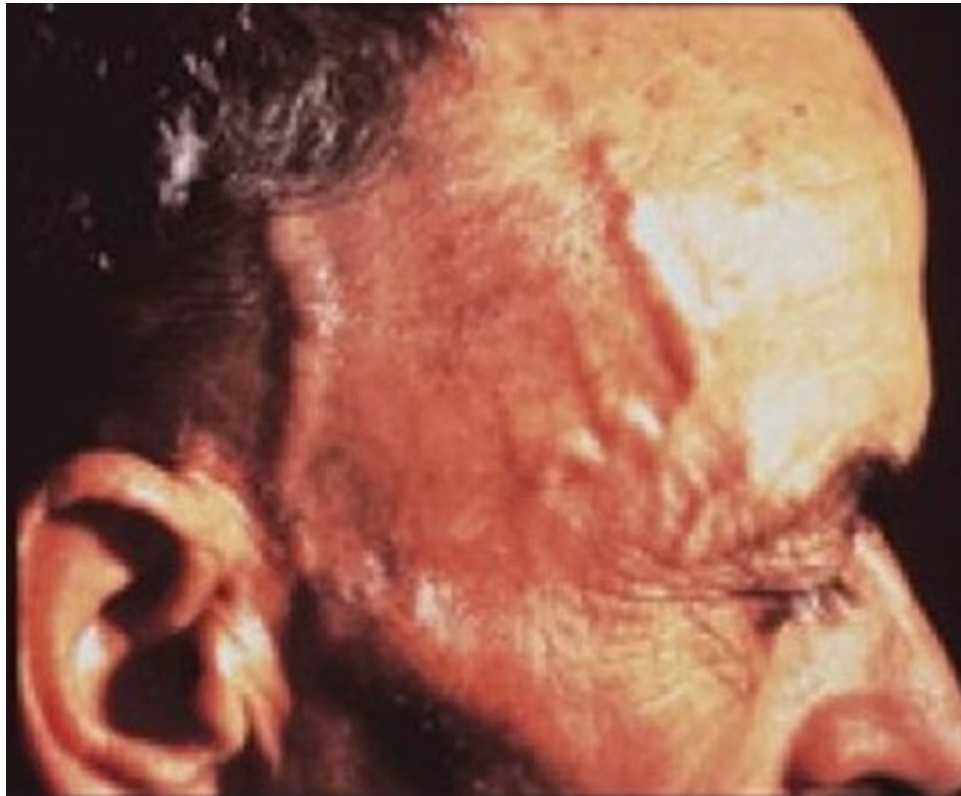* Range 1 to 48 months before diagnosis

Adapted from: Calamia, KT, Hunder, GG. *Clin Rheum Dis* 1980; 6:389.

Clinical findings - Headache

- Located over the temples, but can also be frontal or occipital or generalized
- The headaches can progressively worsen, or wax and wane, sometimes subsiding temporarily before treatment is started
- Tenderness of the scalp to touch

Temporal artery



Jaw Claudication

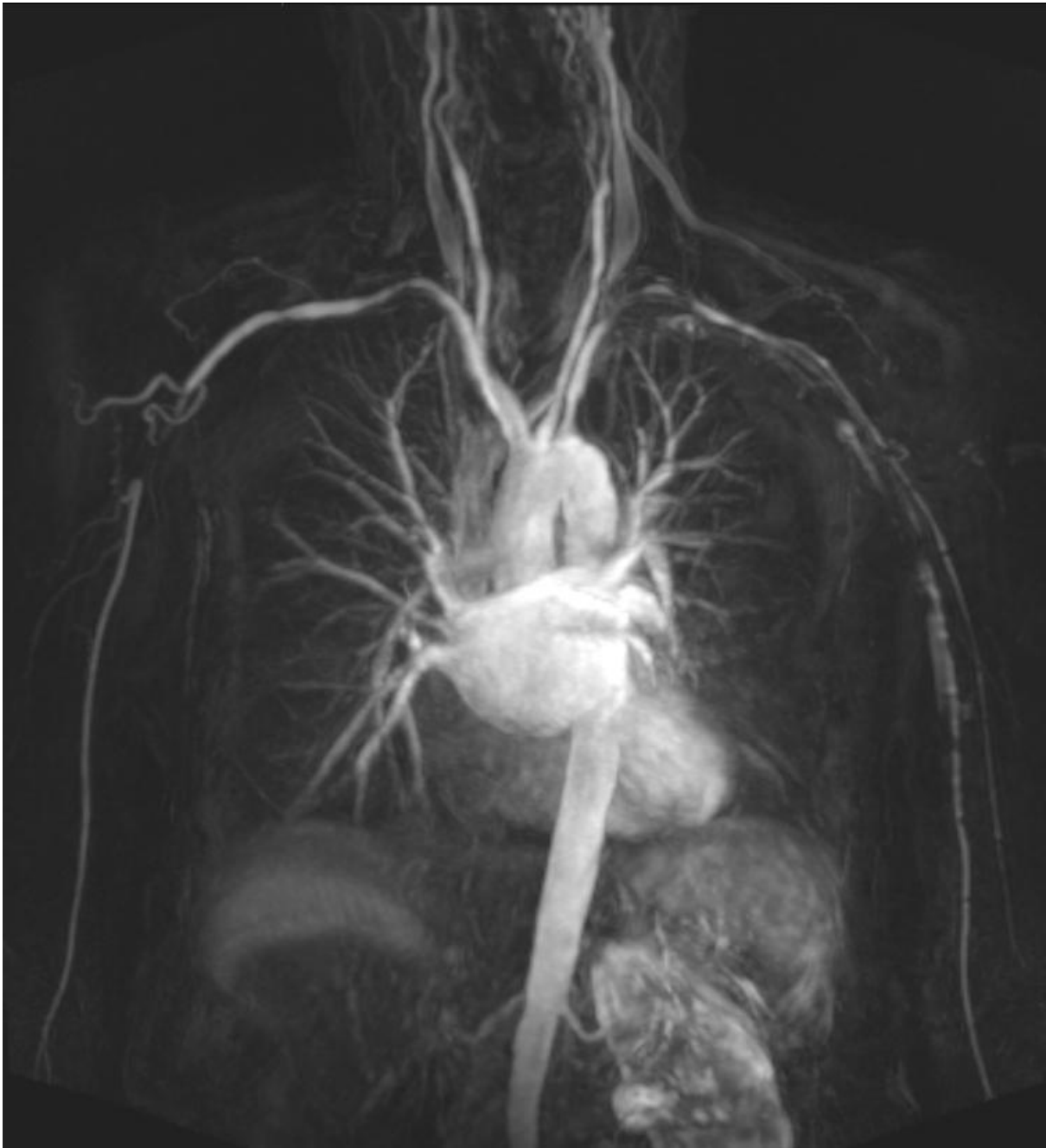- Trismus-like symptoms
- Fatigue of the muscles of mastication
- Rapid onset after the start of chewing and the ensuing severity of pain
- Patients seldom recognize the significance of symptoms of jaw claudication and must be questioned directly about this symptom
- Claudication-like symptoms occasionally occur with repeated swallowing and in the tongue during eating
- Jaw claudication is the symptom most highly associated with a positive temporal artery biopsy

Vision

- **Transient visual loss (amaurosis fugax)** — Transient monocular (and, rarely, binocular) impairment of vision can be an early manifestation of GCA.
- **Permanent vision loss** — The most feared complication of GCA. Commonly is painless and sudden, may be partial or complete, and may be unilateral or bilateral. Even in the era of effective therapy, permanent partial or complete loss of vision in one or both eyes is reported 20% of patients
- **Risk factors** — prior transient visual loss as the strongest predictor for subsequent permanent visual loss
- **Diplopia**

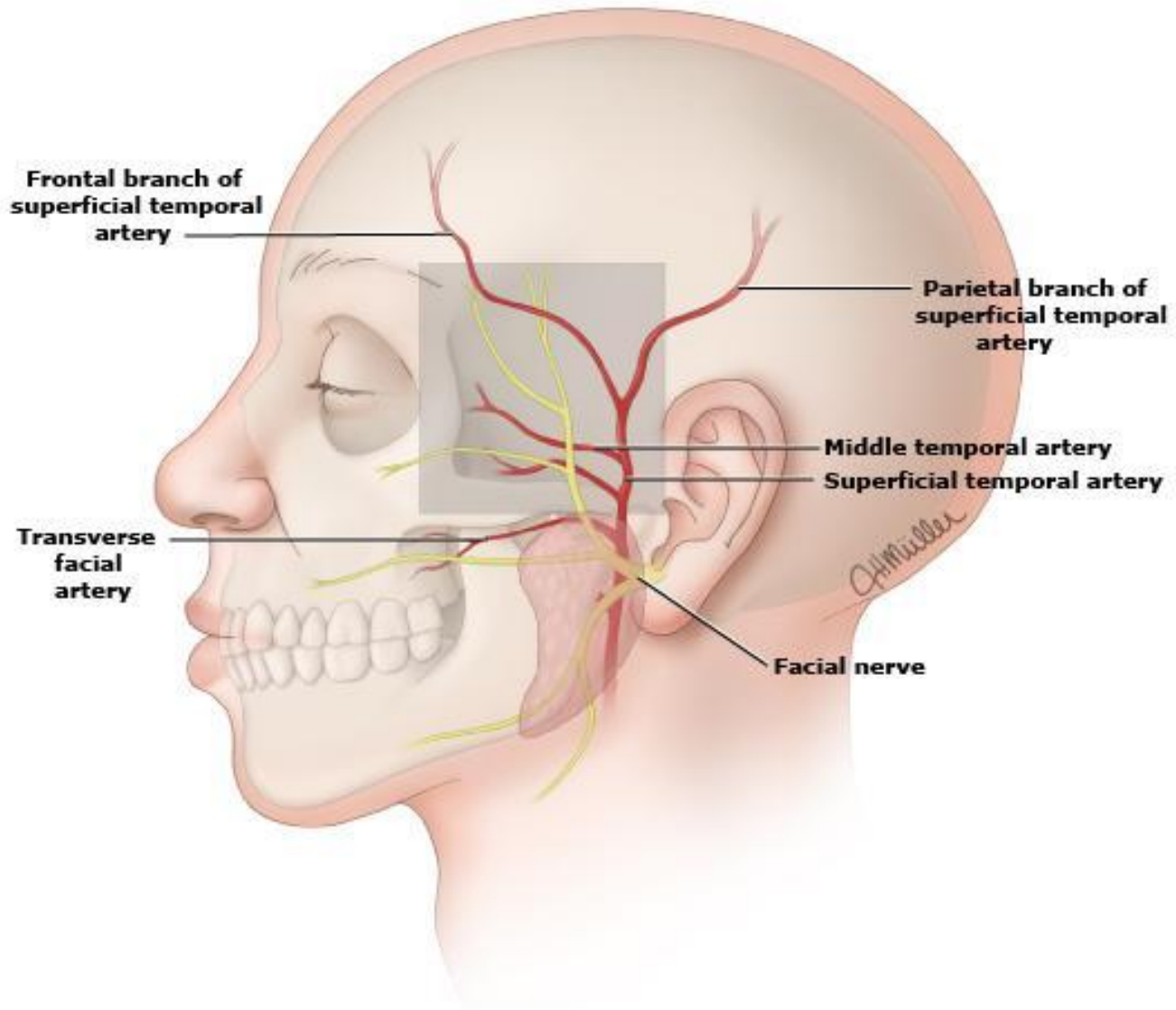
Large vessel GCA

- Involvement of the aorta and its major proximal branches - especially in the upper extremities
- The clinical consequences comprise aneurysms and dissections of the aorta, particularly the thoracic aorta, as well as stenosis, occlusion and ectasia of large arteries
- Axillary arteries, proximal brachial arteries - arterial bruits, diminished or absent blood pressures, and arm claudication may ensue. Cold intolerance is common, but explicit digital ulcerations and gangrene are rare because of the adequacy of collateral arterial supply
- Upper-extremity disease is bilateral, though not symmetric,



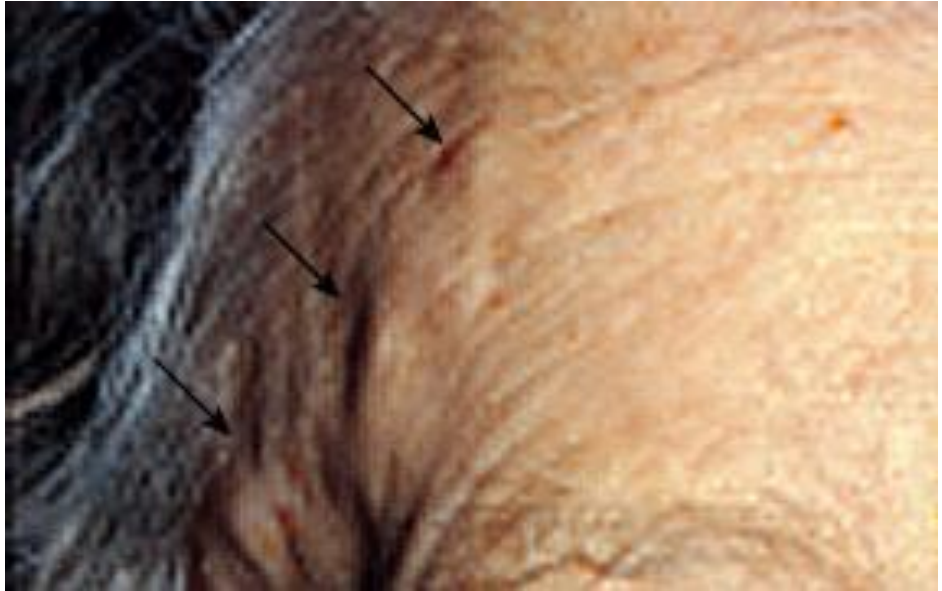
External carotid artery- branches

- Maxillary and dental pain
- Facial swelling
- Throat pain
- Tongue pain

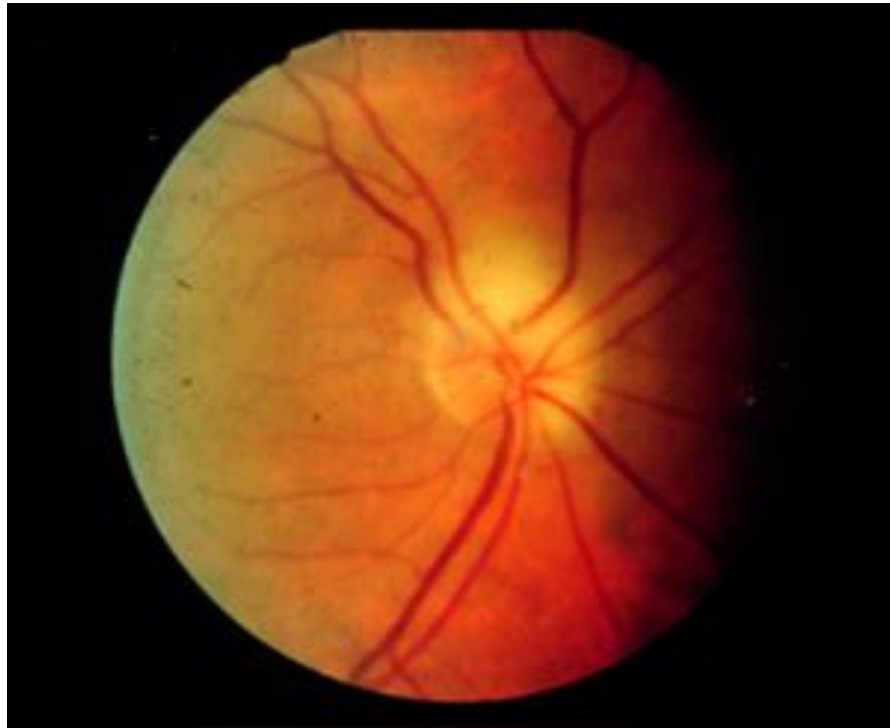

Physical examination

- Pulses – carotid, brachial, radial, femoral, pedal
- Blood pressure
- Bruits – carotid or supraclavicular areas; over the axillary, brachial, or femoral arteries; over the abdominal aorta
- Cardiac auscultation
- Temporal a. examination



AION



Laboratory findings

- **Normochromic anemia** is often present prior to therapy and improves promptly after the institution of glucocorticoids
- **Thrombocytosis**
- **The leukocyte count** is usually normal, even in the setting of widespread systemic inflammation.
- **Serum albumin** — moderately decreased at diagnosis but responds quickly to the institution of glucocorticoids
- **Hepatic enzymes** — Elevated serum concentrations of hepatic enzymes, especially the alkaline phosphatase, occur in 25 to 35 percent of patients
- **ESR and C-reactive protein** — elevated

Diagnosis

- The diagnosis of giant cell arteritis (GCA) should be considered in a patient over the age of 50 who complains of:
 - New headaches
 - Abrupt onset of visual disturbances
 - Symptoms of polymyalgia rheumatica
 - Jaw claudication
 - Unexplained fever or anemia
 - High ESR/CRP

Diagnosis

- Patient suspected of having GCA should undergo temporal artery biopsy
- ~85% sensitivity
- Other arteries can also be sampled
- Scheduling of the biopsy should NOT interfere with the start of glucocorticoid therapy when there is a significant concern about the possibility of GCA

Biopsy-negative GCA

- The patient may not have GCA. If the clinical story is equivocal, then alternative diagnoses should be given more weight
- The patient may have GCA involving only the great vessels. Among patients with suggestive symptoms (most often arm claudication), an imaging study should be performed
- An empiric trial of glucocorticoid therapy may be helpful. Failure of the patient's symptoms to resolve within one week of high-dose glucocorticoids argues strongly against the diagnosis of GCA

Imaging

- MRI/MRA
- USD
- Angiography
- PET-CT

Treatment

- Uncomplicated GCA - 40 to 60 mg of prednisone in a single dose
- After achieving a daily dose of 10 mg, the prednisone taper should be slow, such that patients remain on some prednisone for 9 to 12 months. Tapering in 1 mg decrements per month once the daily dose is less than 10 mg is appropriate

Treatment

- Add aspirin (80 to 100 mg/day) to reduce the risk of visual loss, transient ischemic attacks, or stroke
- PPI to prevent GI damage
- If there is a strong suspicion of GCA as the cause of visual loss - intravenous pulse methylprednisolone – 1gr for 3 days.
- This is then followed by oral therapy with 1 mg/kg per day (maximum of 60 mg/day), as recommended above for uncomplicated GCA. For patients without contraindications to anticoagulation, warfarin therapy in addition to low-dose aspirin may also be considered in this setting.
- Annual chest radiographs for up to 10 years to identify asymptomatic thoracic aortic
- Self-limited course over several months to several years. The glucocorticoid dose can eventually be reduced and discontinued in the majority of patients. GCA may not adversely affect overall survival
- Permanent partial or complete loss of vision in one or both eyes has been observed in 15 to 20 percent of patients