

Hysterosalpingography

Written by : IRENE NASIKIWA KIVARIA

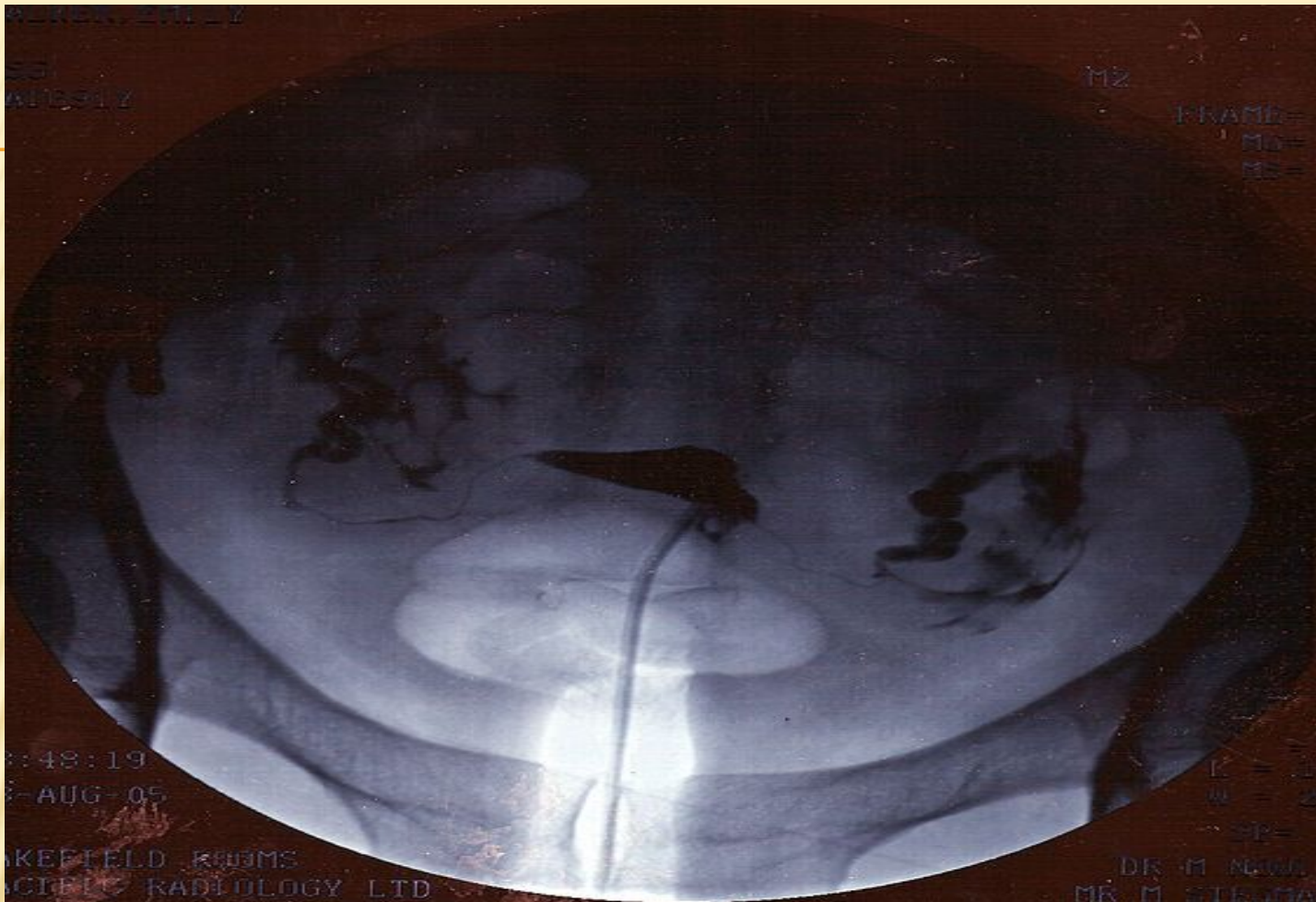Course: 5th year

Faculty: General Medicine

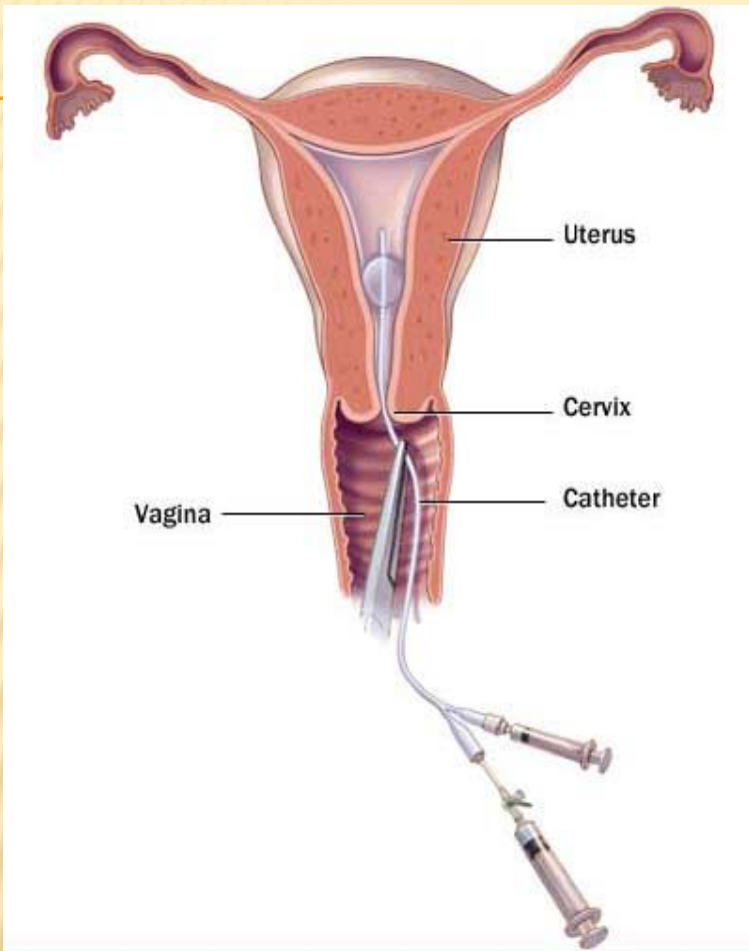
? **Hysterosalpingography (HSG)** is a radiologic procedure to investigate the shape of the uterine cavity and the shape and patency of the fallopian tubes. It entails the injection of a radio-opaque material into the cervical canal and usually fluoroscopy with image intensification. A normal result shows the filling of the uterine cavity and the bilateral filling of the fallopian tube with the injection material. To demonstrate tubal rupture, spillage of the material into the peritoneal cavity needs to be observed. A synonym to hysterosalpingography is uterosalpingography

PROCEDURE

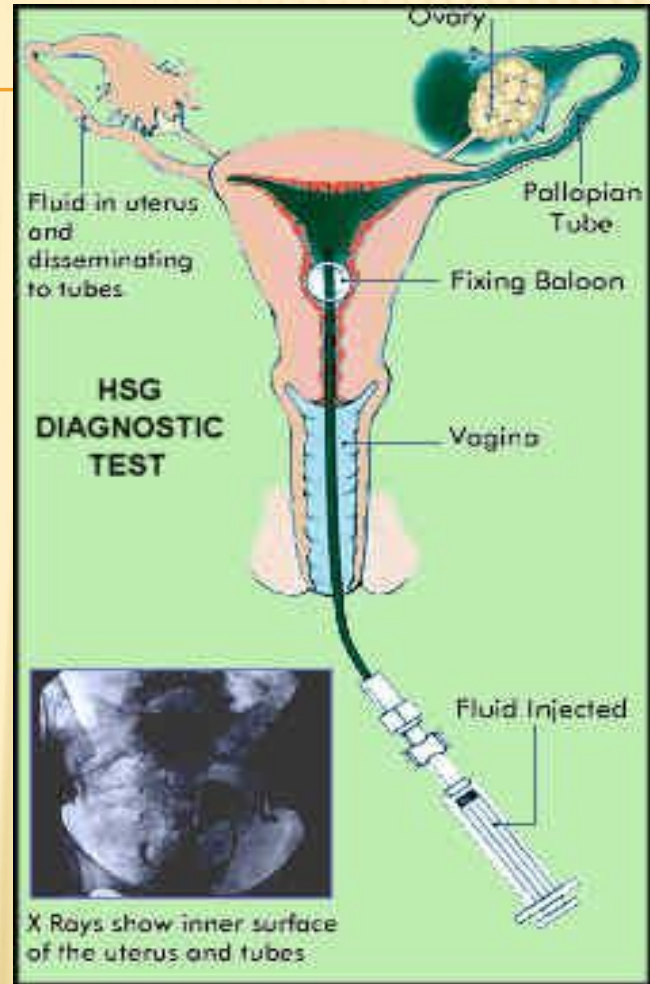
- ? The procedure involves X-rays. It should be done in the follicular phase of the cycle. It is useful to diagnose uterine malformations, Asherman's syndrome, tubal occlusion and used extensively in the work-up of infertile women.
- ? The test is usually done with radiographic contrast medium (dye) injected into the uterine cavity through the vagina and cervix. If the fallopian tubes are open the contrast medium will fill the tubes and spill out into the abdominal cavity. It can be determined whether the fallopian tubes are open or blocked and whether the blockage is located at the junction of the tube and the uterus (proximal) or whether it is at the end of the fallopian tube (distal).
- ? The HSG can be painful, so analgesics may be administered before and/or after the procedure to reduce pain. Many doctors will also prescribe an antibiotic prior to the procedure to reduce the risk of an infection.



- ? A hysterosalpingogram. Note the catheter entering at the bottom of the screen, and the dark contrast material filling the uterine cavity (small triangle in the center) and outlining the Fallopian tubes (winding structures on left and right).



© Mayo Foundation for Medical Education and Research. All rights reserved.

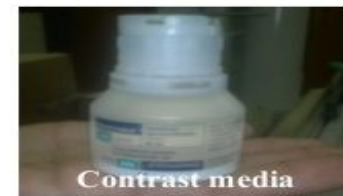

HOW IS HSG DONE?

HSG is done in a hospital, clinic, or health care provider's office. It is best to have HSG done in the first half (days 1–14) of the menstrual cycle. This timing reduces the chance that you may be pregnant.

During HSG, a contrast medium is placed in the uterus and fallopian tubes. This is a fluid that contains a dye. The dye shows up in contrast to the body structures on an X-ray screen. The dye outlines the inner size and shape of the uterus and fallopian tubes. It also is possible to see how the dye moves through the body structures.

Instruments of Hysterosalpingography:



☐ **Timing : should be performed within 10th-14th day of cycle .**

The procedure is performed as follows:

- ? 1. You will be asked to lie on your back with your feet placed as for a pelvic exam. A device called a speculum is inserted into the vagina. It holds the walls of the vagina apart to allow the cervix to be viewed. The cervix is cleaned.
- ? 2. The end of the cervix may be injected with local anesthesia (pain relief). You may feel a slight pinch or tug as this is done.
- ? 3. One of two methods may be used to insert the dye. In one method, the cervix is grasped with a device to hold it steady.
- ? An instrument called a cannula is then inserted into the cervix. In the other method, a thin plastic tube is passed into the cervical opening. The tube has a small balloon at the end that is inflated. The balloon keeps the tube in place in the uterus.
- ? 4. The speculum is removed, and you are placed beneath an X-ray machine.
- ? 5. The fluid slowly is placed through the cannula or tube into the uterus and fallopian tubes. The fluid may cause cramping.
- ? If the tubes are blocked, the fluid will cause them to stretch.
- ? 6. X-ray images are made as the contrast medium fills the uterus and tubes. You may be asked to change position. If there
- ? is no blockage, the fluid will spill slowly out the far ends of the tubes. After it spills out, the fluid is absorbed by the body.
- ? 7. After the images are made, the cannula or tube is removed.

What are the risks associated with HSG?

Severe problems after an HSG are rare. They include an allergic reaction to the dye, injury to the uterus, or pelvic infection.

Call your health care provider if you have any of these symptoms:

- ? • Foul-smelling vaginal discharge
- ? • Vomiting
- ? • Fainting
- ? • Severe abdominal pain or cramping
- ? • Heavy vaginal bleeding
- ? • Fever or chills

Are there alternatives to HSG?

There are other procedures that can give your health care provider some of the same information as HSG:

- ? • Laparoscopy —This surgical procedure requires general anesthesia (see the FAQ Laparoscopy).
- ? • Hysteroscopy —This procedure can give a detailed view of the inside of the uterus. However, it cannot show whether
- ? the fallopian tubes are blocked (see the FAQ Hysteroscopy).
- ? • Sonohysterography —This technique uses ultrasound to show the inside of the uterus. Like hysteroscopy, it does not
- ? give information about the fallopian tubes (see the FAQ Sonohysterography).

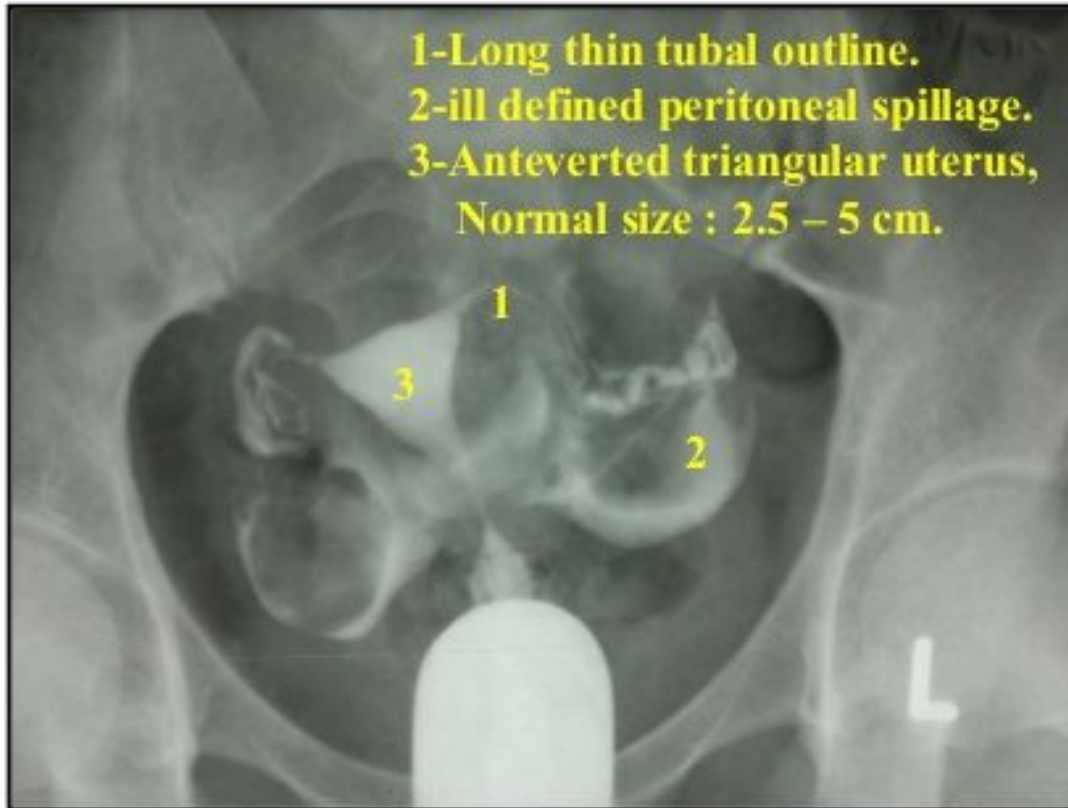Indications of Hysterosalpingography:

- Infertility (tubal patency , Asherman's syndrome).**
- congenital uterine anomalies.**
- Recurrent miscarriage.**
- Abnormal uterine bleeding.**
- Diagnosis of uterine mass (fibroids).**
- Evaluation following pelvic trauma.**

Contraindications of Hysterosalpingography:

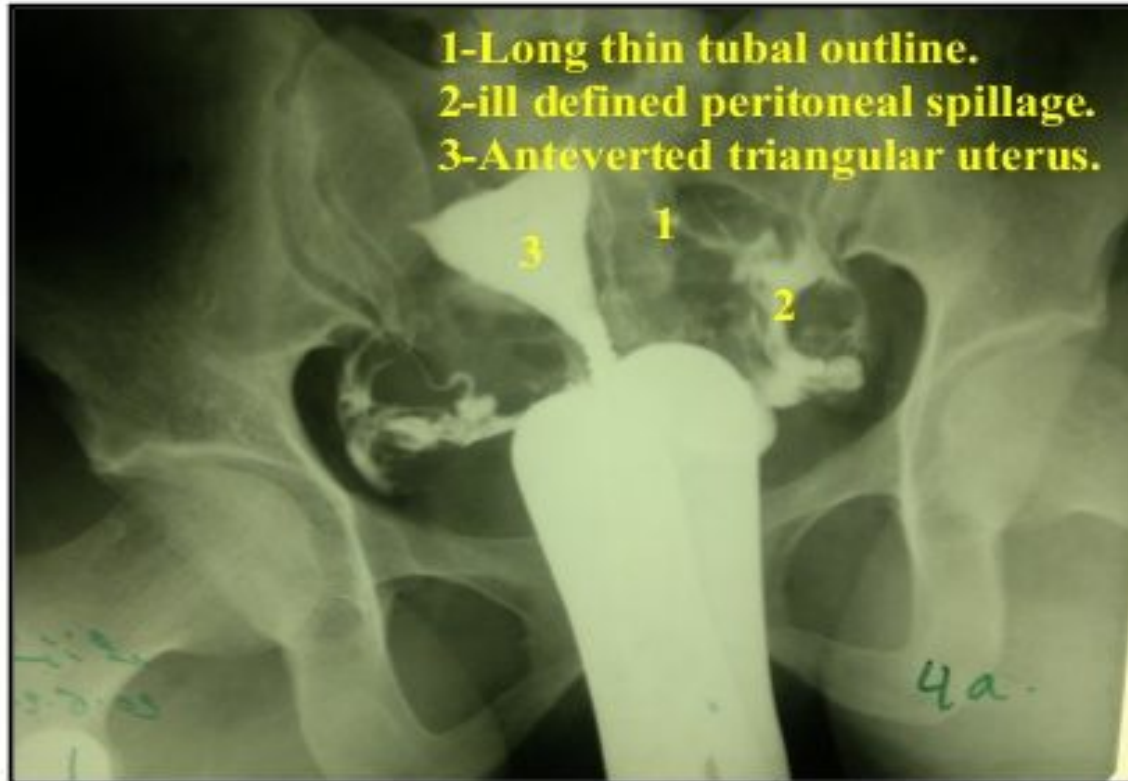
- Pregnancy.**
- Bleeding.**
- Immediate premenstrual or postmenstrual phase.**
- Recent untreated pelvic infection.**
- Tubal or uterine surgery within last 6 weeks.**
- Contrast medium sensitivity.**

Case 1



- Diagnosis:** normal film.
- Description:** small uterus (nulliparous)

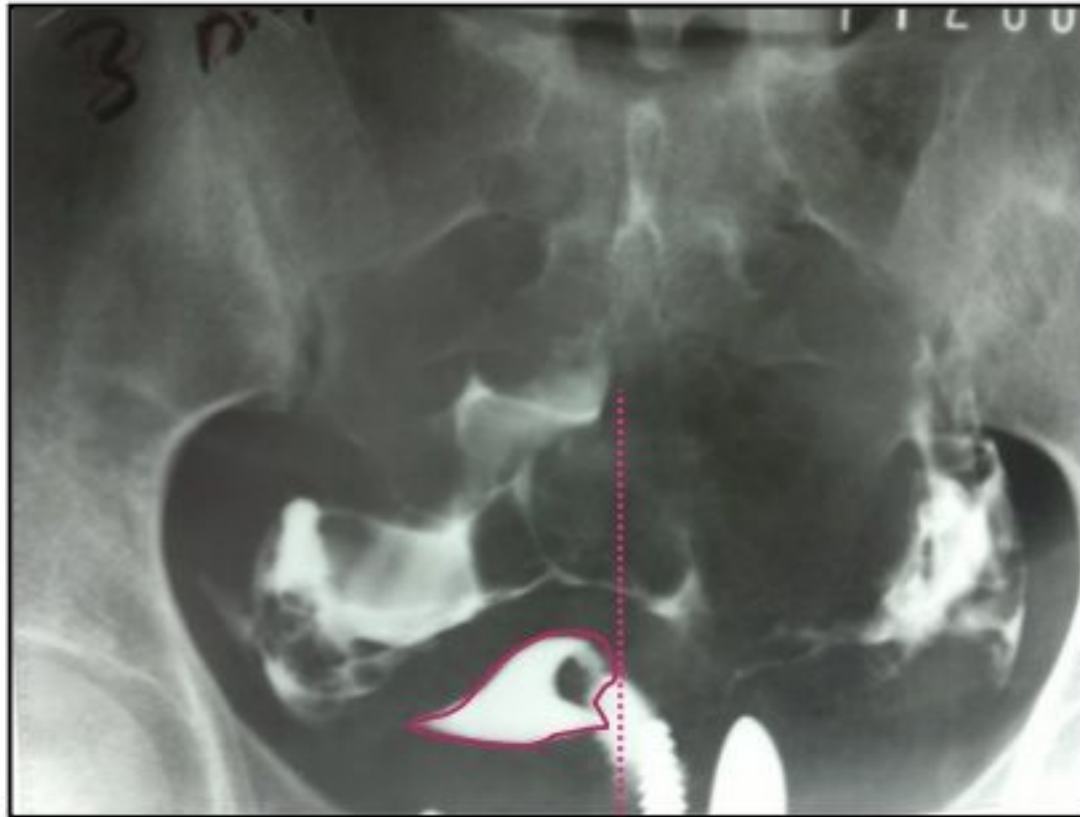
Case 2



Diagnosis: normal film.

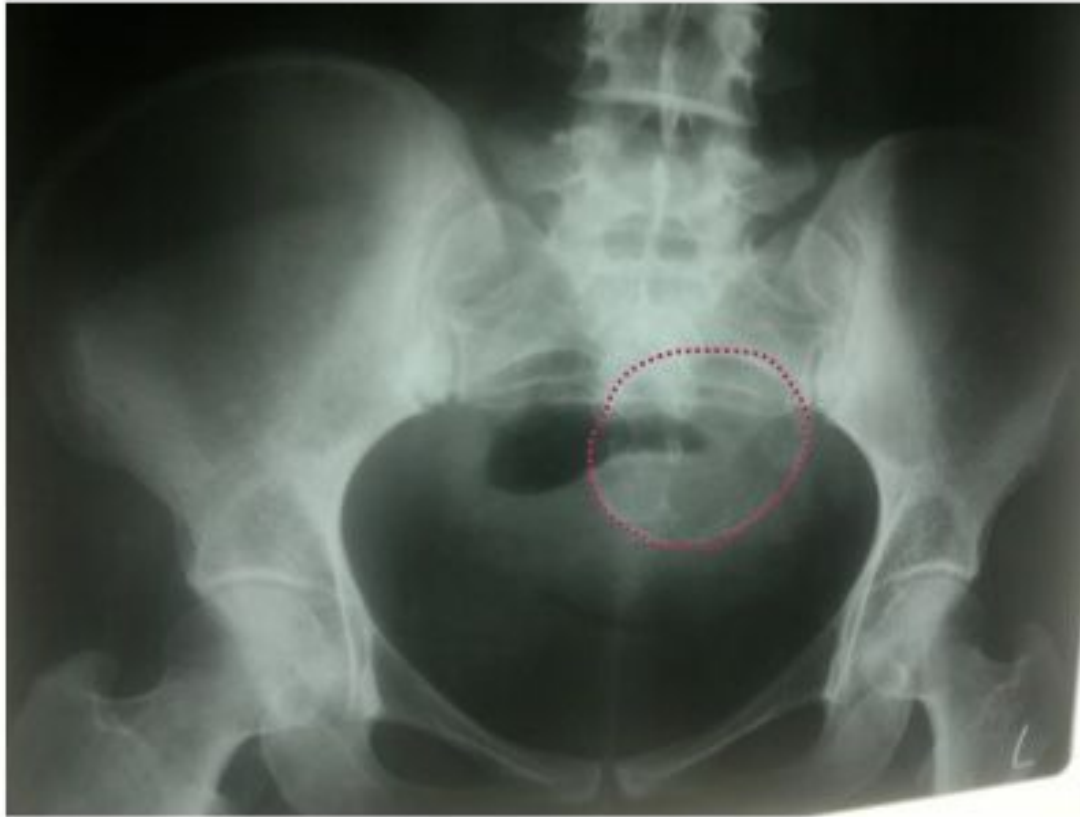Description: large uterus (multiparous)

Case 6



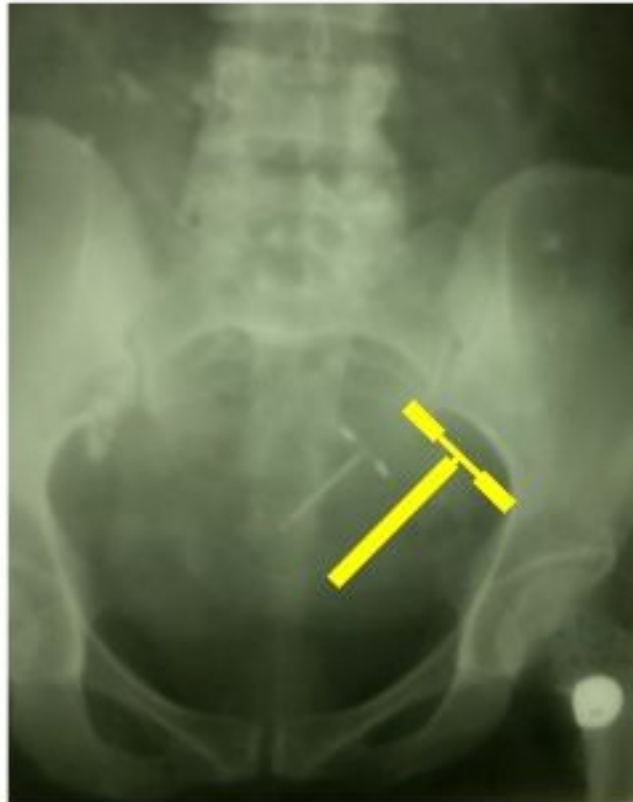- ❑ **Diagnosis:** retroverted uterus.
- ❑ **Description:** deviation from medline.

Case 44



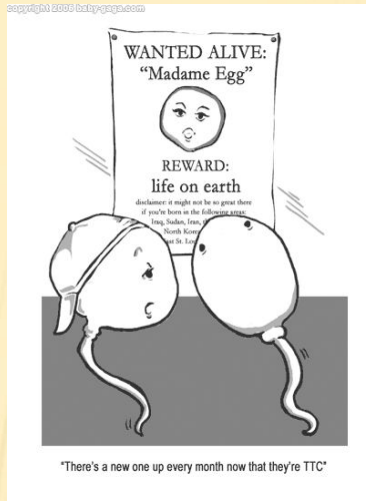
- ❑ **Diagnosis:** uterine fibroid.
- ❑ **Description:** calcification inside uterus.

Case 41



Diagnosis: IUCD.

Description: copper IUCD inside uterus.



THE END