

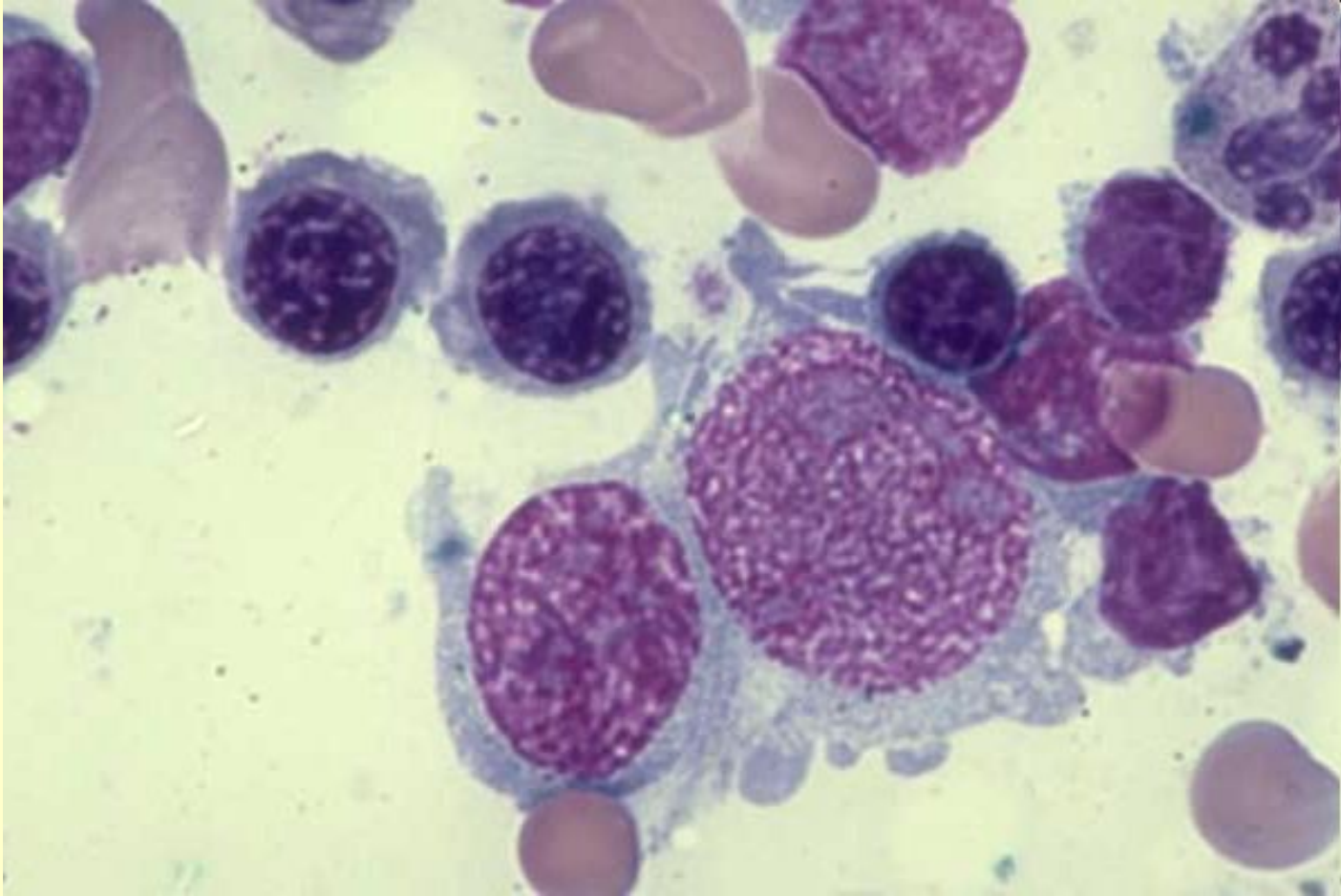
*Клеточное строение
костного мозга*

Все клетки, которые можно встретить в костном мозге в норме и при патологии можно разделить на следующие основные группы:

1. Клетки ретикулярной стромы (не принимают непосредственного участия в кроветворении, но имеют большое значение, т. к. создают необходимое микроокружение для кроветворных клеток). К ним относятся:
 - ретикулярные клетки;
 - клетки эндотелия;
 - остеобласты;
 - жировые клетки.

Ретикулярные клетки

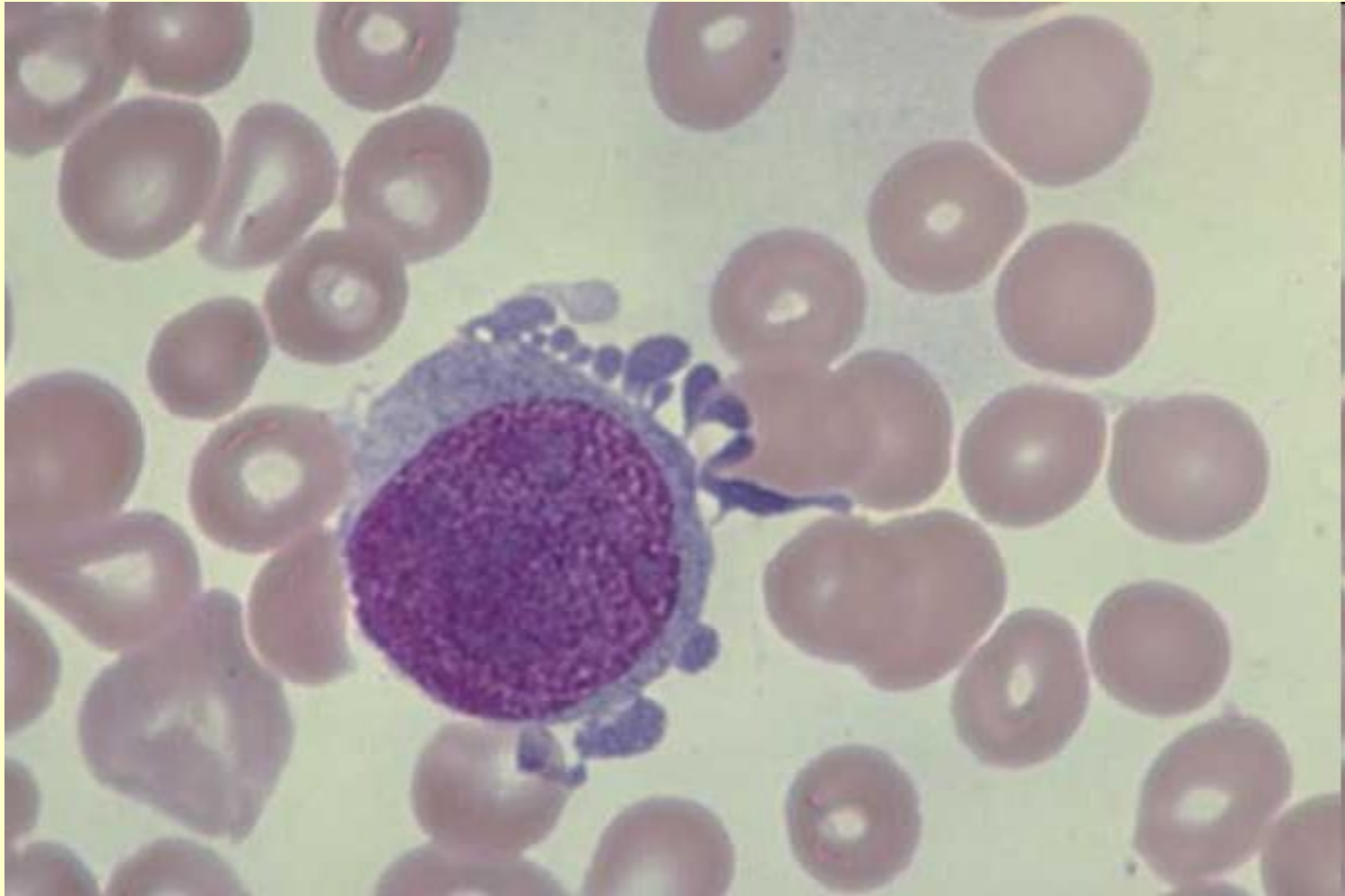
Reticular cells, polychromatic NRBCs, normal marrow



Two reticular cells (center), 4 lymphocytes, 5 polychromatic NRBCs, 1 segmented neutrophil, 1 smudge cell. Normal marrow - 100X

Ретикулярные клетки

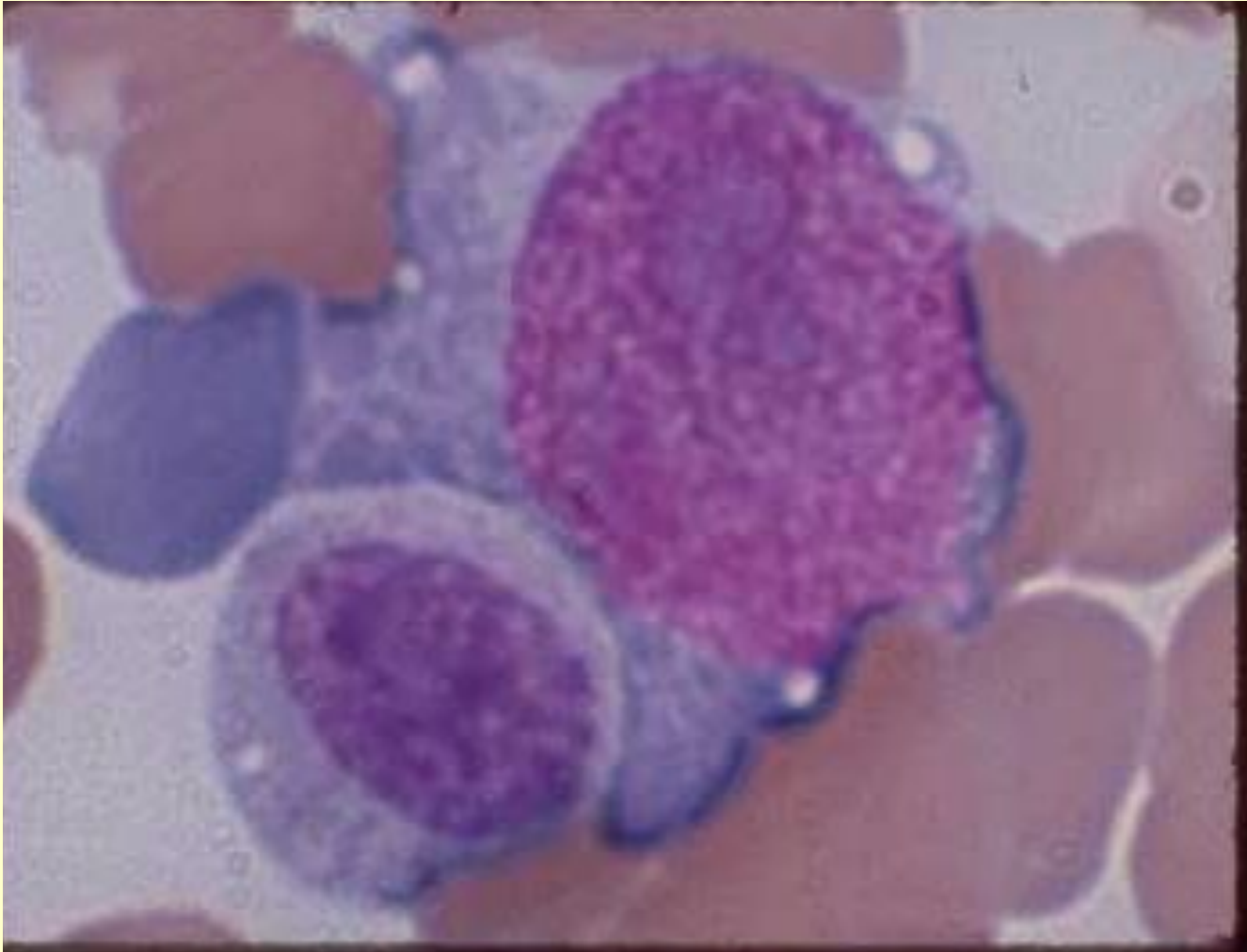
Reticular cell, normal marrow



One reticular cell. Normal marrow - 100X

Ретикулярные клетки

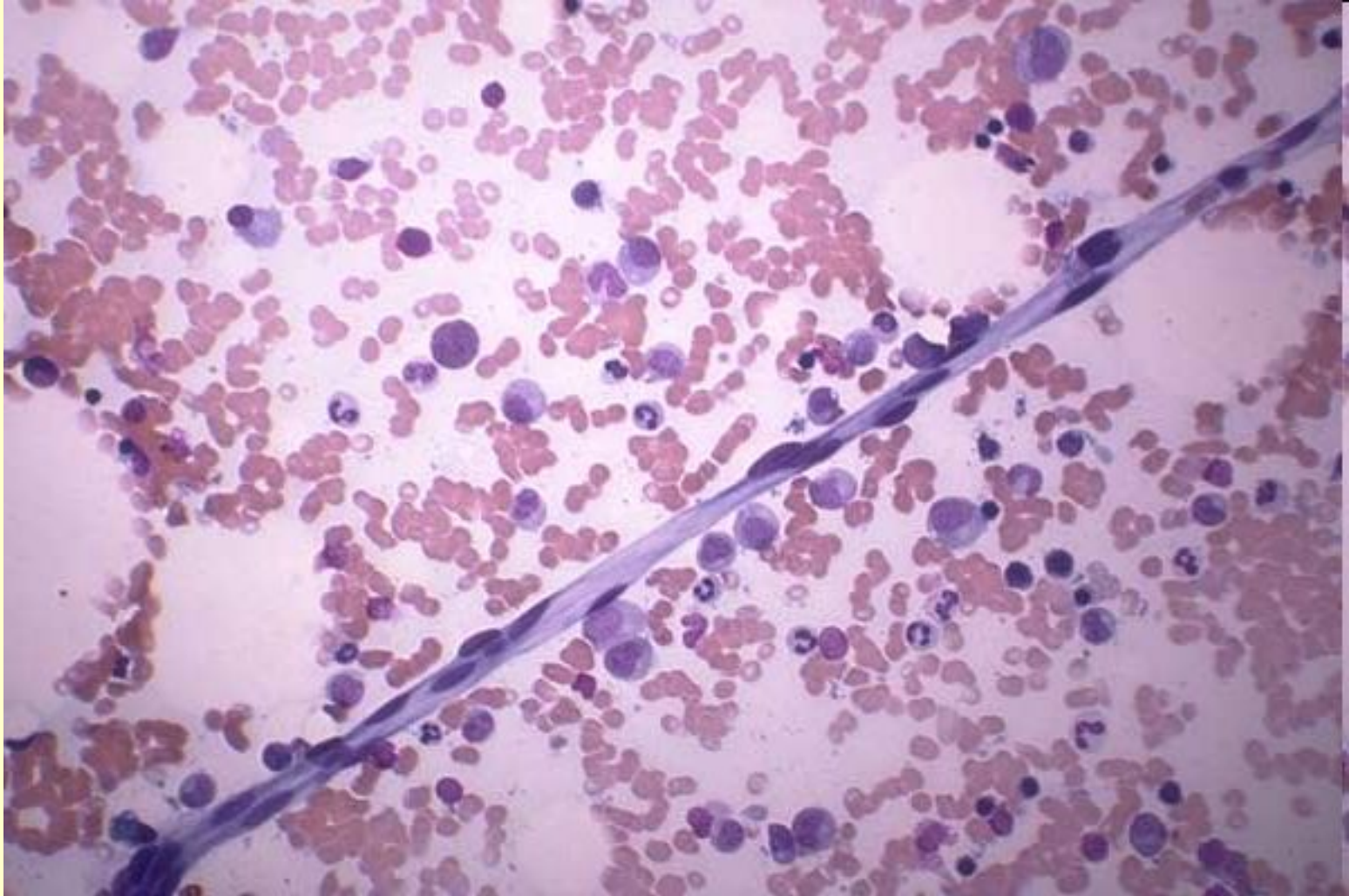
Reticular cell, neutrophilic myelocyte, normal marrow



One reticular cell, 1 neutrophilic myelocyte. Normal marrow - 100X

Клетки эндотелия

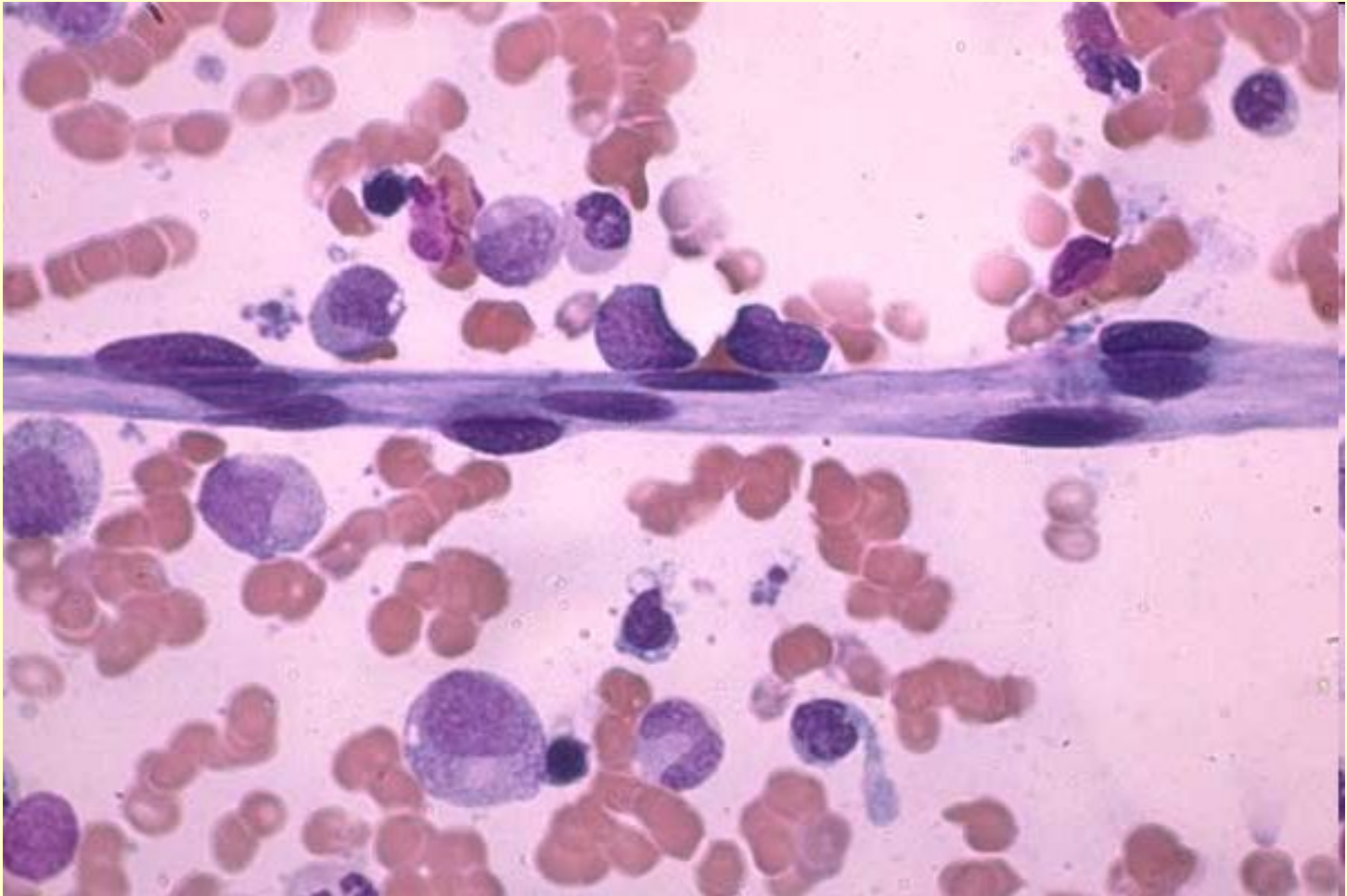
Endothelial cells.



Strand of endothelial cells. Normal marrow -20X

Клетки эндотелия

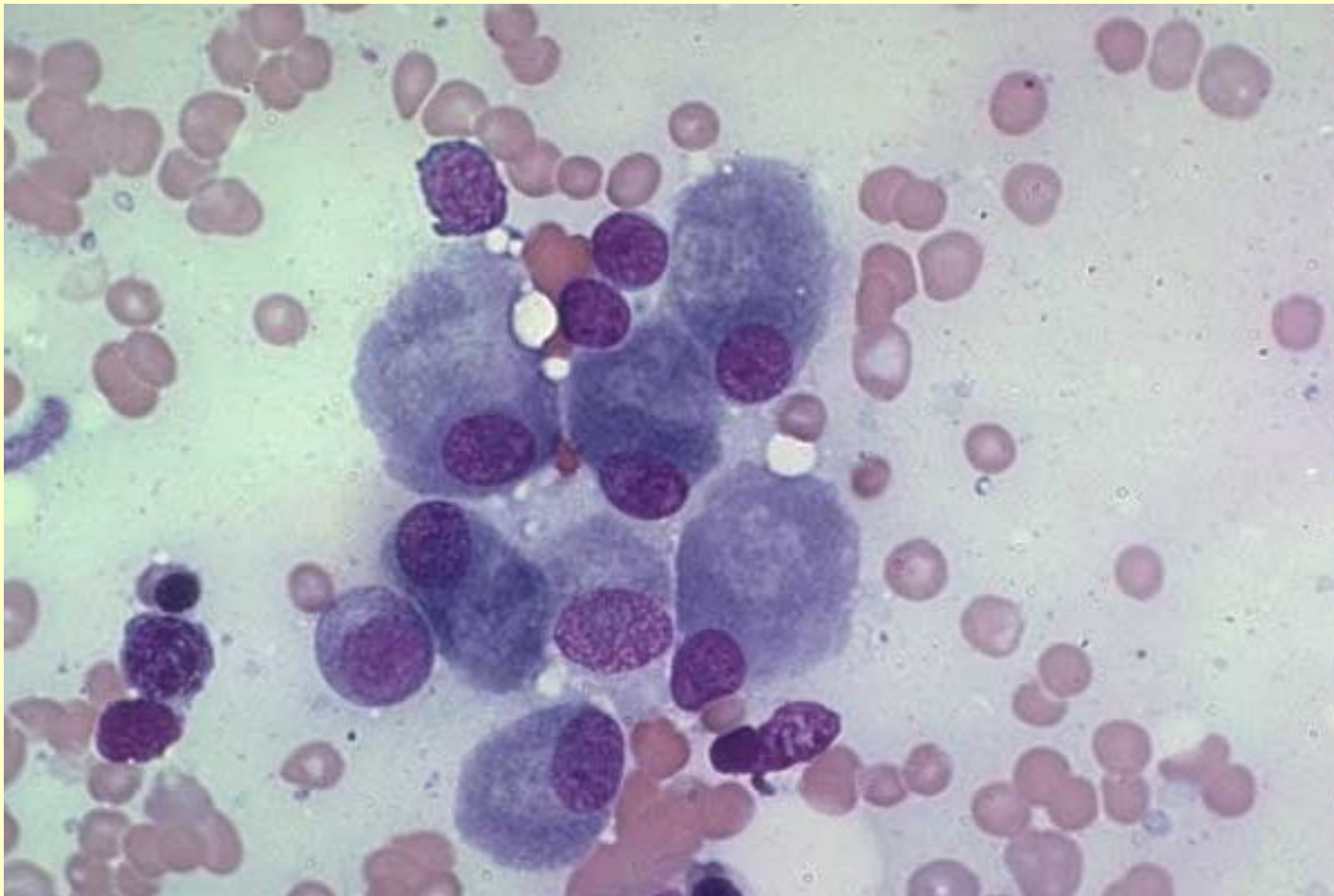
Endothelial cells



Higher magnification of strand of endothelial cells. Normal marrow - 100X

Остеобласты

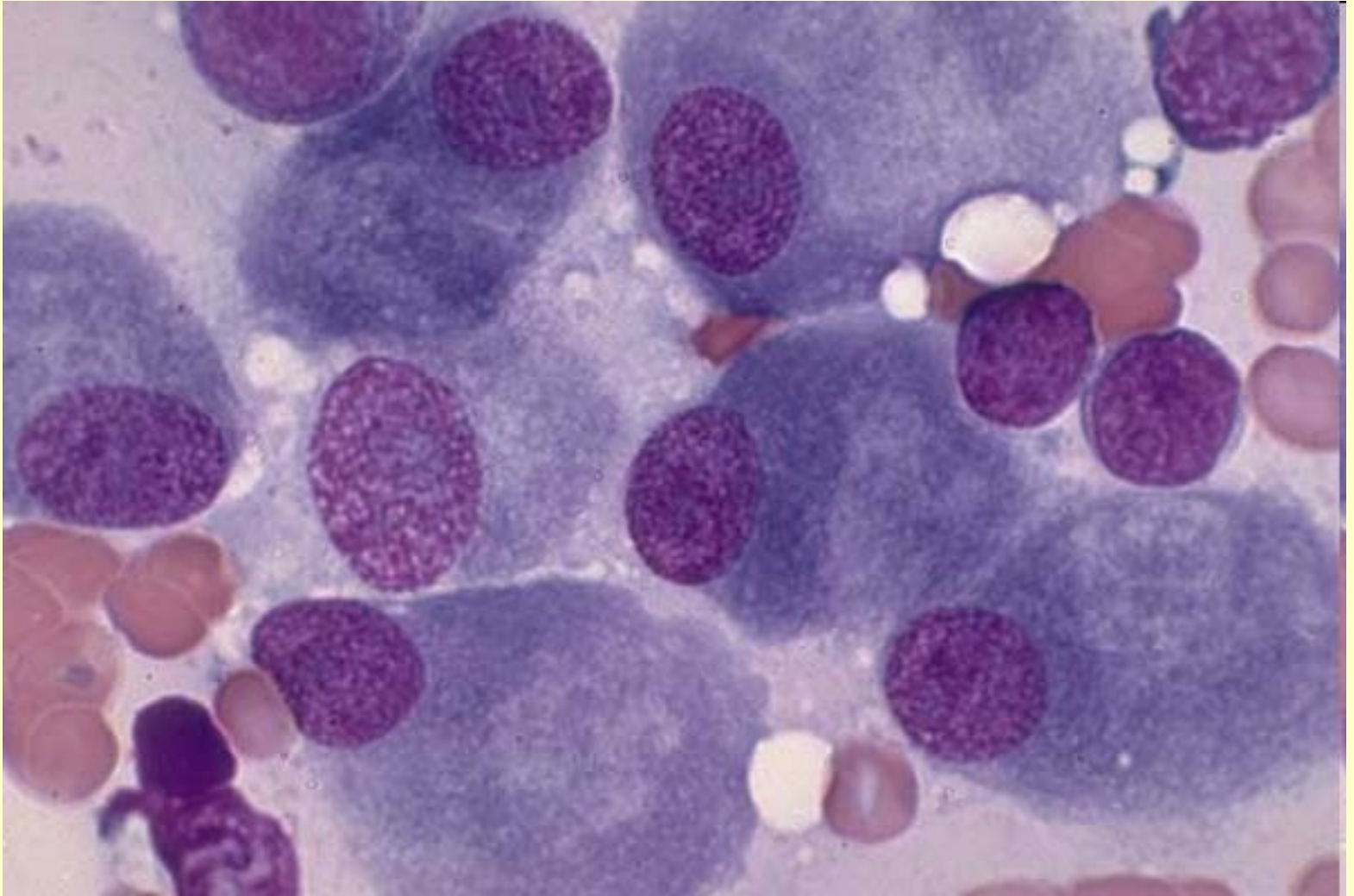
Osteoblasts



Clump of osteoblasts. Normal marrow particle preparation -50X Osteoblast are large in size, often are oval in shape, have an eccentrically located nucleus which appears to be falling out of the cell, blue-gray cytoplasm with a clear area away from the nucleus.

Остеобласты

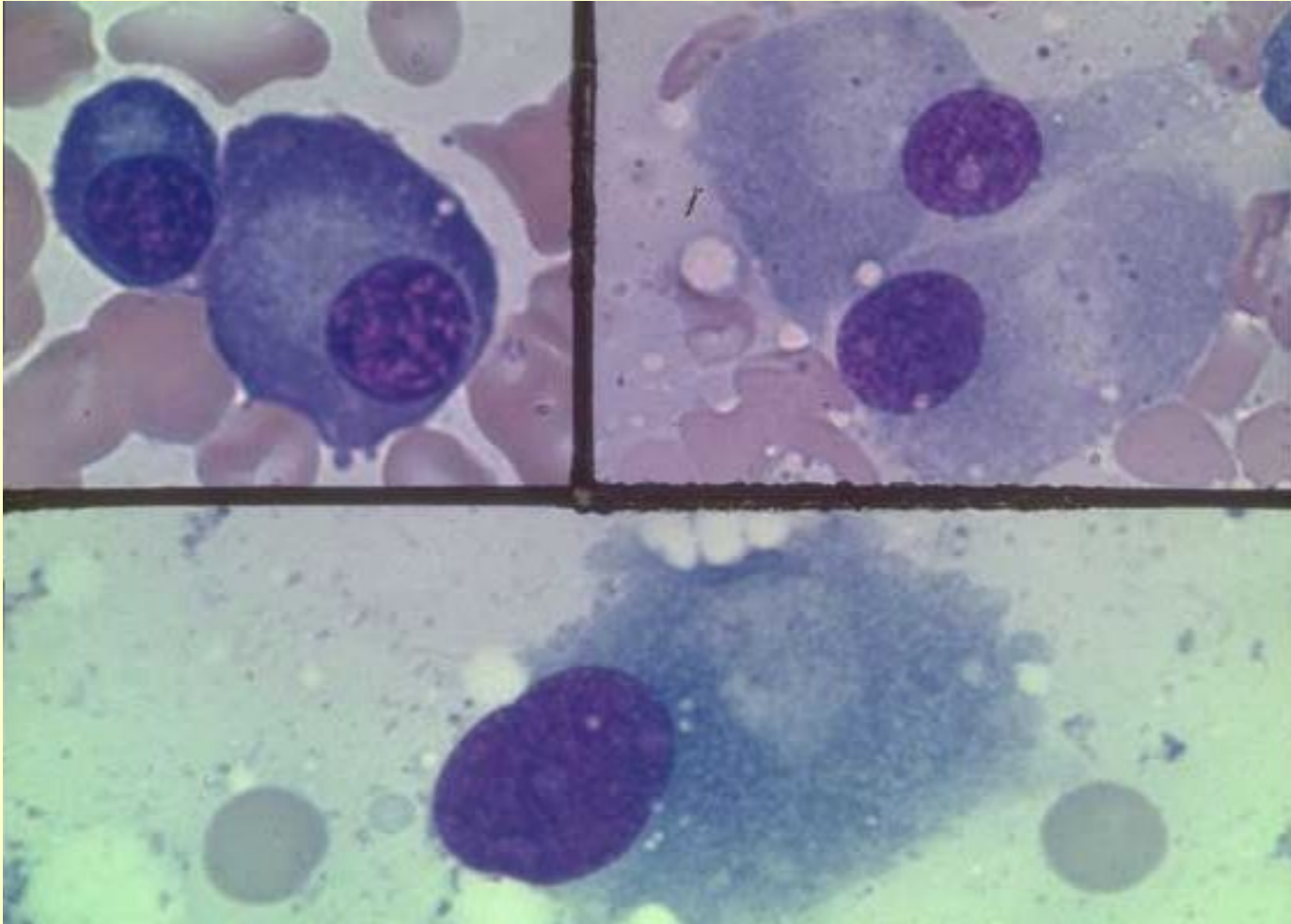
Osteoblasts, Normal marrow



Same clump of osteoblasts. Normal marrow particle preparation -100X

Остеобласты

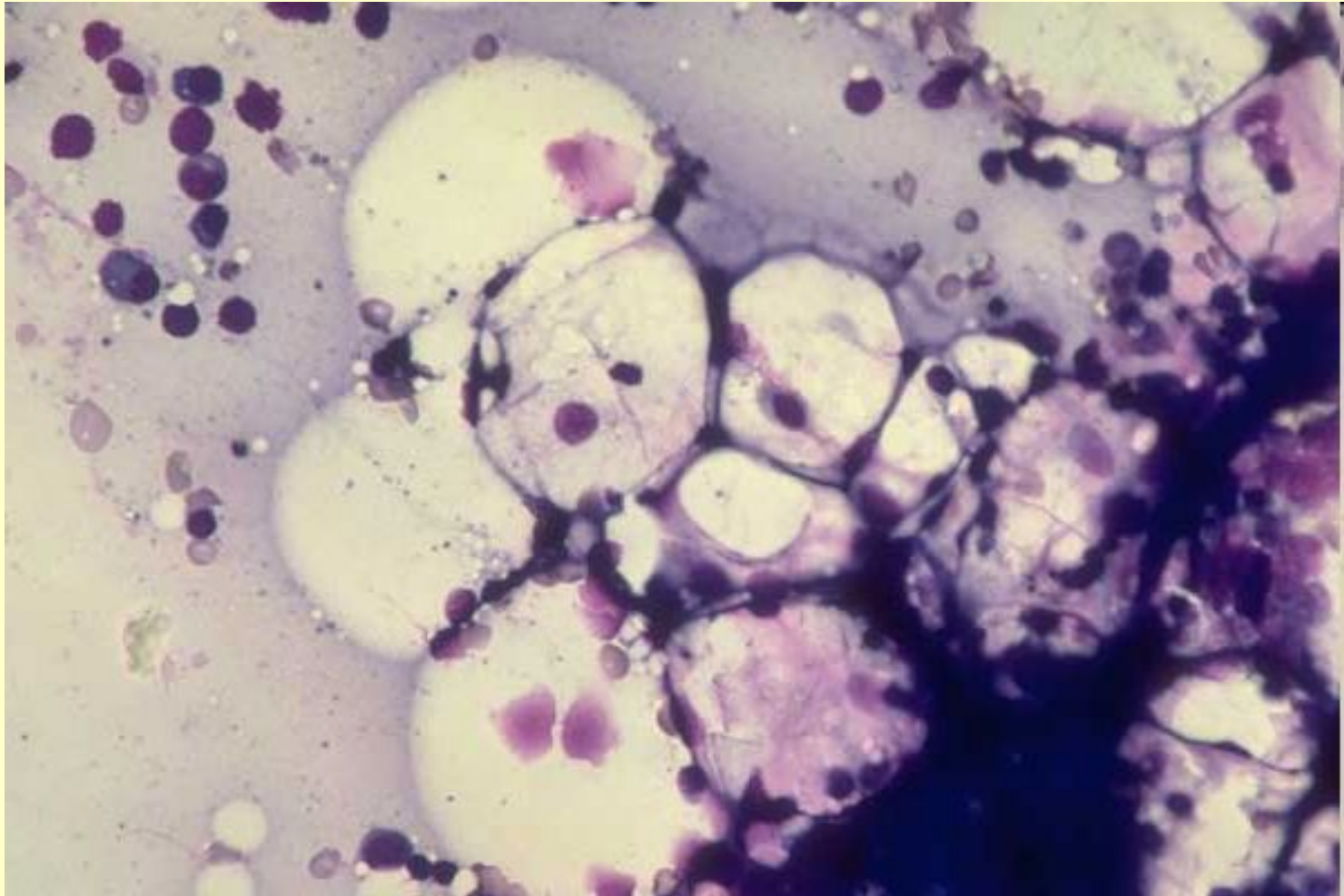
Plasma cell, osteoblasts



One small and 1 large plasma cell in top left frame. 2 osteoblasts in top right frame, 1 osteoblast in lower frame. Normal marrow -100X

Жировые клетки

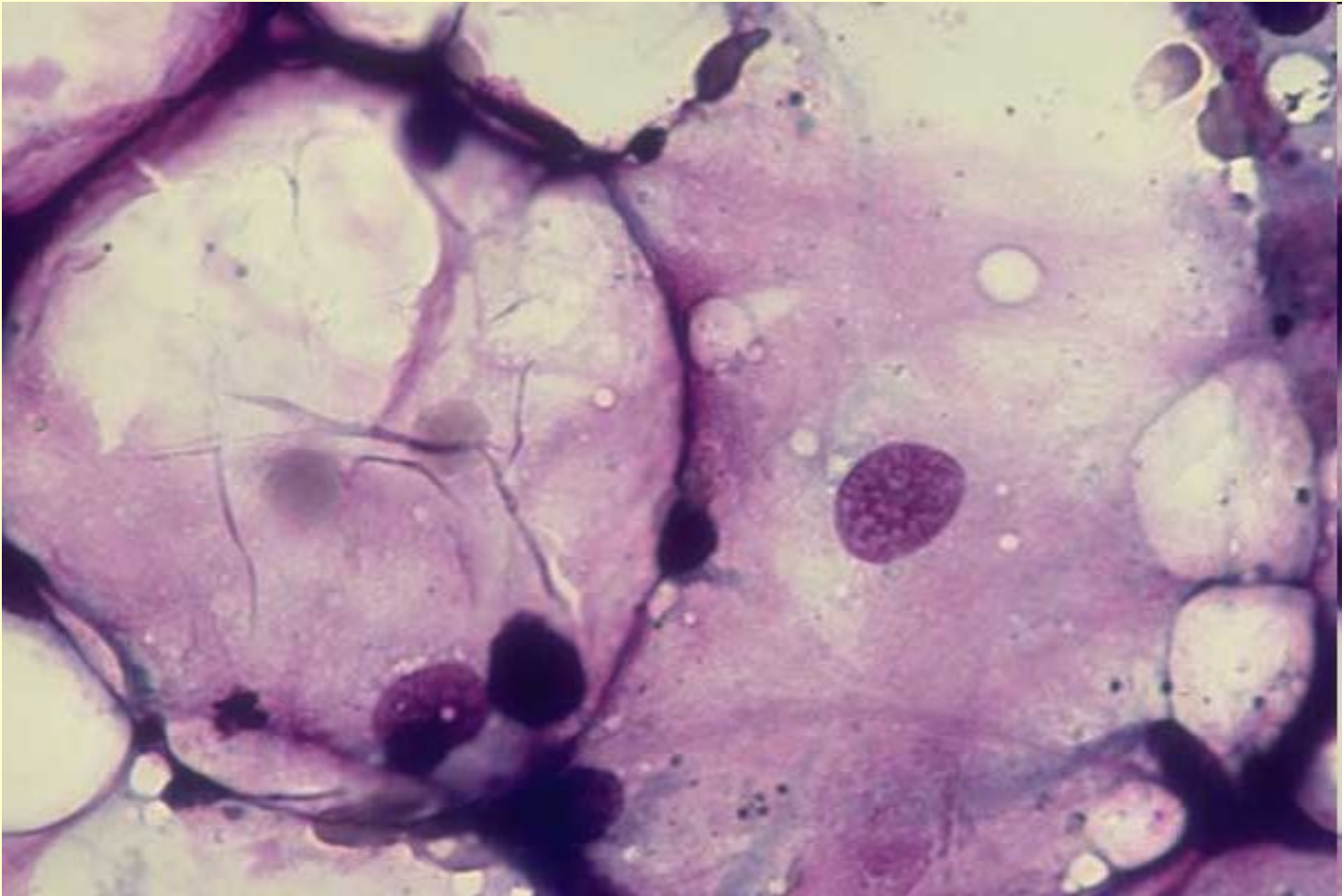
Fat cells. Aplastic anemia marrow



Multiple fat cells. Aplastic anemia marrow -20X

Жировые клетки

Fat cells, Aplastic anemia marrow

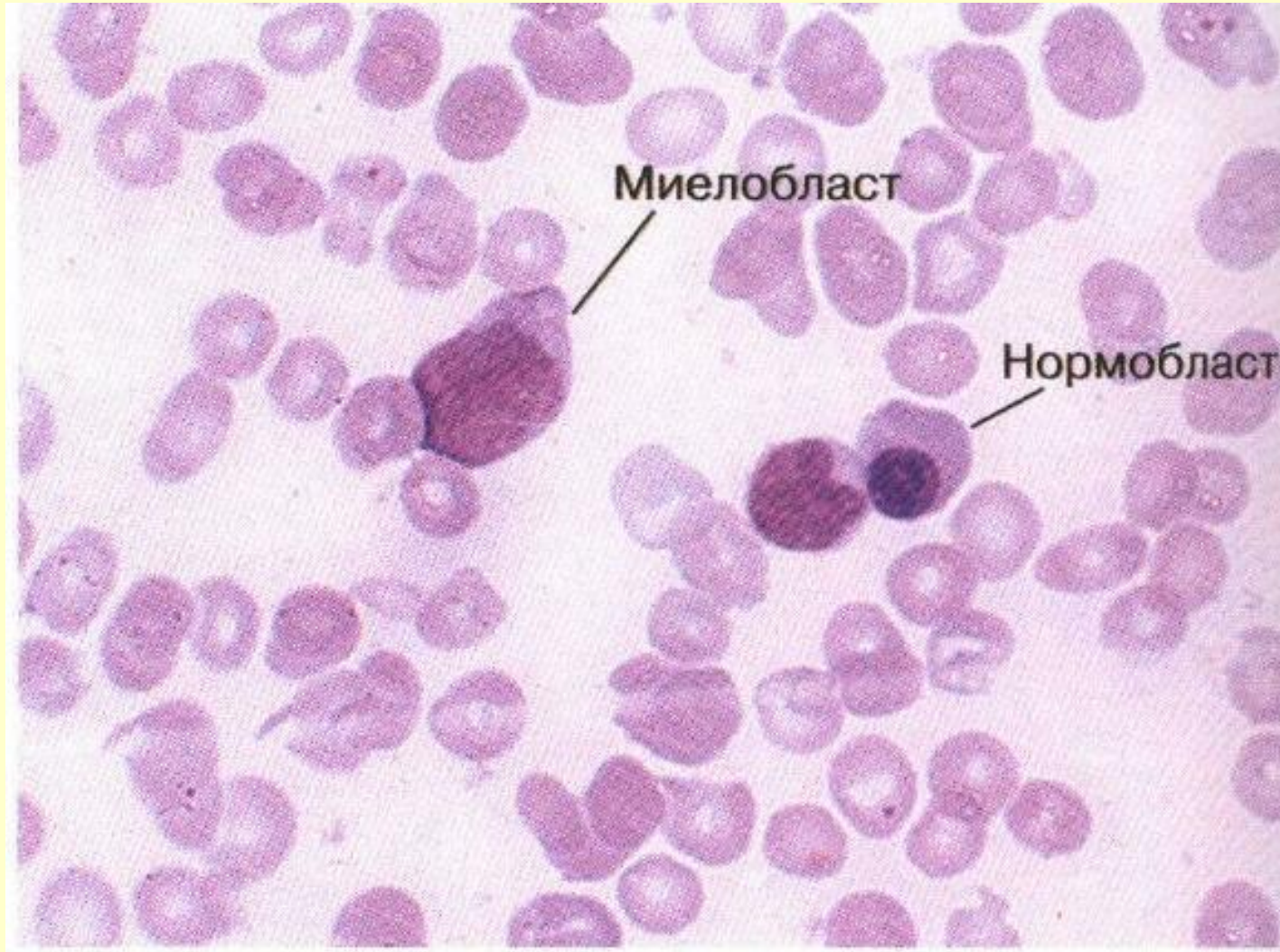


Two very large fat cells. Aplastic anemia marrow -50X

2. Миелокариоциты - клетки кроветворной ткани костного мозга с их производными - зрелыми клетками крови. К ним относятся:

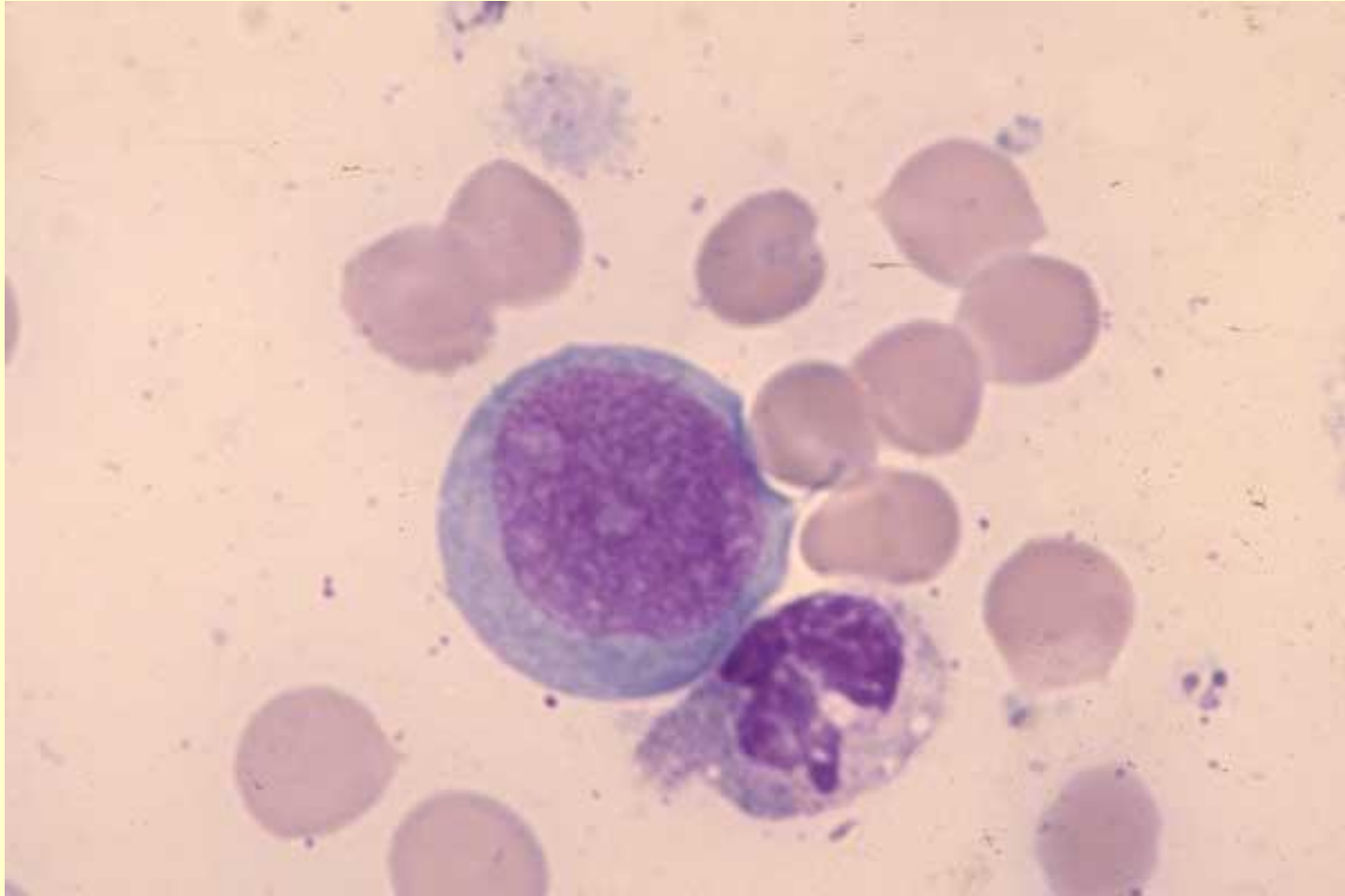
- недифференцированные бласты;
- клетки миелоцитарного ряда;
- клетки моноцитарного ряда;
- клетки лимфоцитарного ряда;
- клетки эритроцитарного ряда;
- клетки мегакариоцитарного ряда.

Недифференцированные бласты



Миелобласт

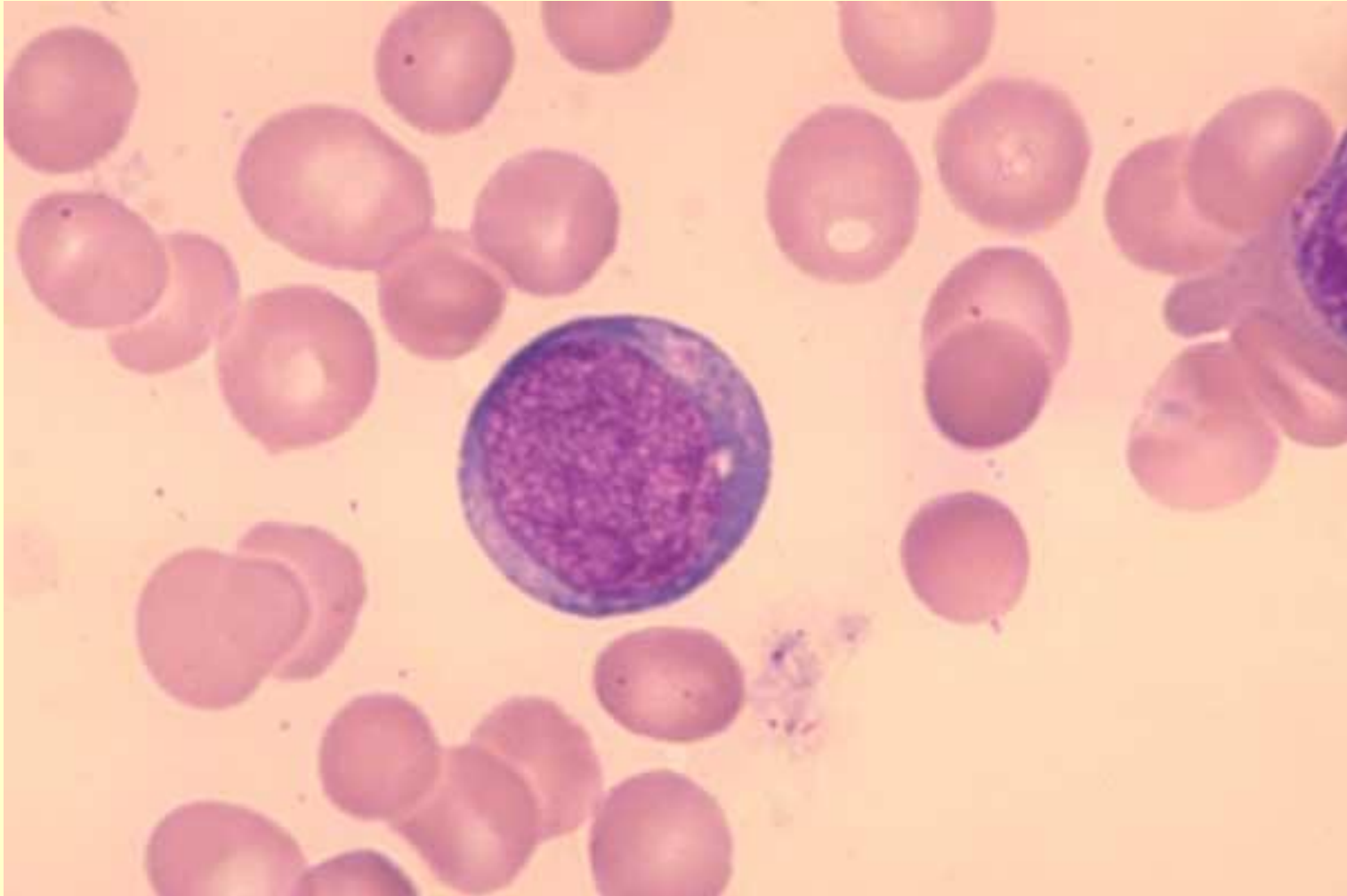
Myeloblast, late neutrophil, normal marrow



One myeloblast, 1 late neutrophil. Normal marrow - 100X

Миелобласт

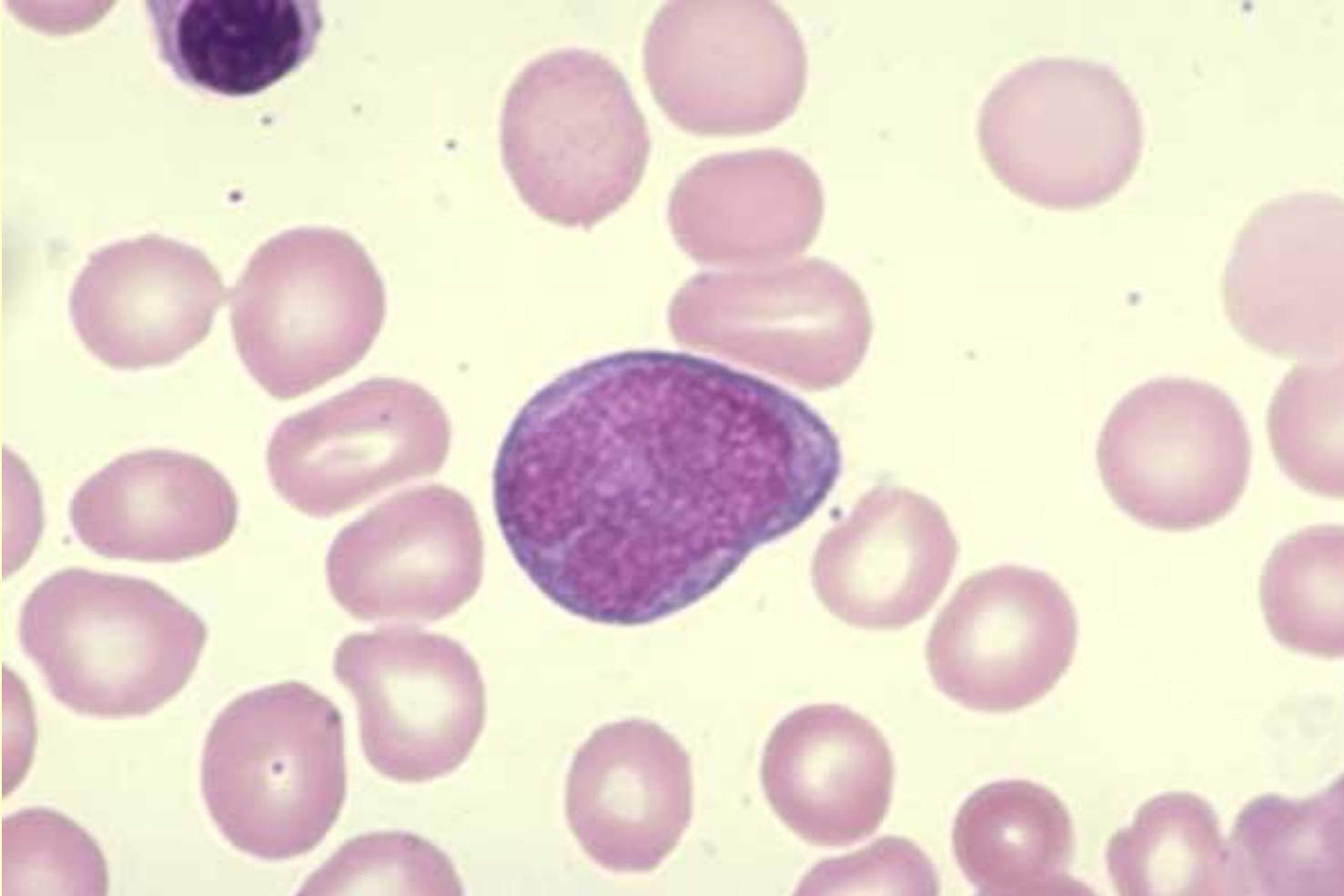
Myeloblast, neutrophilic metamyelocyte, normal marrow



One myeloblast, 1 neutrophilic metamyelocyte. Normal marrow - 100X

Миелобласт

Myeloblast, late NRBC, normal marrow

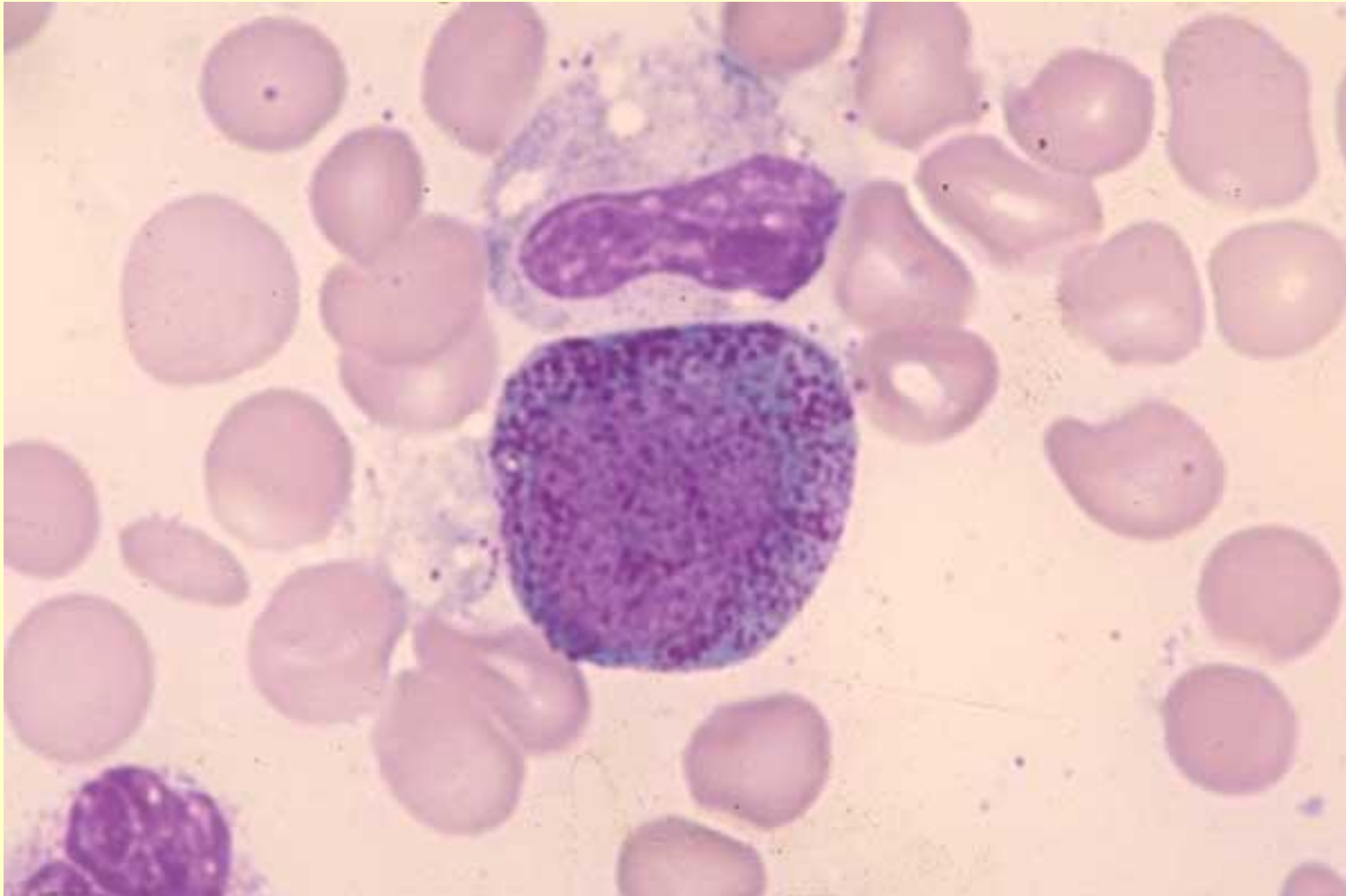


One myeloblast / monoblast, 1 late NRBC. Normal marrow - 100X

Progranulocyte, band neutrophils

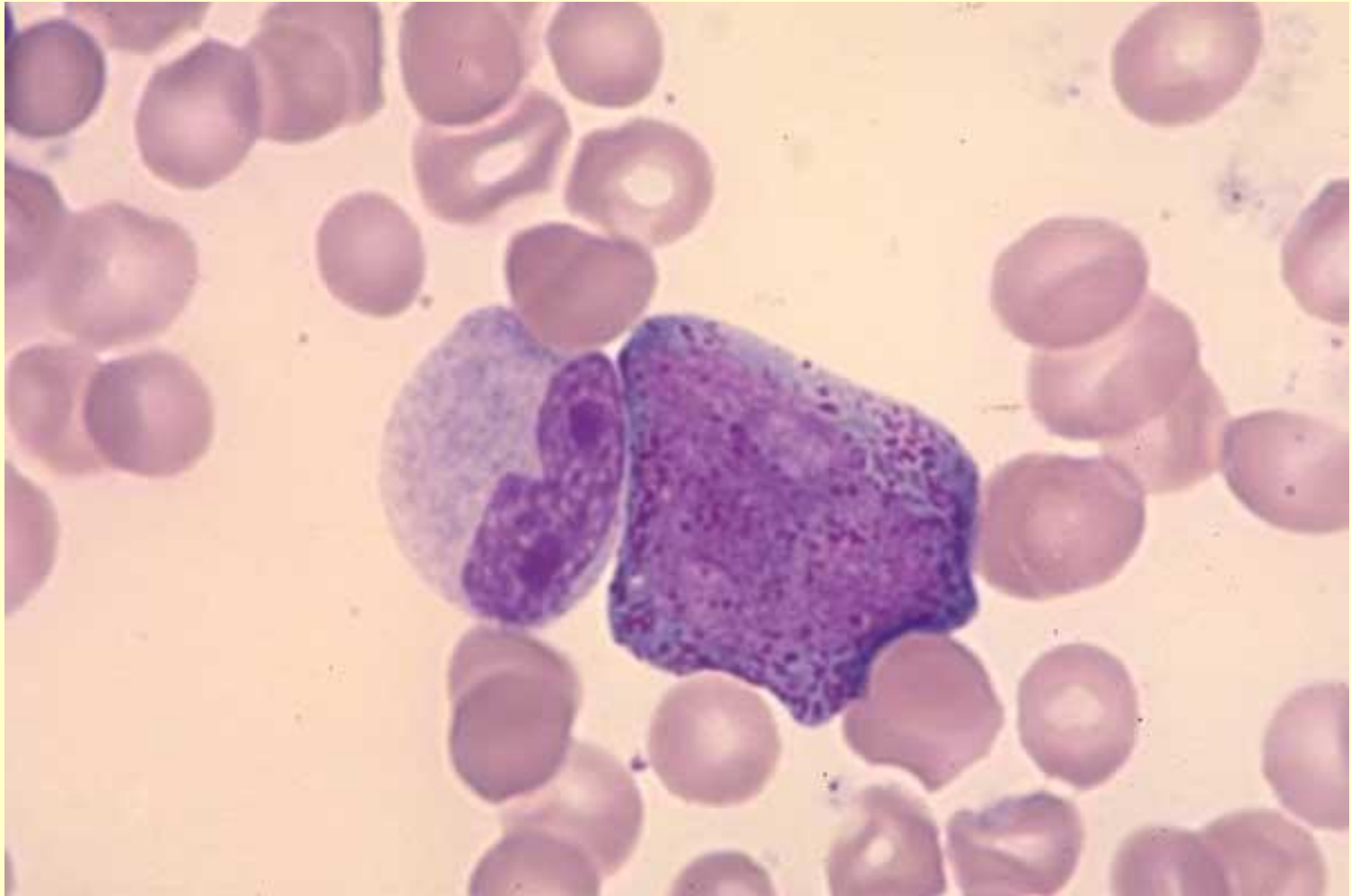
One late progranulocyte, 2 band neutrophils.

Normal marrow - 100X



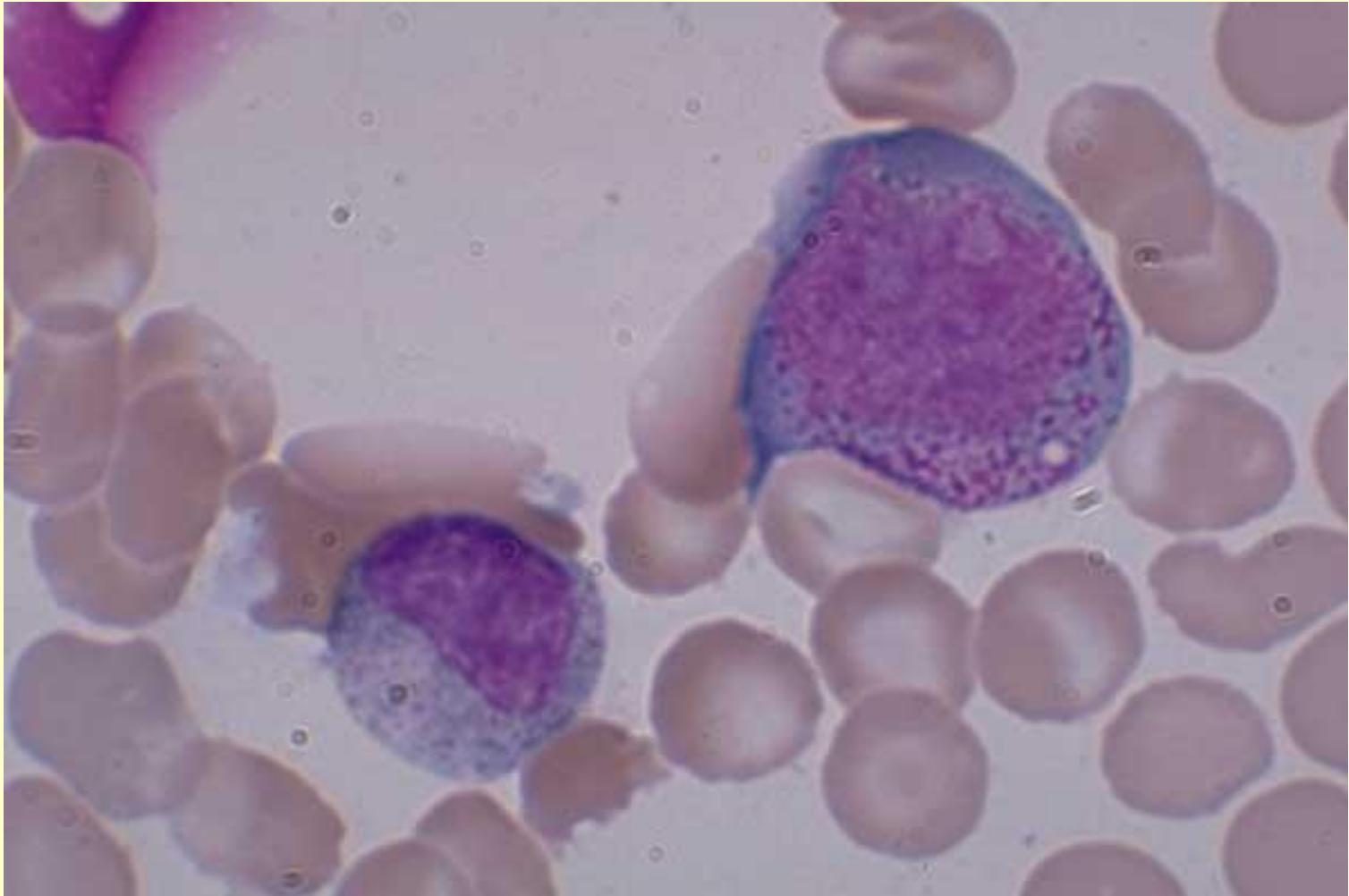
Progranulocyte, band neutrophils, normal marrow

One progranulocyte, 2 band neutrophils. Normal marrow
- 100X



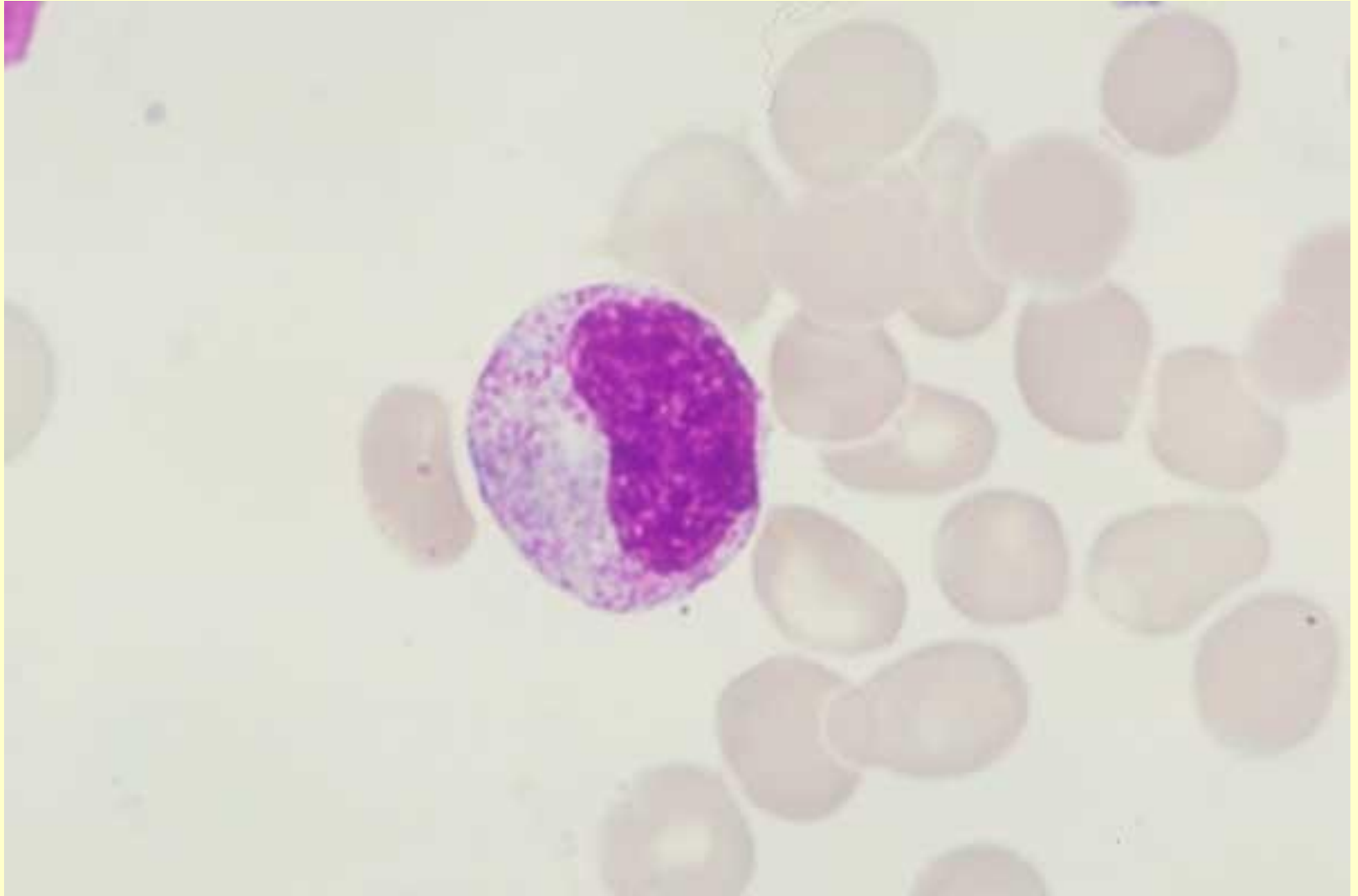
Progranulocyte, myelocyte, normal marrow

One progranulocyte, 1 myelocyte. Normal marrow
- 100X

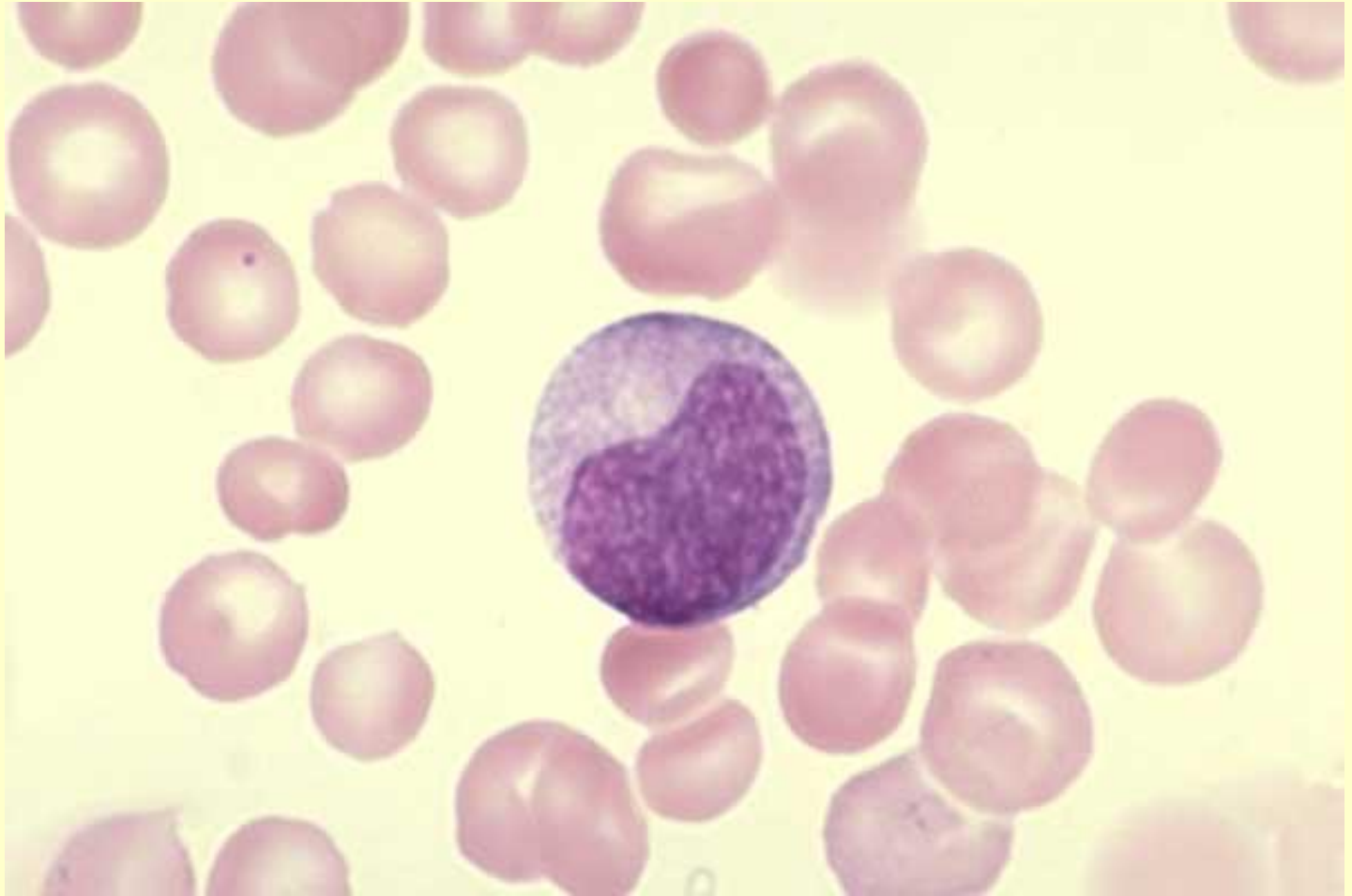

Late neutrophilic myelocyte, normal marrow

One late neutrophilic myelocyte. Normal marrow - 100X

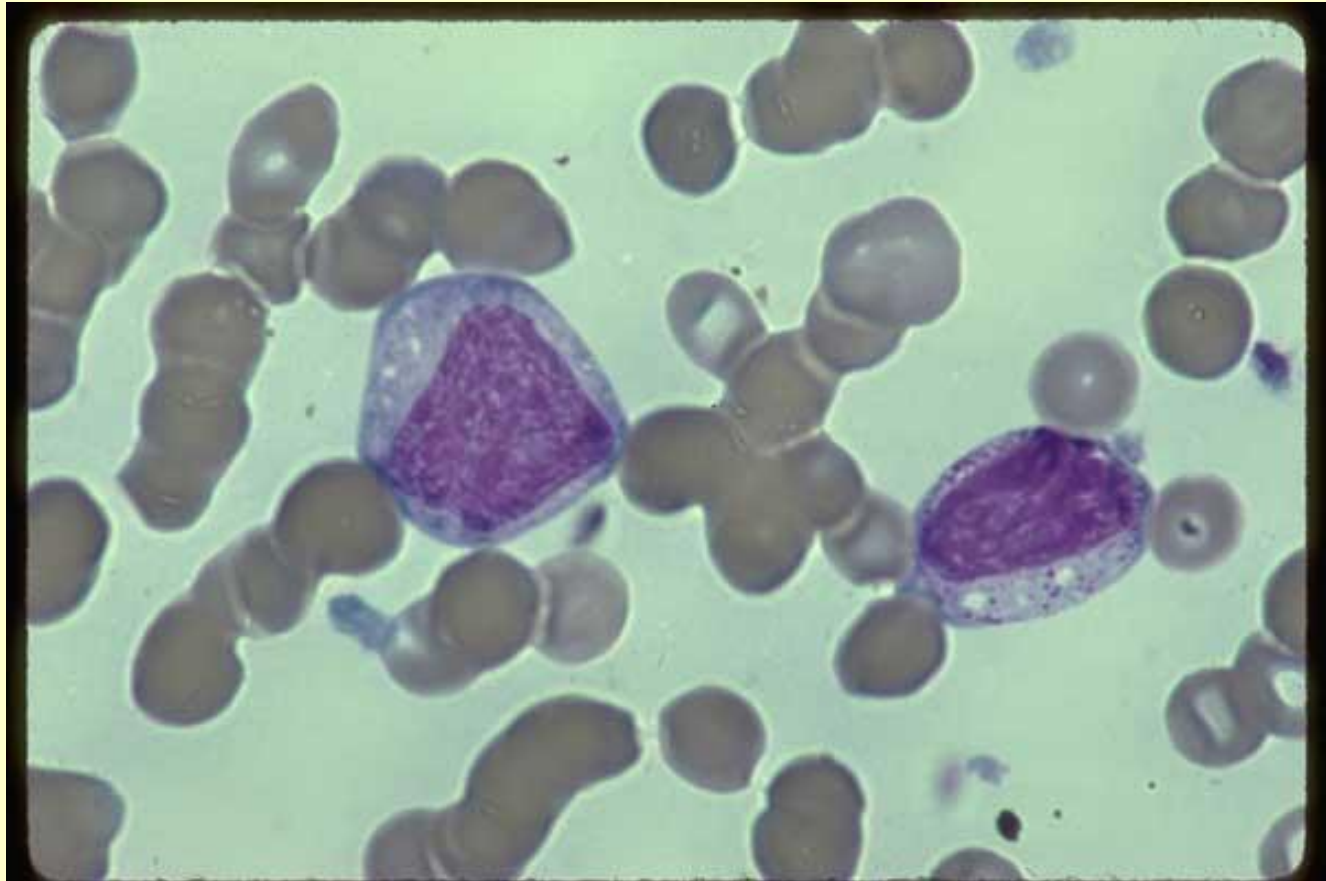


Neutrophilic myelocyte, normal marrow
One neutrophilic myelocyte. Normal marrow -
100X



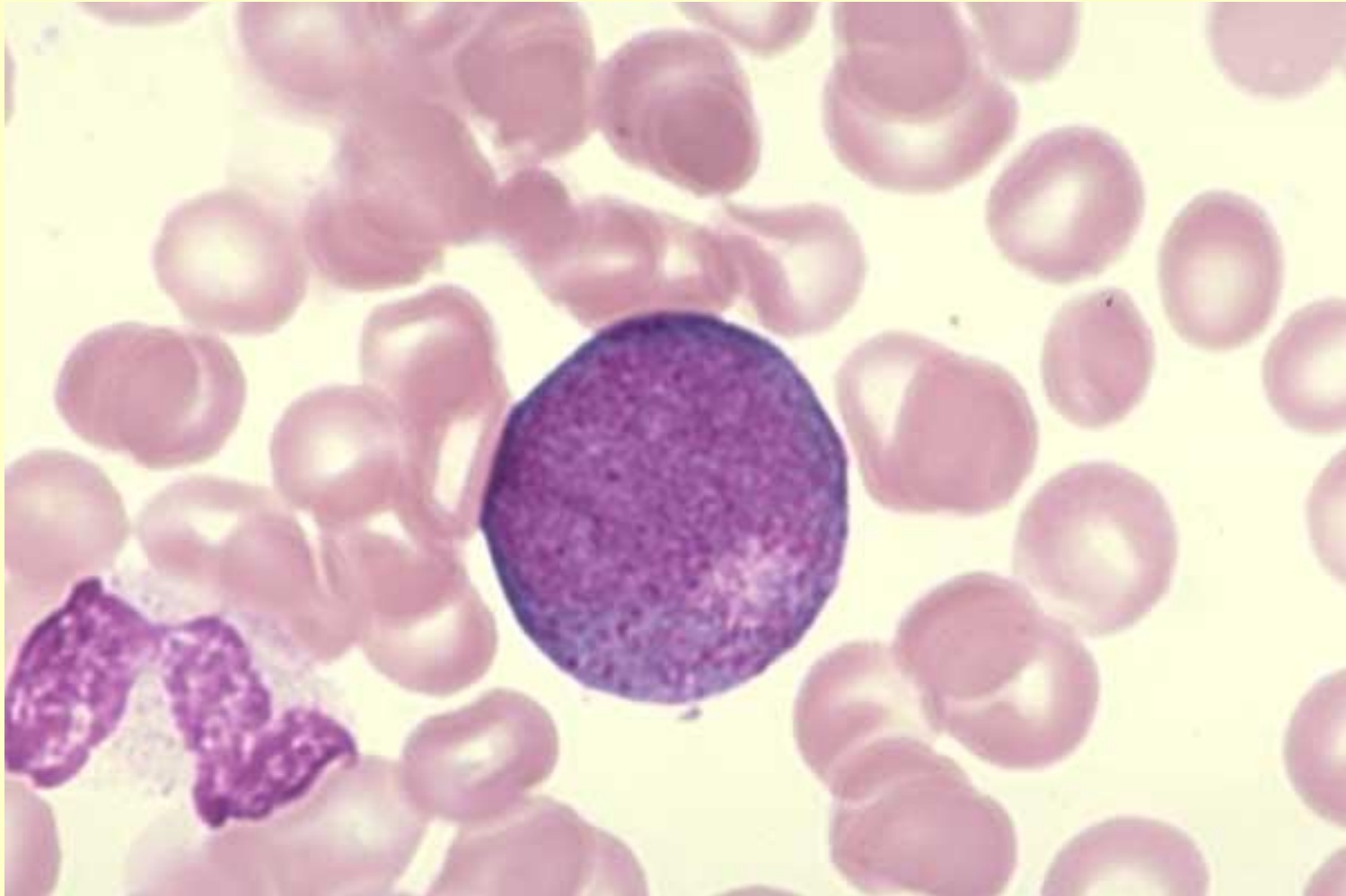
Myelocytes, abnormal platelets, AML blood

Two myelocytes, one with and the other without primary or coarse azurophilic granules. Both contain vacuoles. Their nuclear chromatin is showing some heterochromatin development. Several abnormal (agranular) platelets are present. Acute Megakaryocytic Leukemia (M-7). Blood - 100



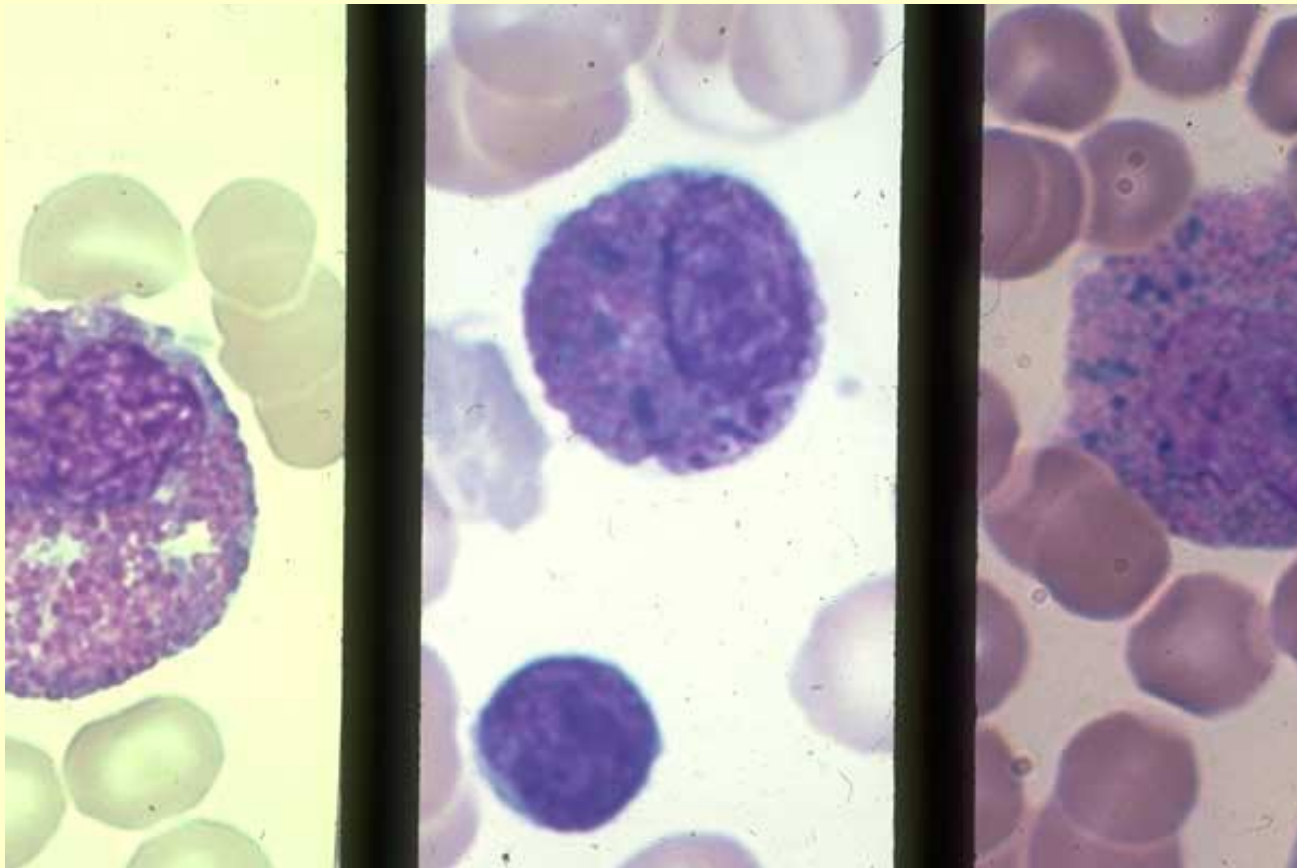
Myelocyte, disrupted band neutrophil

One early myelocyte with many azure granules, 1 disrupted band neutrophil. Normal marrow - 100X



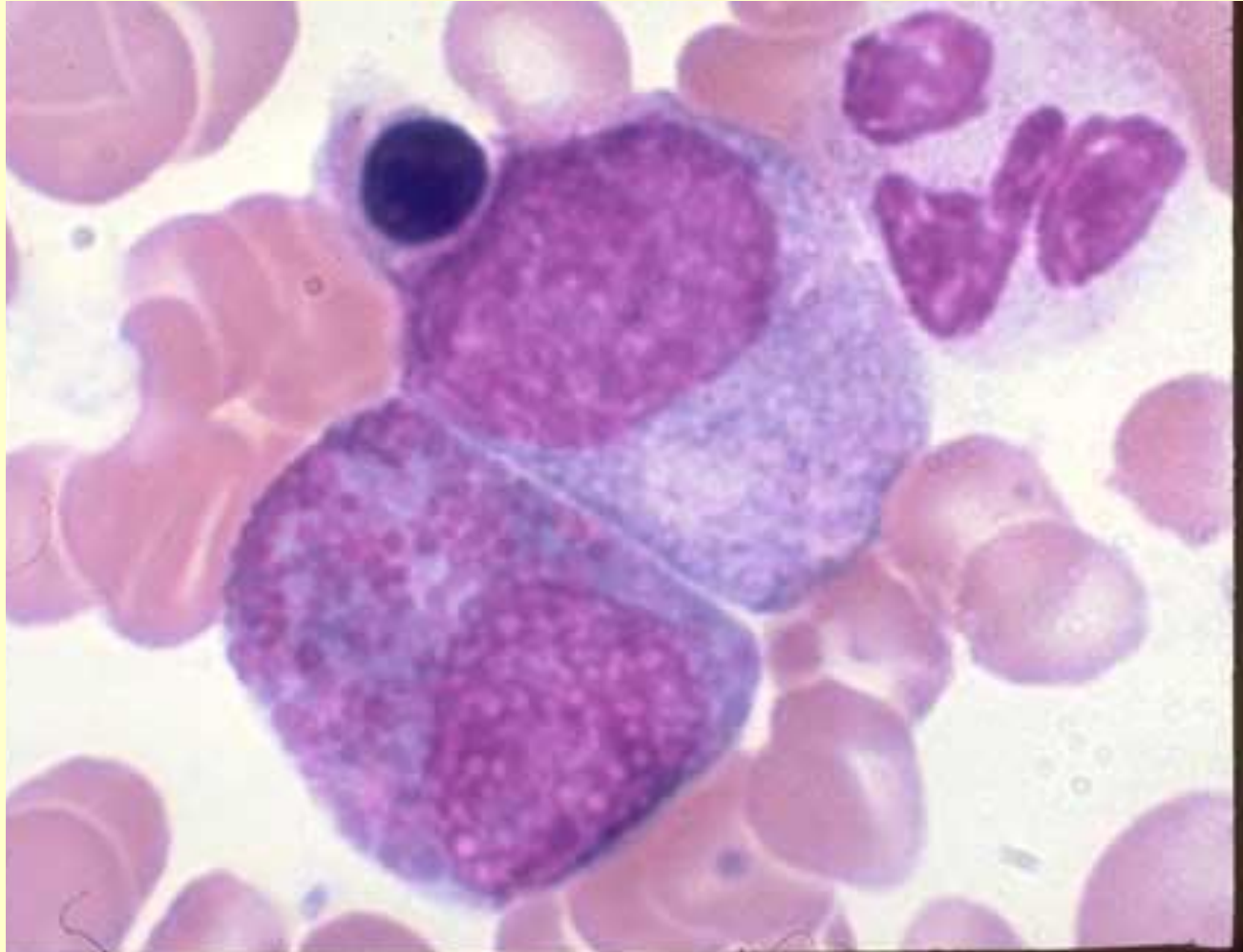
Eosinophilic myelocyte, Normal marrow

Left frame: 1 normal eosinophilic myelocyte. Center frame: 1 eosinophilic myelocyte with large blue and large eosinophilic granules. Right frame: 1 eosinophilic myelocyte with large blue granules and large eosinophilic granules. Normal marrow - 100X



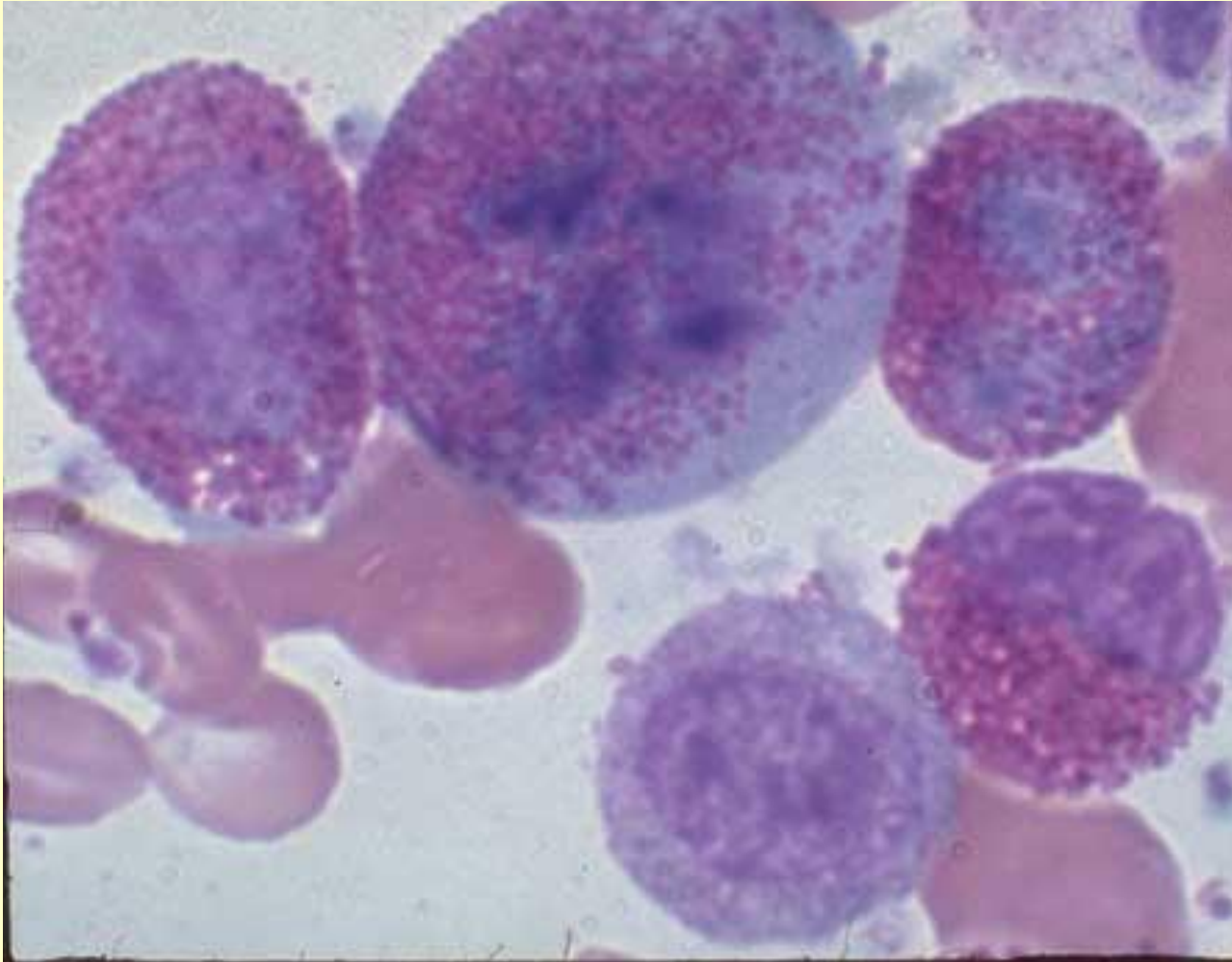
Eosinophilic myelocyte, neutrophilic myelocyte

One eosinophilic myelocyte (lower left), 1 neutrophilic myelocyte, 1 segmented neutrophil, 1 late NRBC. Normal marrow - 100X



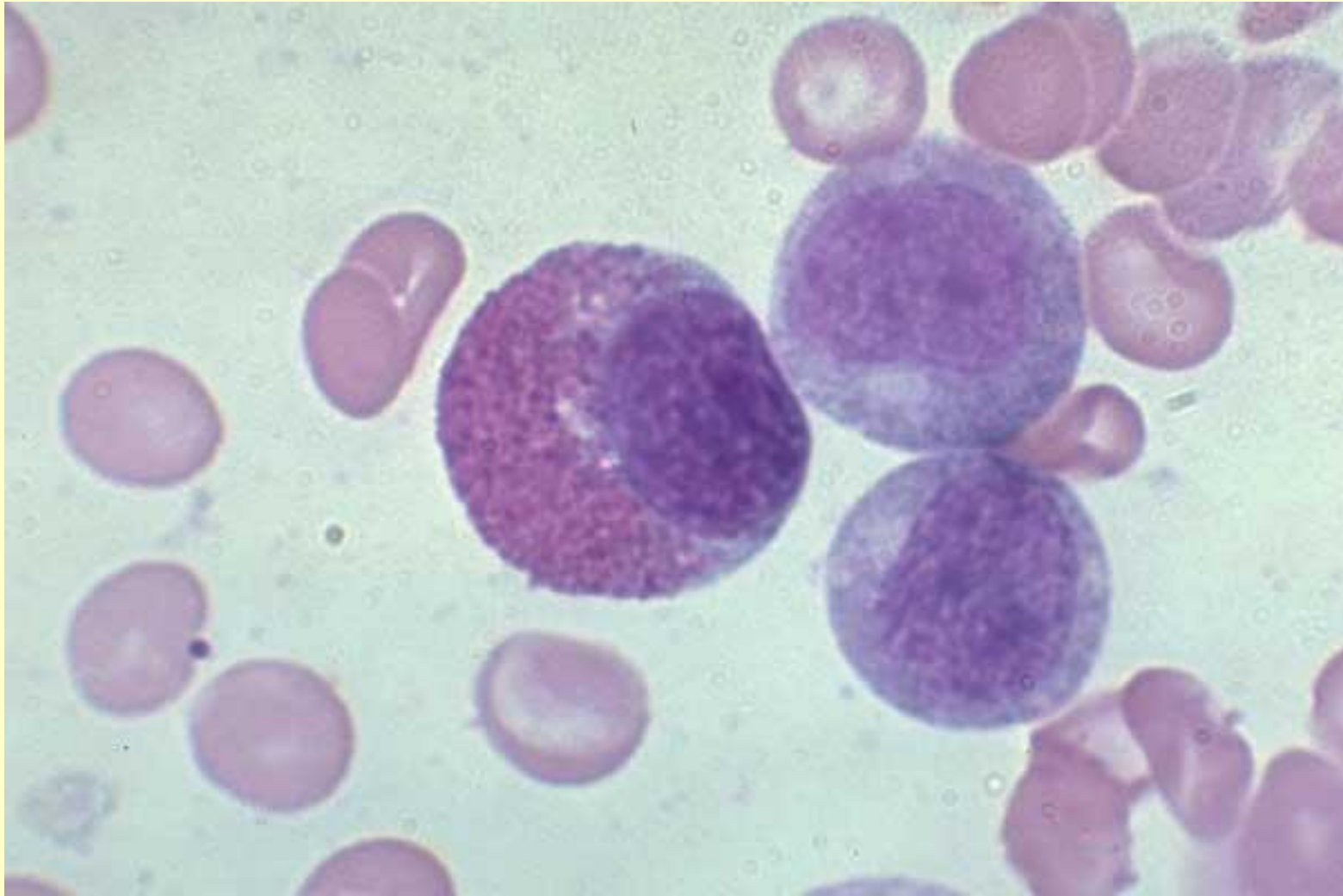
Eosinophilic myelocyte, eosinophilic metamyelocyte, mitosis

One eosinophilic myelocyte (left), 1 eosinophilic metamyelocyte (lower right),
1 eosinophilic band (top right), 1 intermediate (myelocyte) eosinophil in
mitosis, 1 neutrophilic myelocyte. Normal marrow - 100X



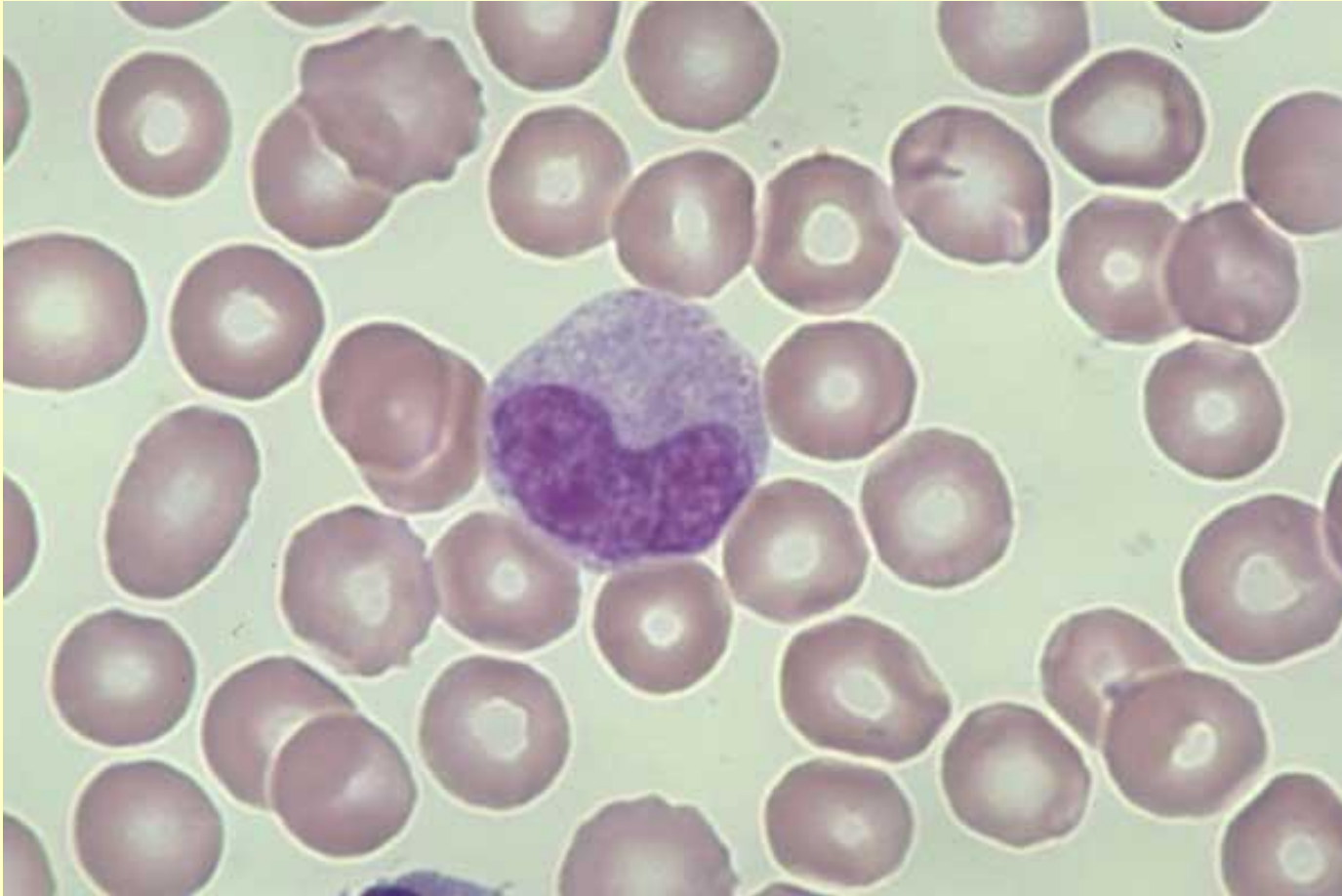
Eosinophilic myelocyte, neutrophilic myelocytes

One eosinophilic myelocyte (left), 2 neutrophilic myelocytes. Normal marrow - 100X



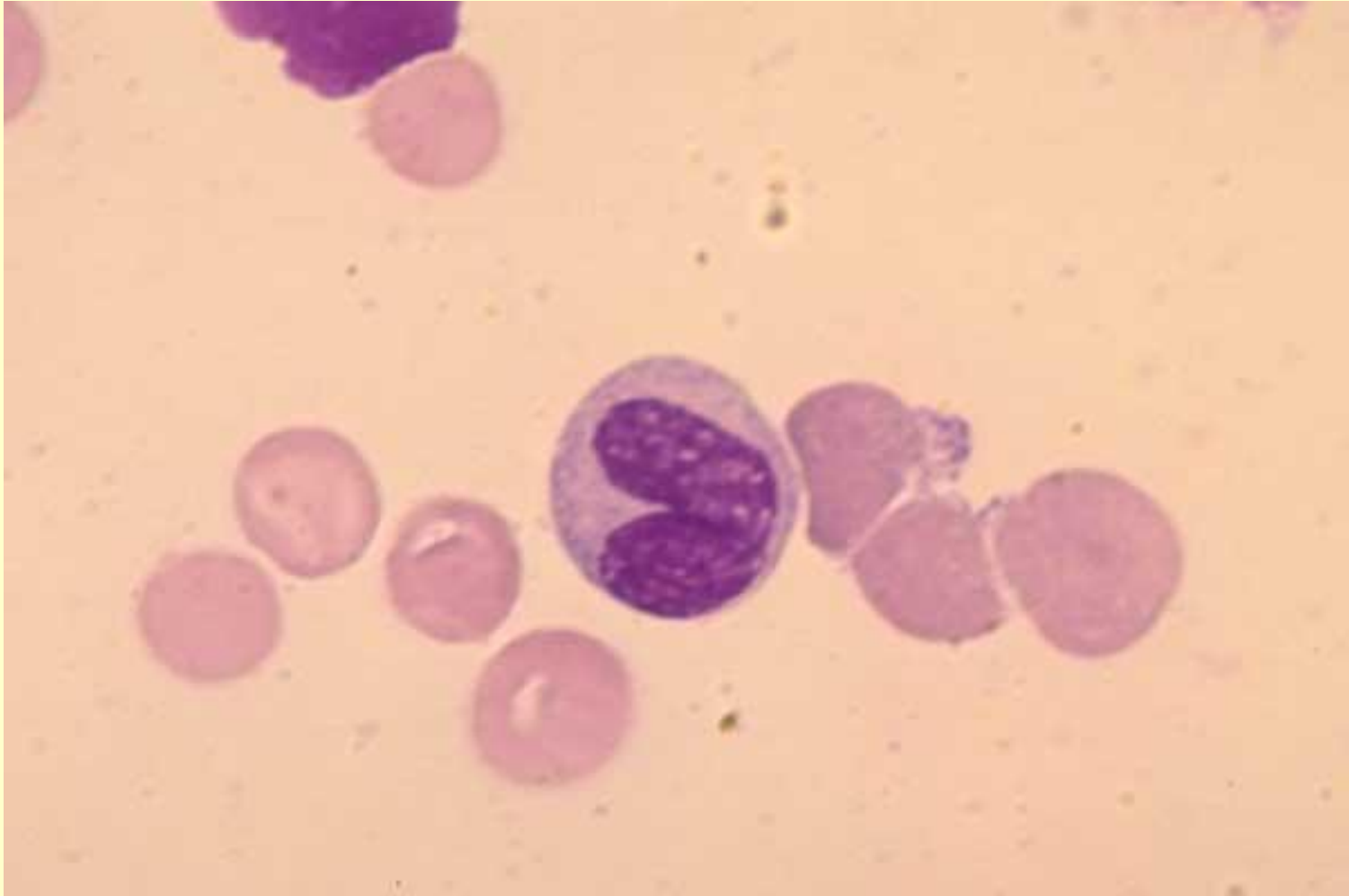
Metamyelocyte, normal marrow

One metamyelocyte - late. Normal marrow - 100X



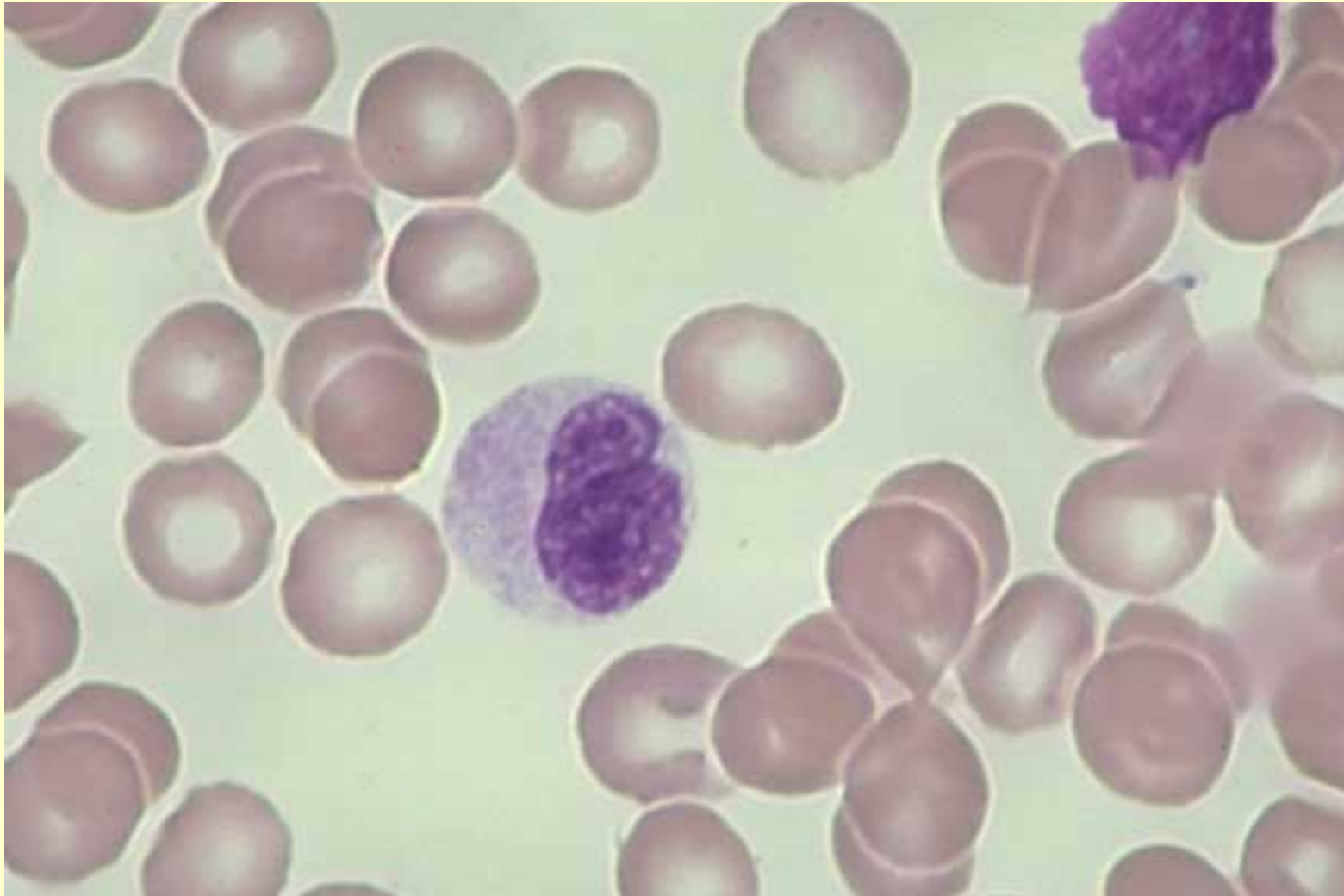
Metamyelocyte, smudge cell, normal marrow

One metamyelocyte, 1 smudge cell. Normal marrow - 100X



Metamyelocyte, smudge cell, normal marrow

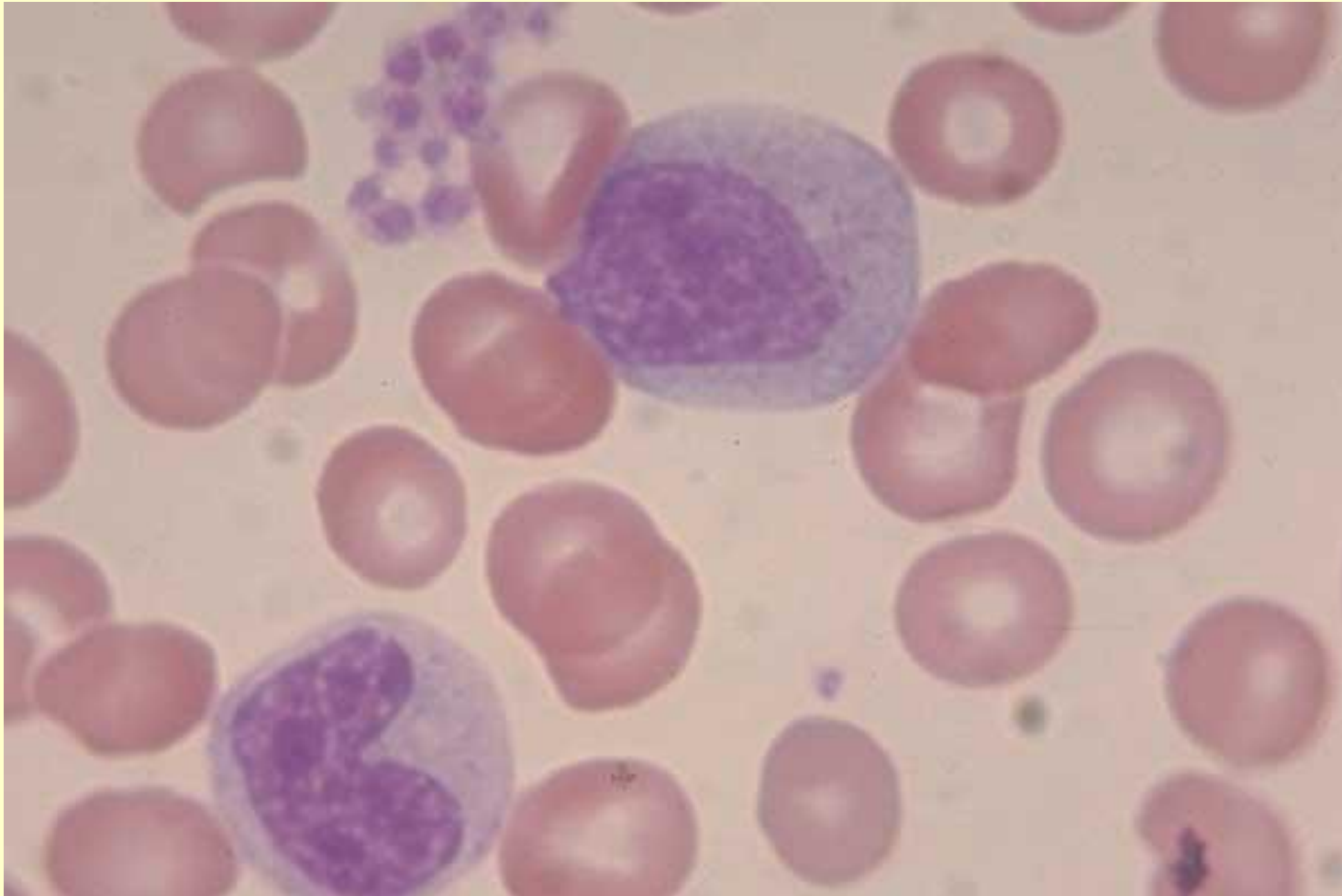
One metamyelocyte - early, 1 smudge cell. Normal marrow
- 100X



Metamyelocyte, neutrophilic myelocyte, normal marrow

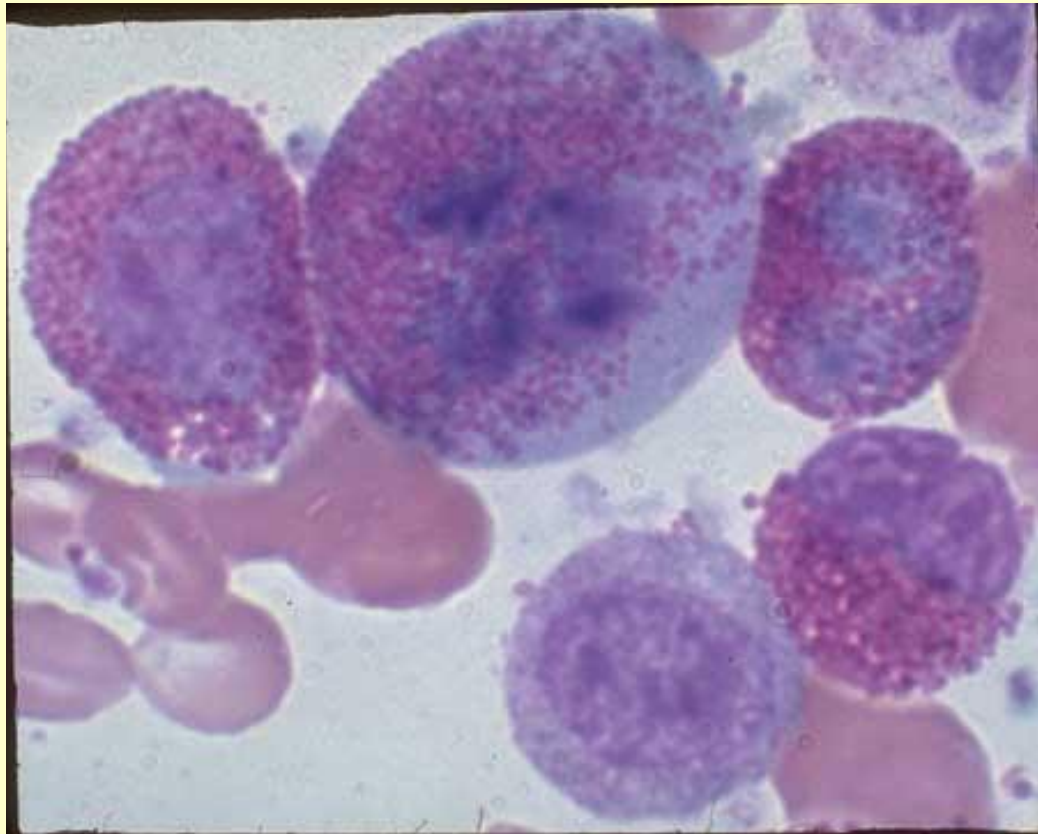
One metamyelocyte - early, 1 neutrophilic myelocyte.

Normal marrow - 100X



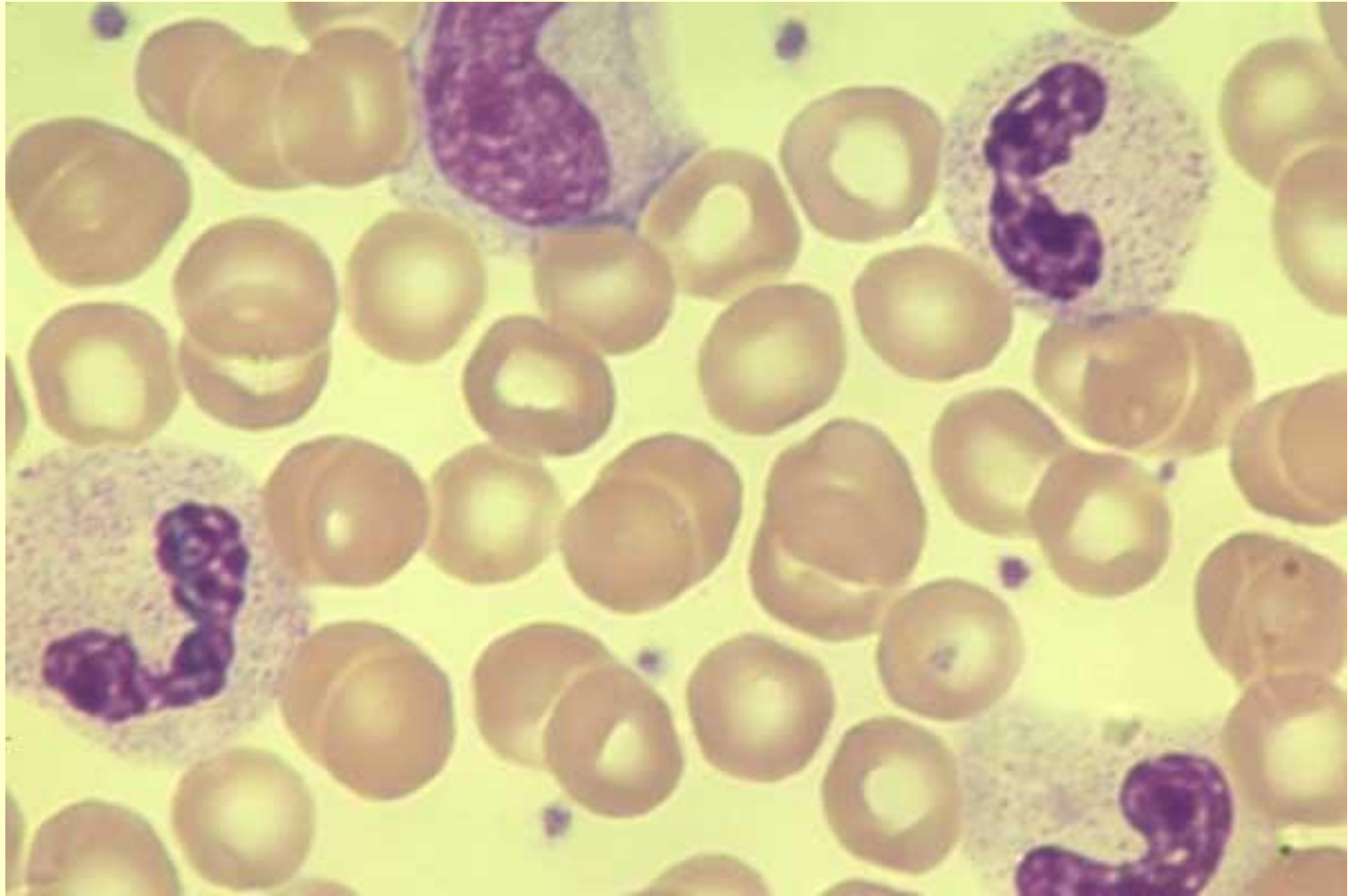
Eosinophilic myelocyte, eosinophilic metamyelocyte, mitosis

One eosinophilic myelocyte (left), 1 eosinophilic metamyelocyte (lower right), 1 eosinophilic band (top right), 1 intermediate (myelocyte) eosinophil in mitosis, 1 neutrophilic myelocyte. Normal marrow - 100X



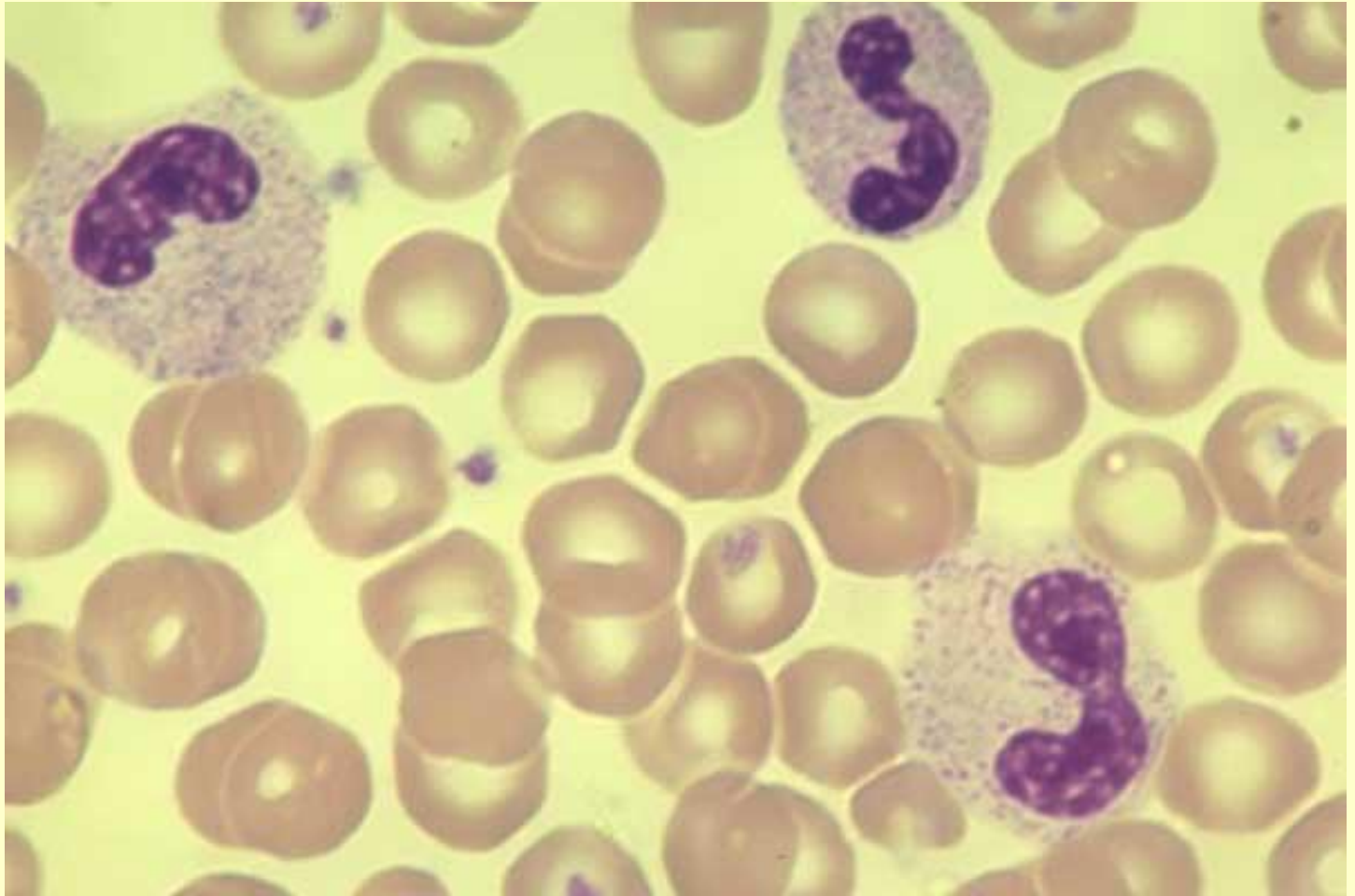
Band neutrophils, monocyte

Three band neutrophils, 1 monocyte (top left center) Note differences in chromatin and cytoplasmic color - 100X

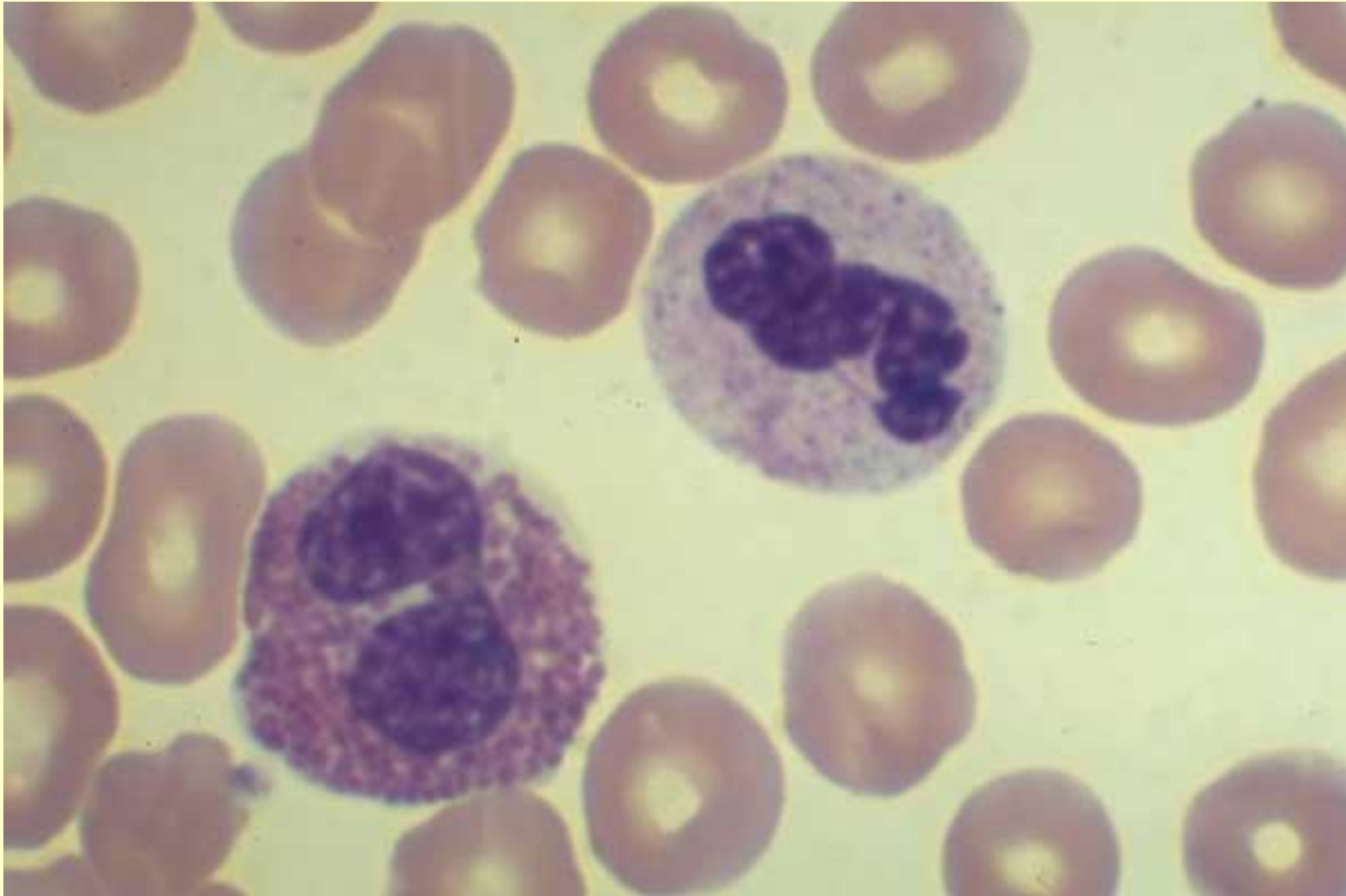


Band neutrophils

Three band neutrophils - 100X

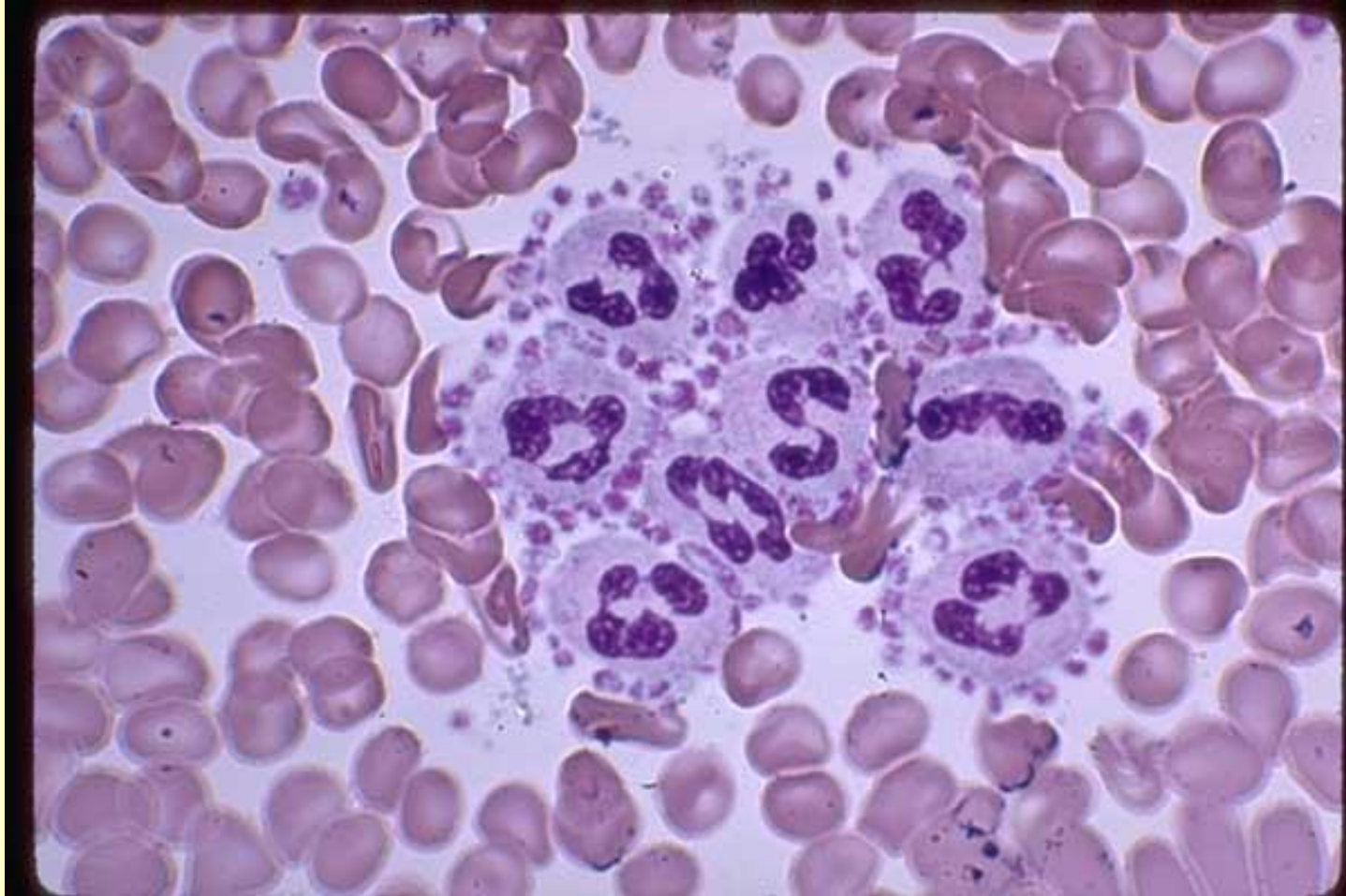


Band eosinophil, mature neutrophil, Normal blood
One band eosinophil, 1 mature neutrophil. Normal blood -
100X



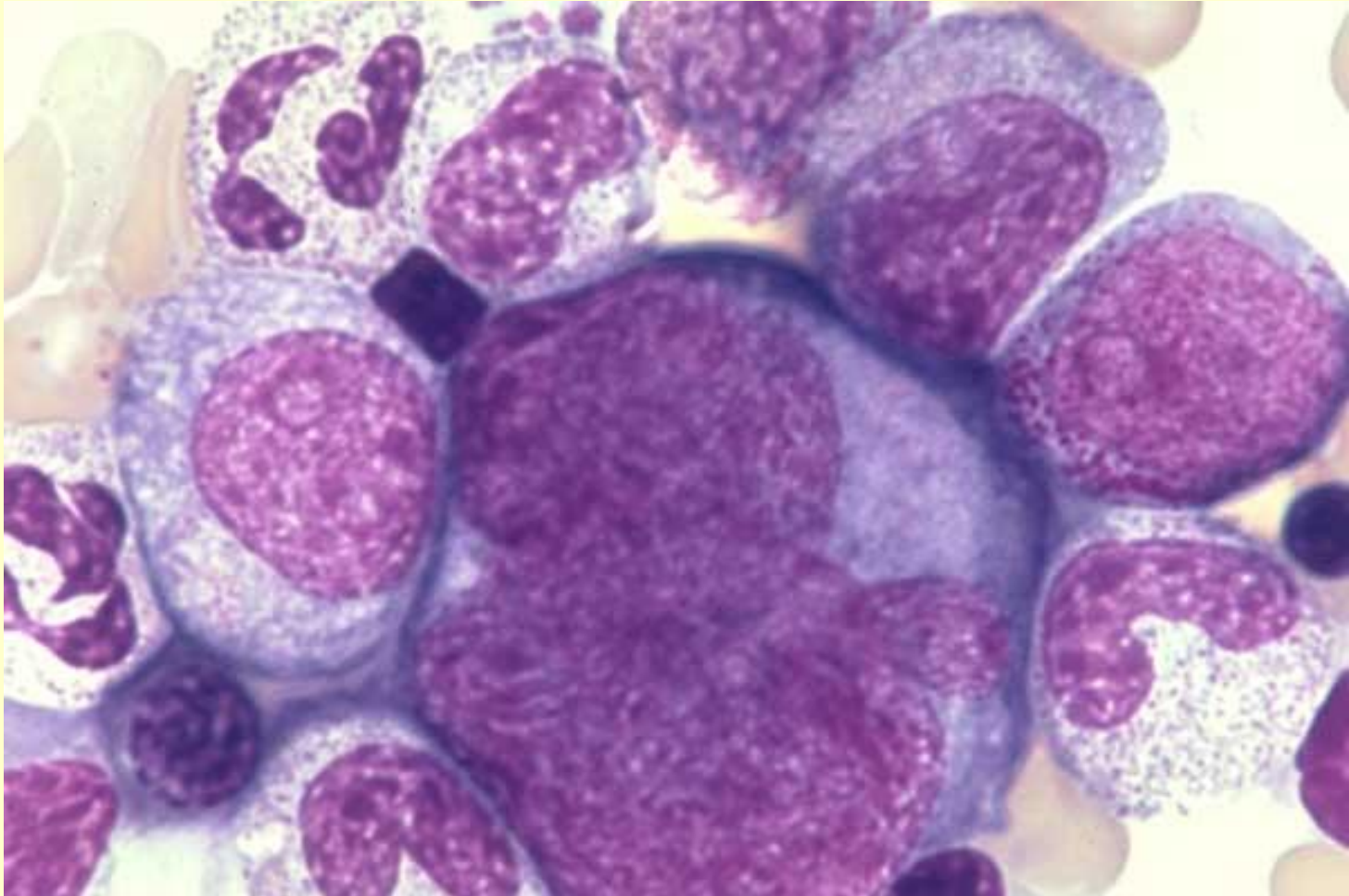
Mature Neutrophils, Platelet Satellitism

One huge clump of nine Mature Neutrophils, each of which is surrounded by platelets. It is probably the stickiness of the platelets for each other that enhances this clumping. The white cell count may be erroneously low in such cases. Platelet Satellitism. EDTA blood - 100X



Young megakaryocyte, neutrophilic myelocytes, normal marrow

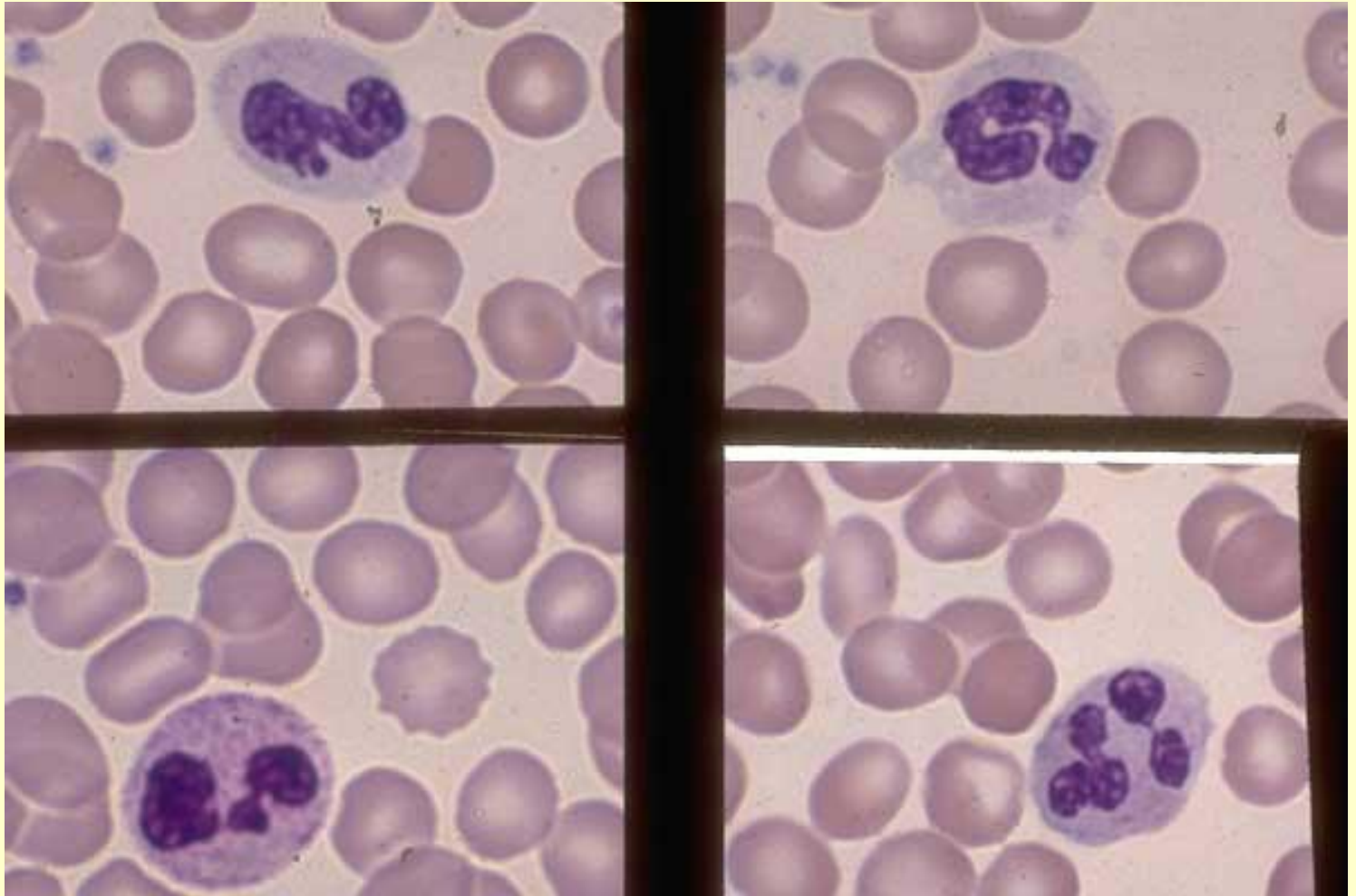
Young megakaryocyte showing early granulation adjacent to lobulated nuclei. 1 progranulocyte, 2 neutrophilic myelocytes, 1 eosinophilic myelocyte, 1 neutrophilic metamyelocyte, 2 band and 2 segmented neutrophils and 3 late NRBC surround it. Normal marrow - 100X



Segmented neutrophils, band neutrophils, normal blood

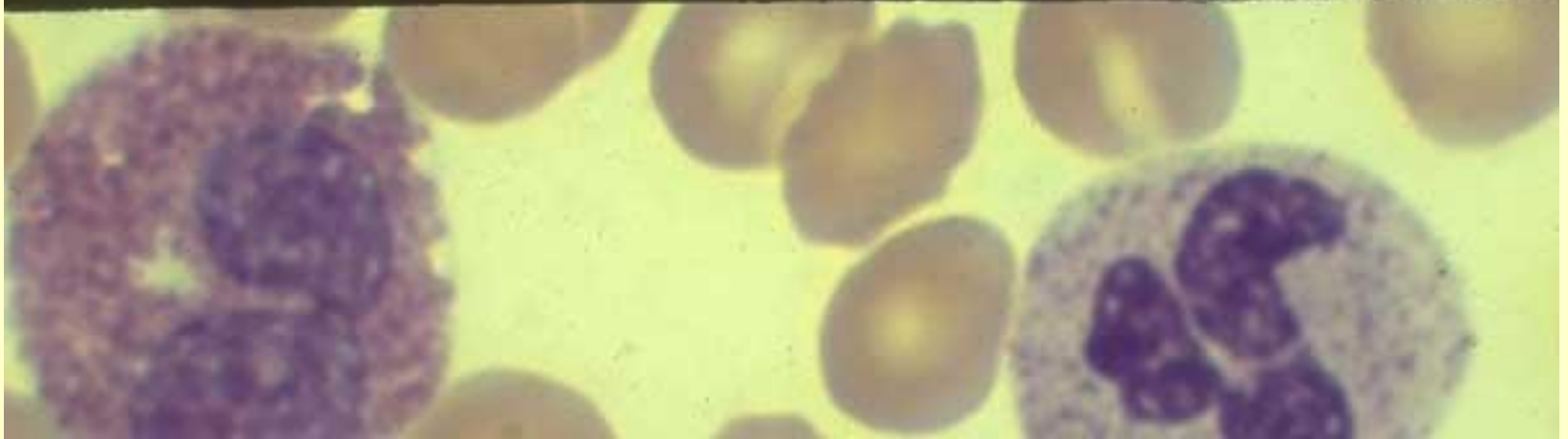
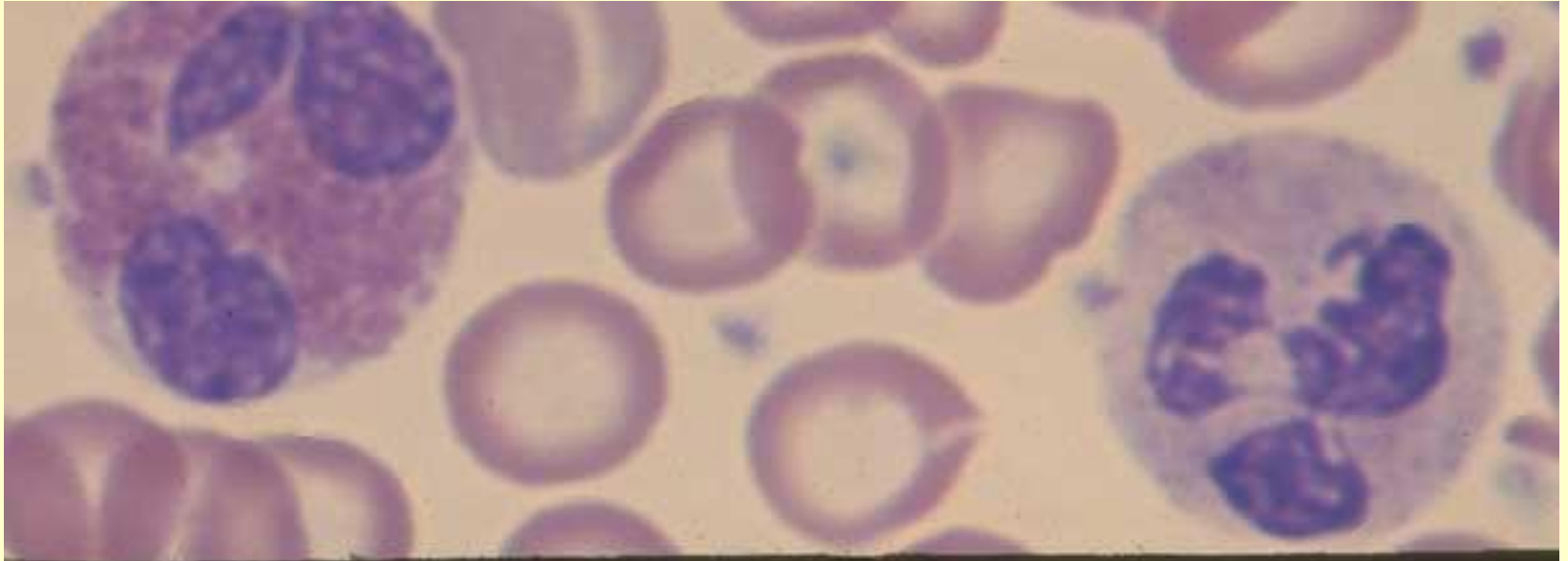
Segmented neutrophils and band neutrophils composite; 2 band neutrophils (top frames) and 2 segmented neutrophils (lower frame).

Normal blood - 100X



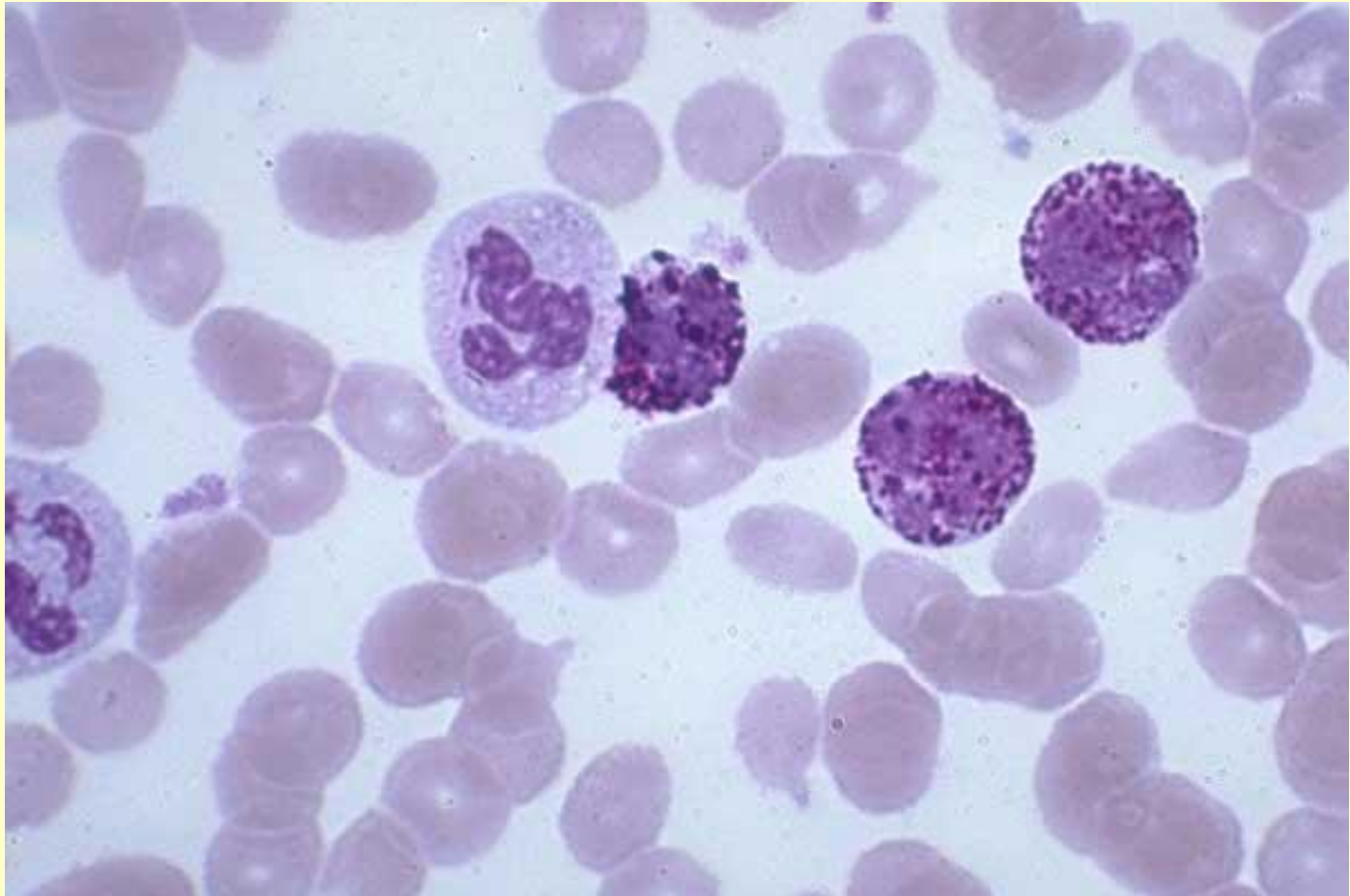
Eosinophil, Normal blood

One 3-lobed eosinophil, 1 2-lobed eosinophil, 2 mature neutrophils; composite. Normal blood - 100X



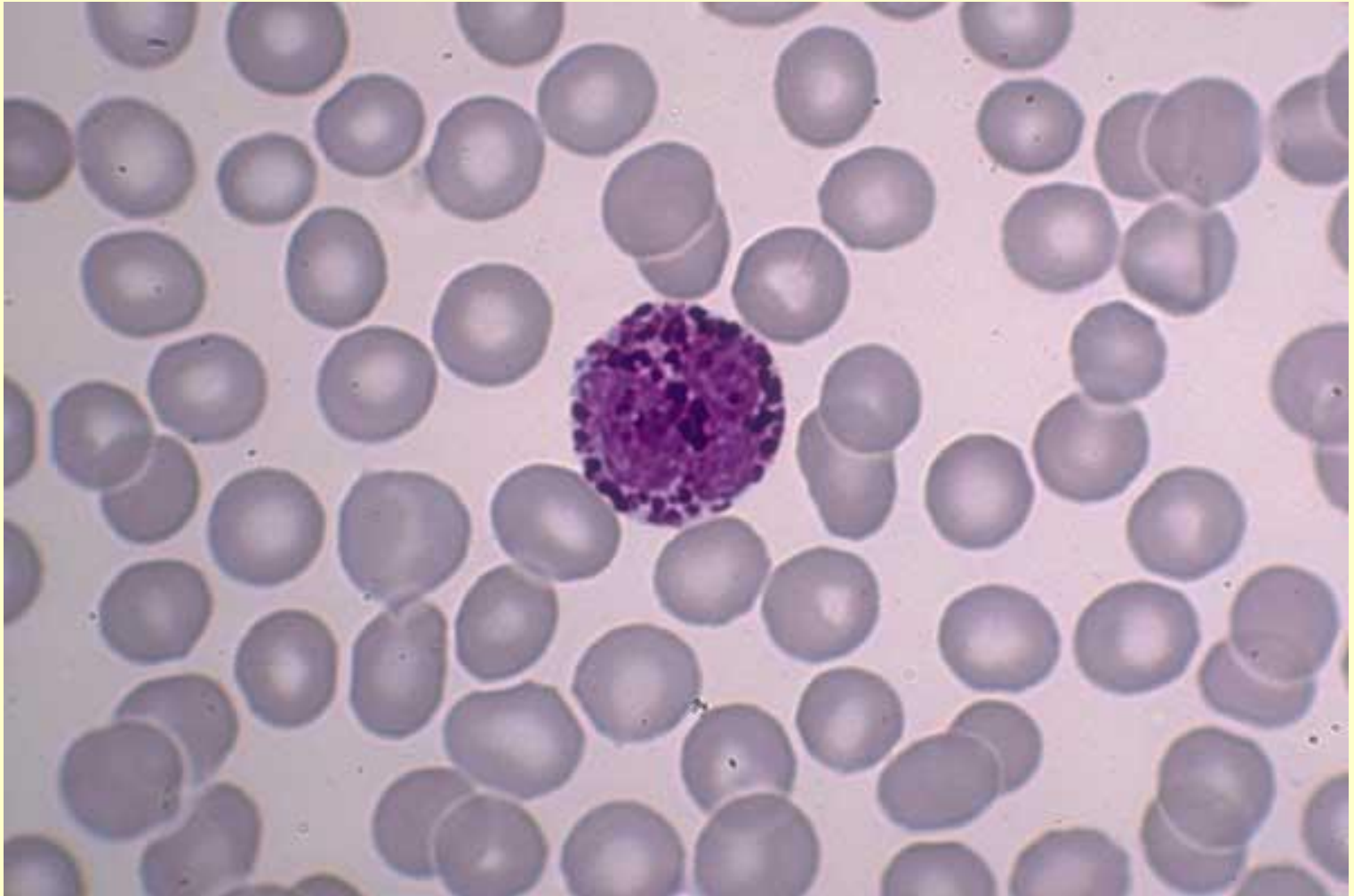
Basophils, mature neutrophils, CML blood

Three mature basophils, 2 mature neutrophils. Chronic myeloid leukemia blood - 100X

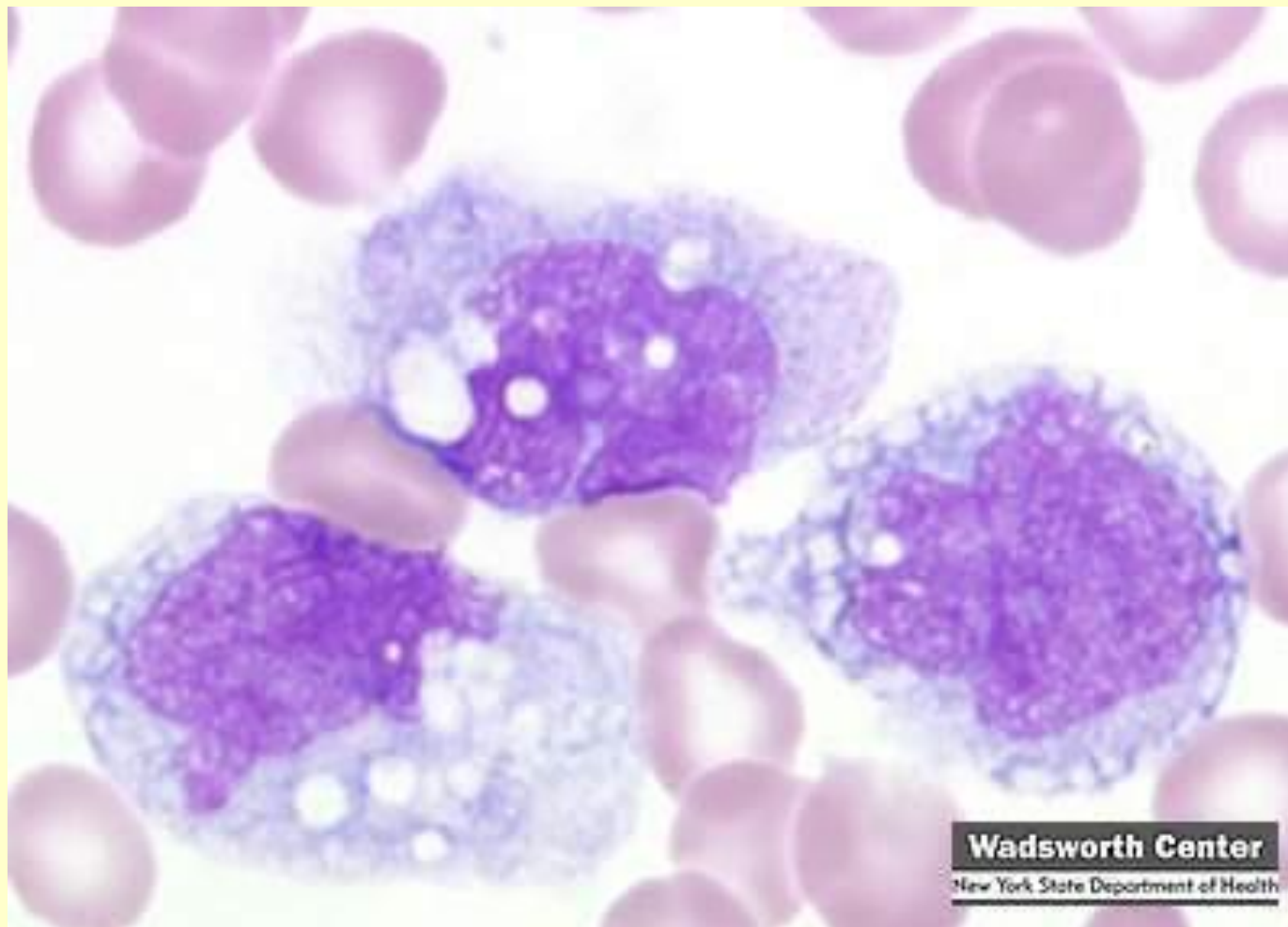


Basophil

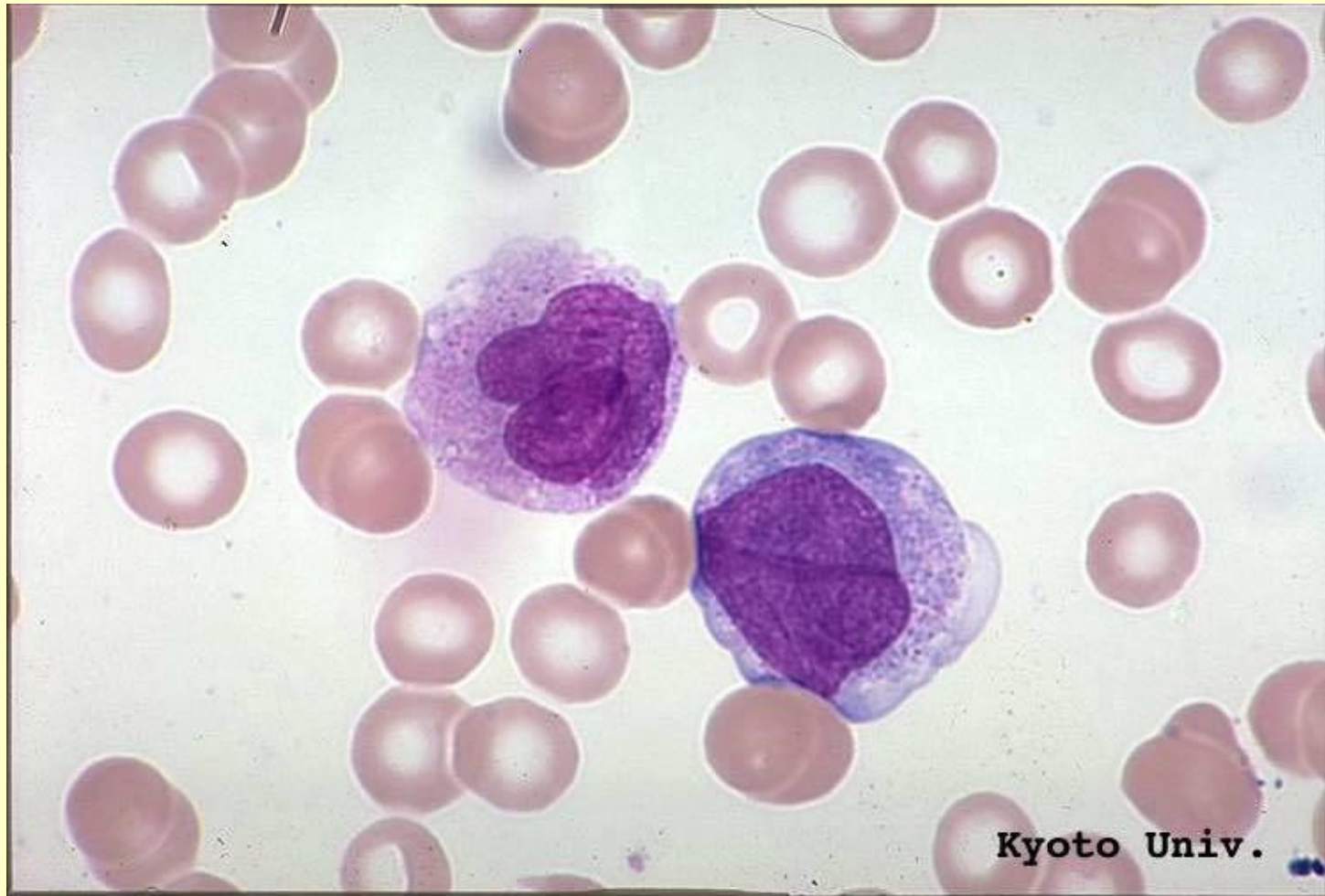
One mature basophil. Normal blood - 100X



Монобласт

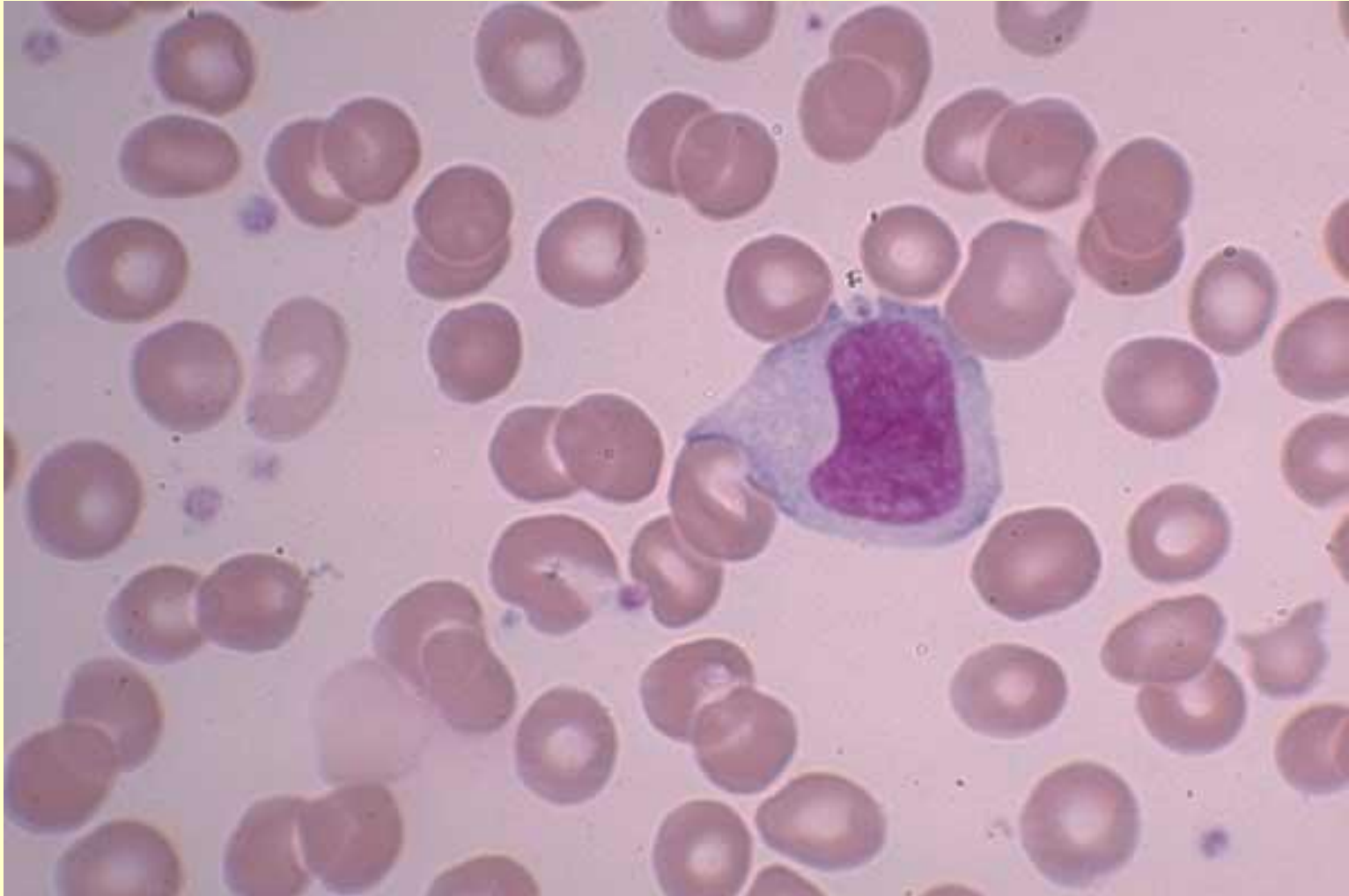


Промоноцит

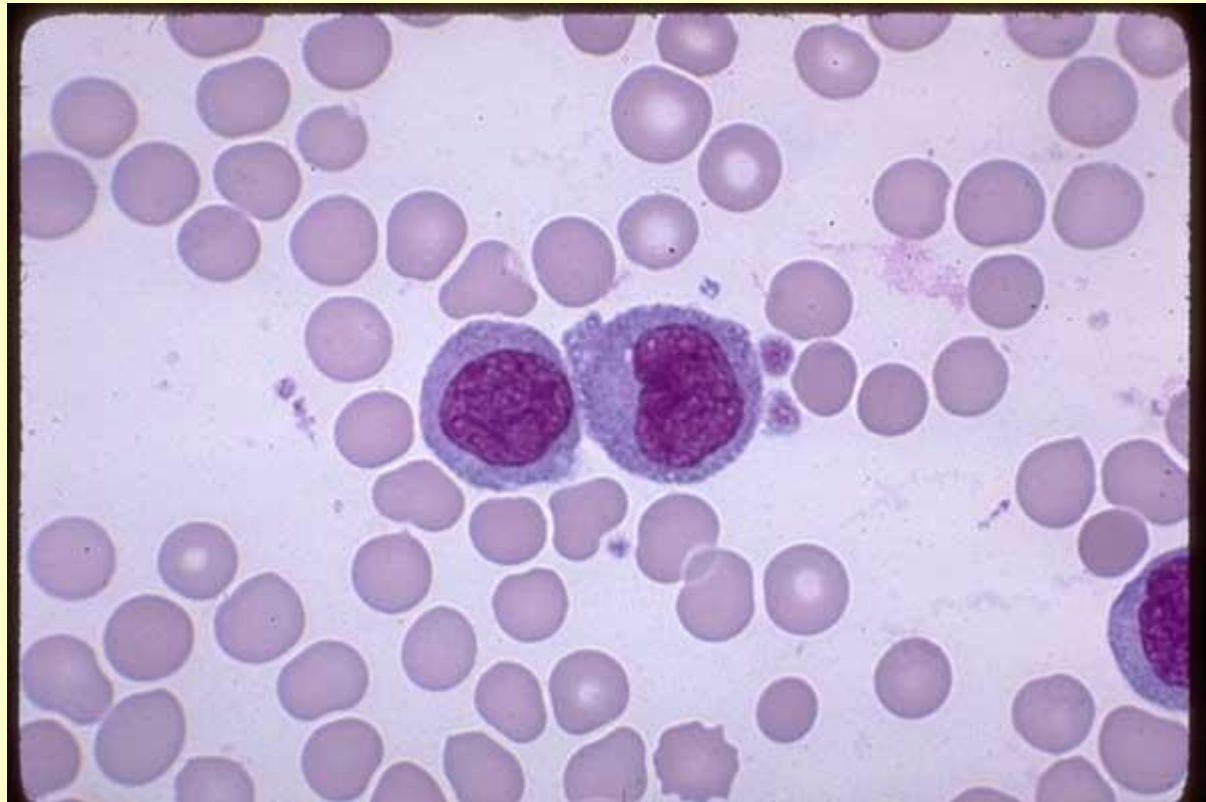

Young monocyte, normal blood

One young monocyte with immature chromatin and nucleoli. Normal blood - 100X

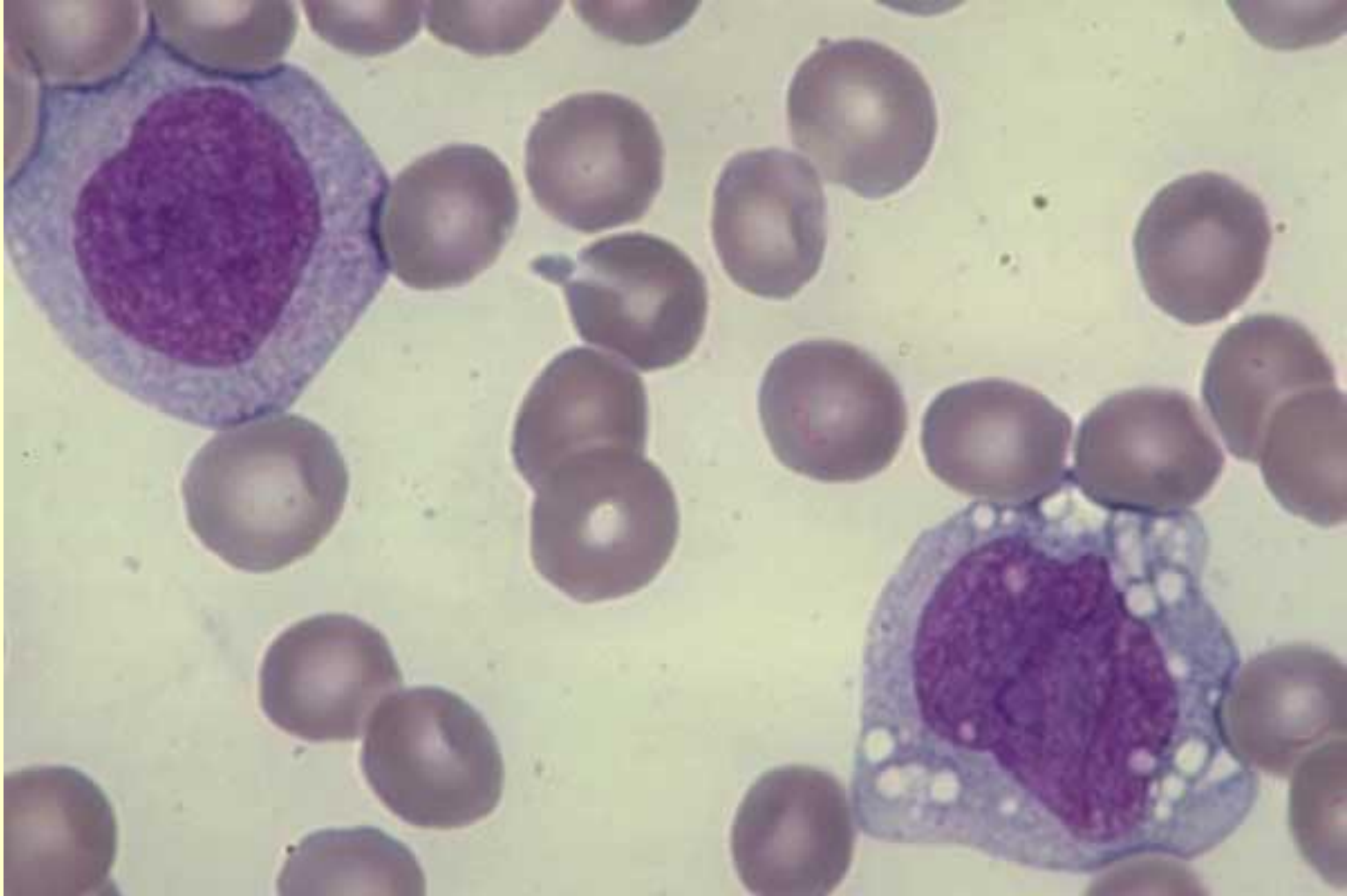


Immature Monocytes, cytoplasmic fragmentation, M-5
Two Immature Monocytes, one of which shows cytoplasmic fragmentation. These fragments resemble Platelets and may be erroneously counted as such. The two fragments to the right of the monocytes may be real platelets. Acute Monocytic Leukemia (M-5). Blood - 100X



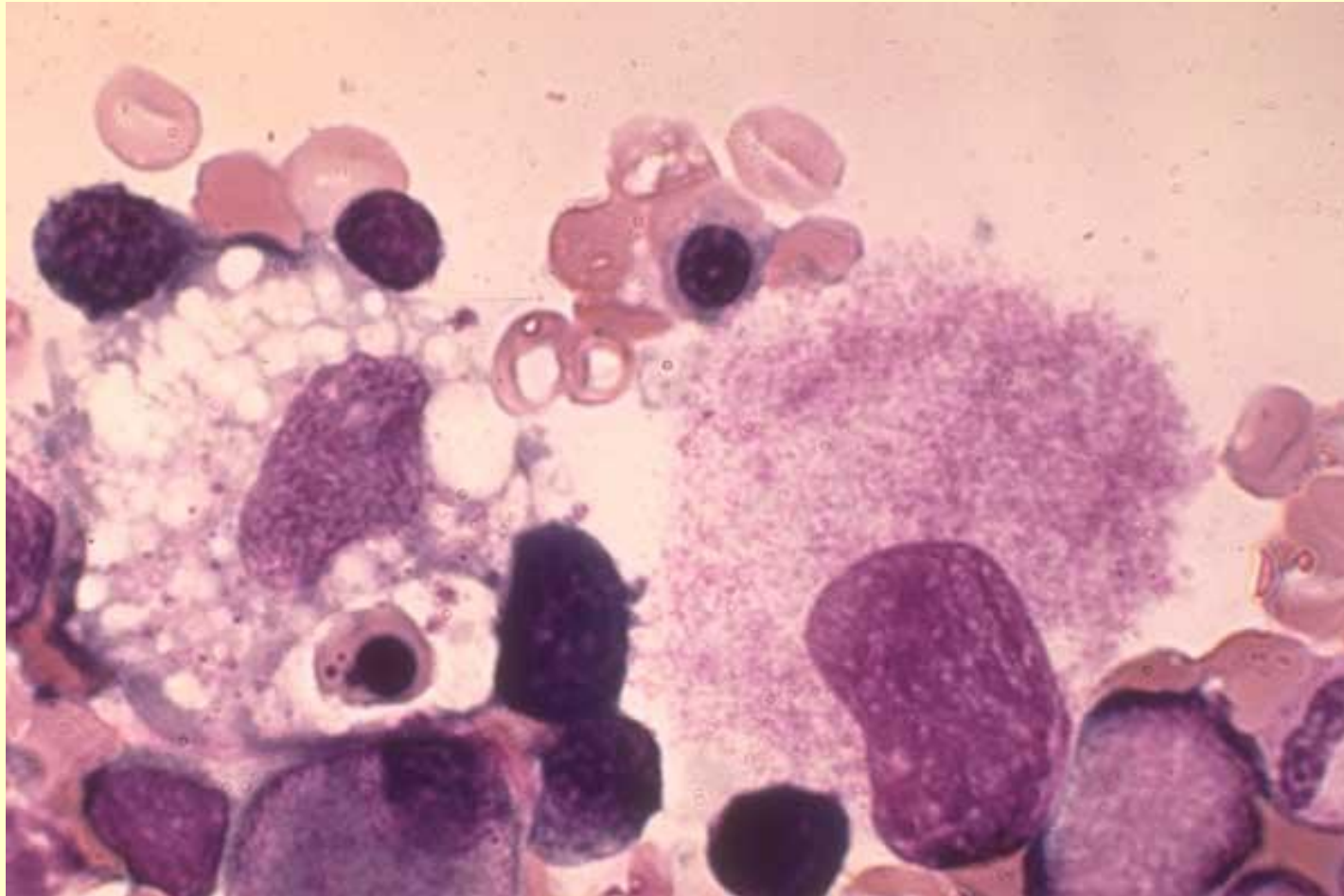
Young monocytes, normal blood

Two young monocytes, 1 with many vacuoles. Normal blood - 100X



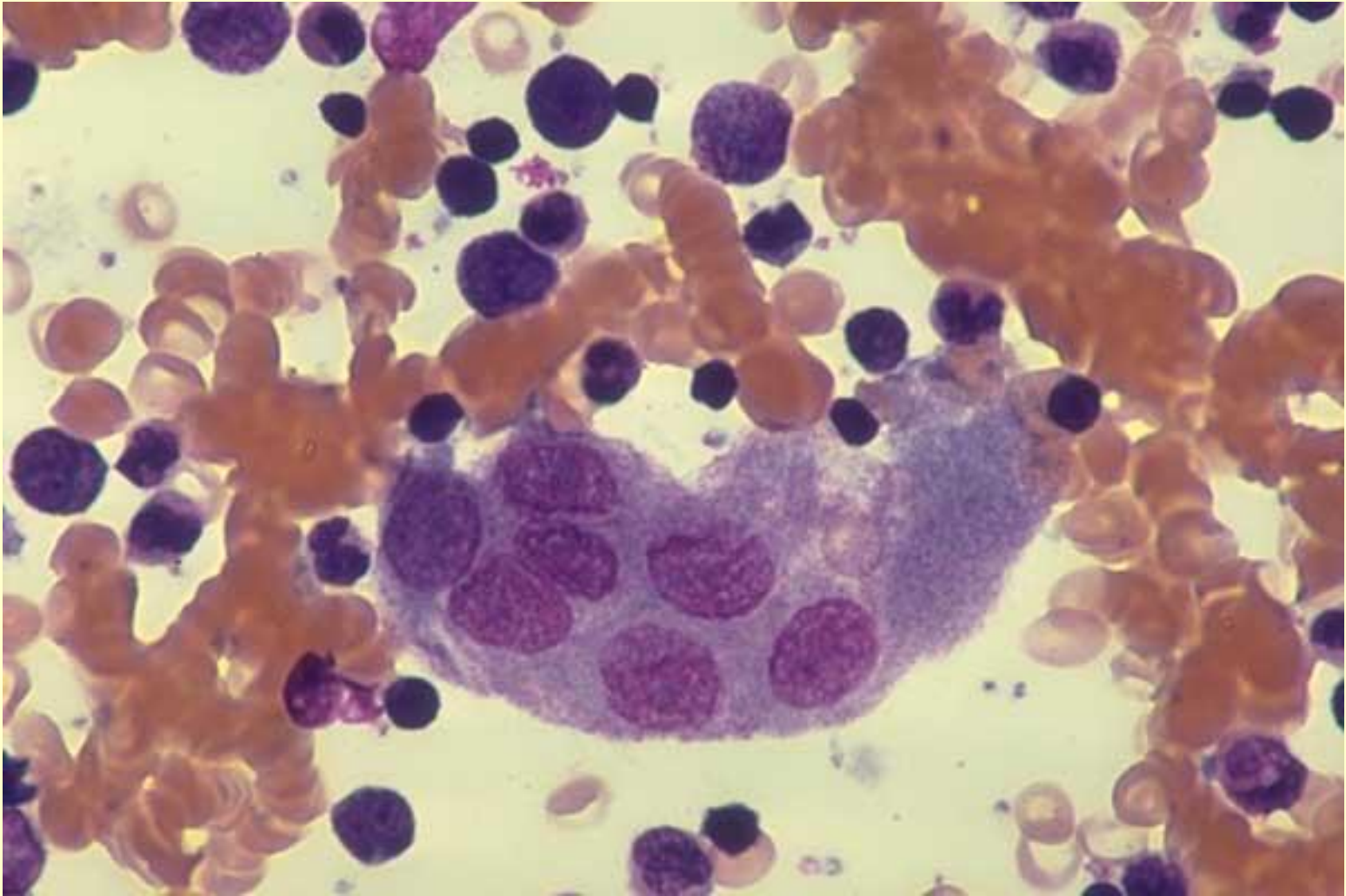
Macrophage, mature megakaryocyte, normal marrow

A macrophage with an oval shaped nucleus and a highly vacuolated cytoplasm containing a NRBC and a few scattered azure granules is at left center. A mature megakaryocyte with a single large nucleus and a fully granulated cytoplasm lies to its right. Normal marrow - 100X

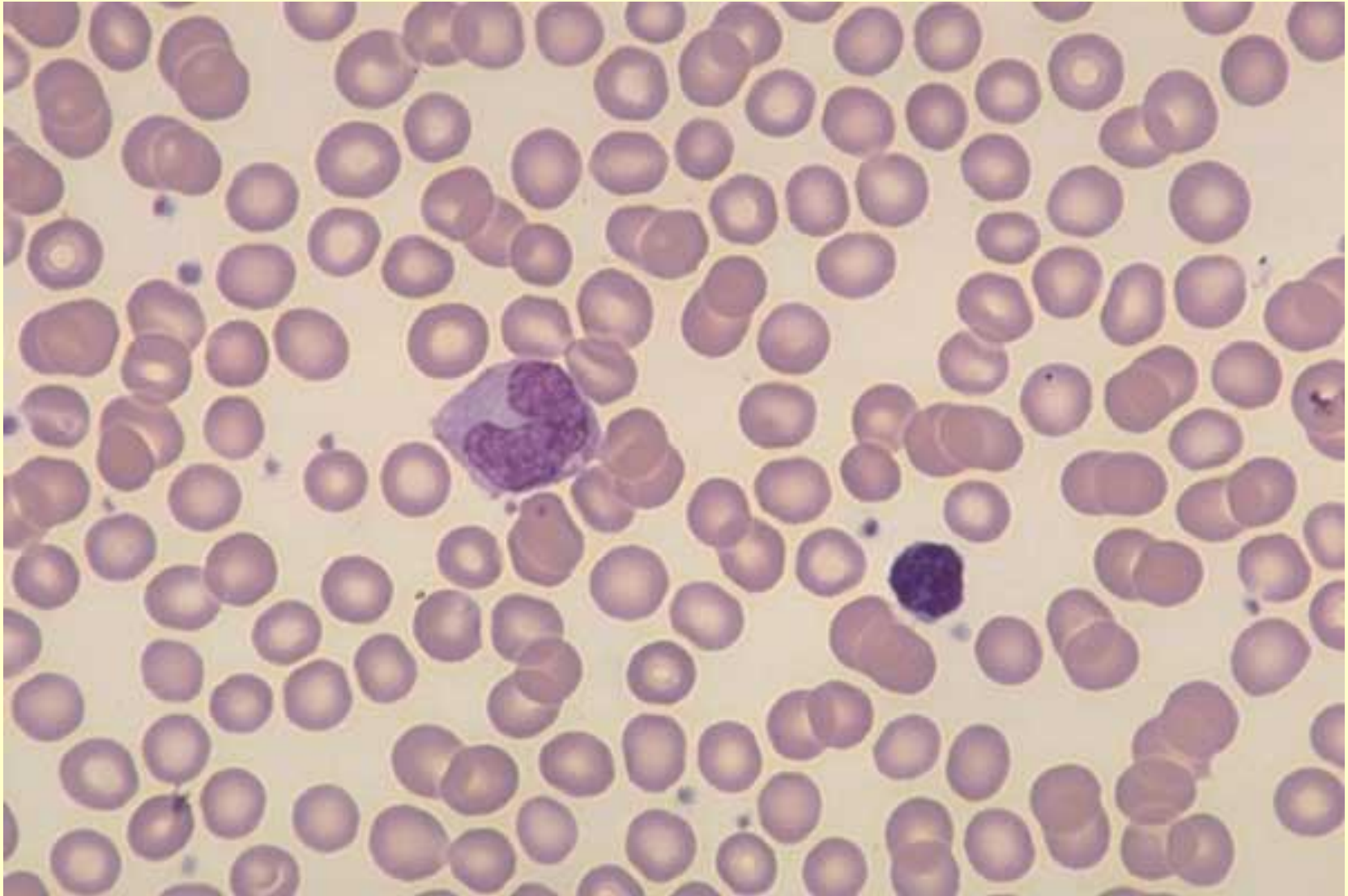


Osteoclast

One osteoclast with 12 nuclei. Normal marrow -100X

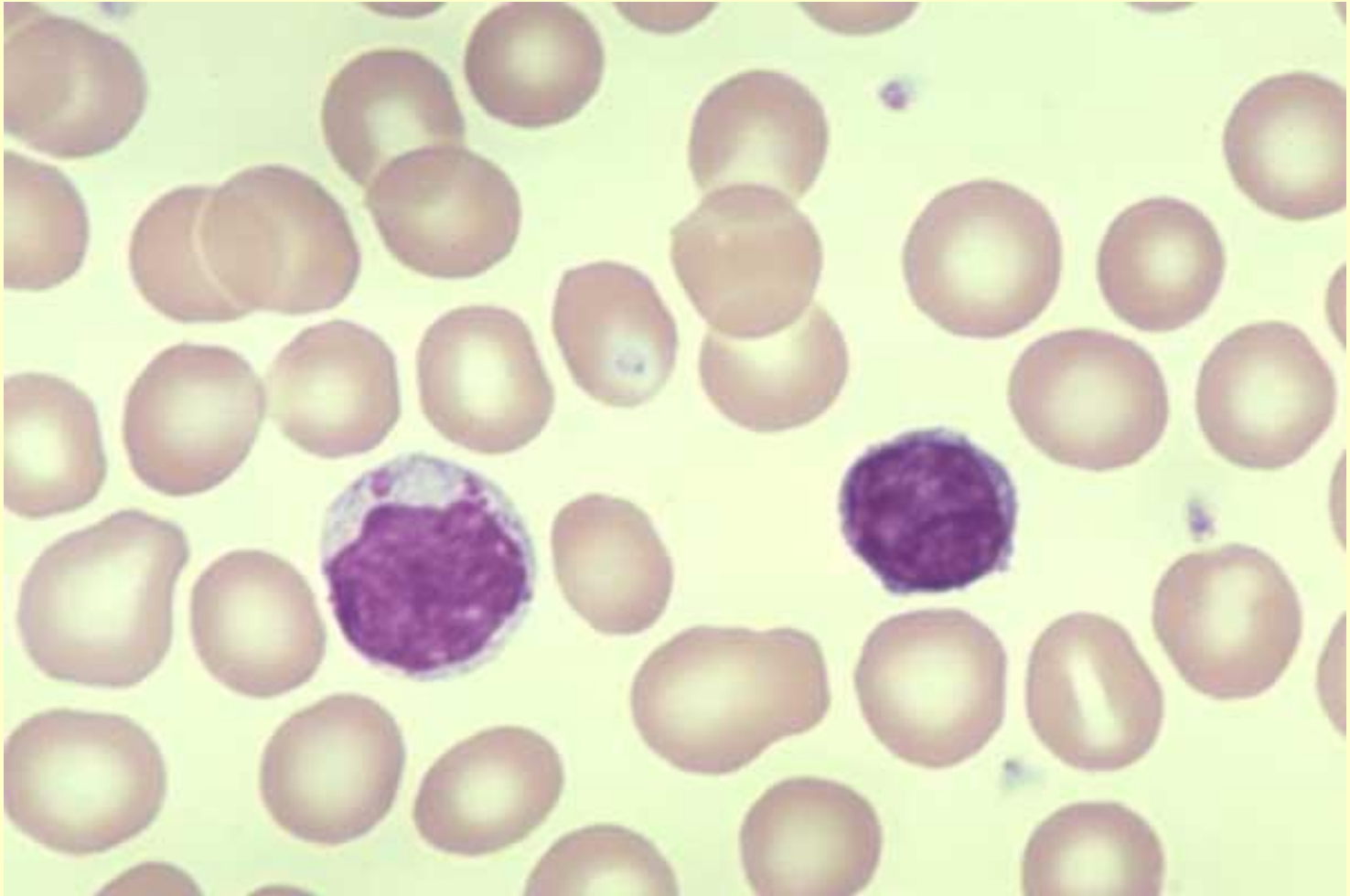


Very small lymphocyte, monocyte, normal blood
One very small lymphocyte, 1 monocyte. Normal blood - 50X



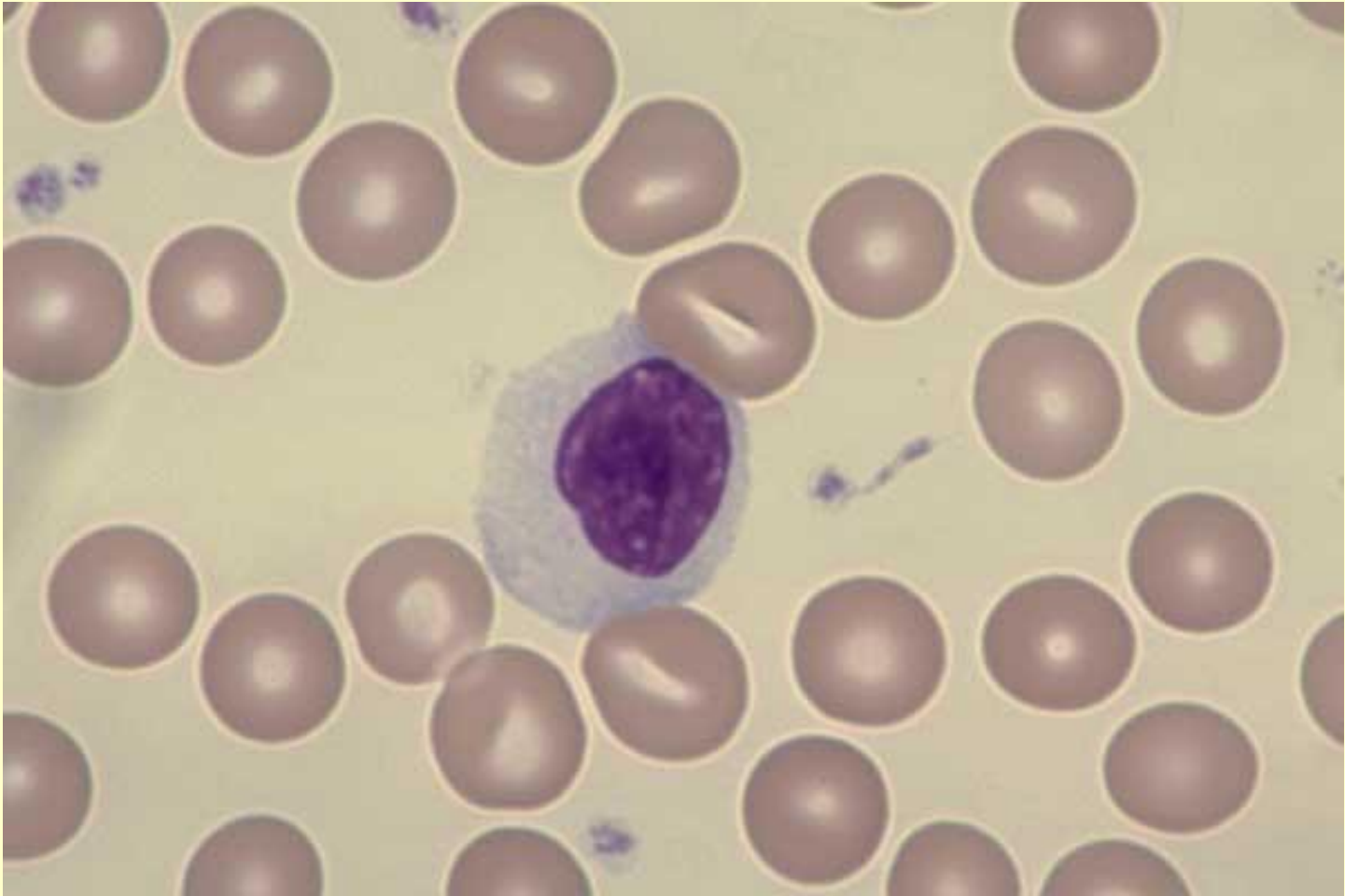
Lymphocytes, normal blood

Two lymphocytes (1 with granules); Normal blood - 100X



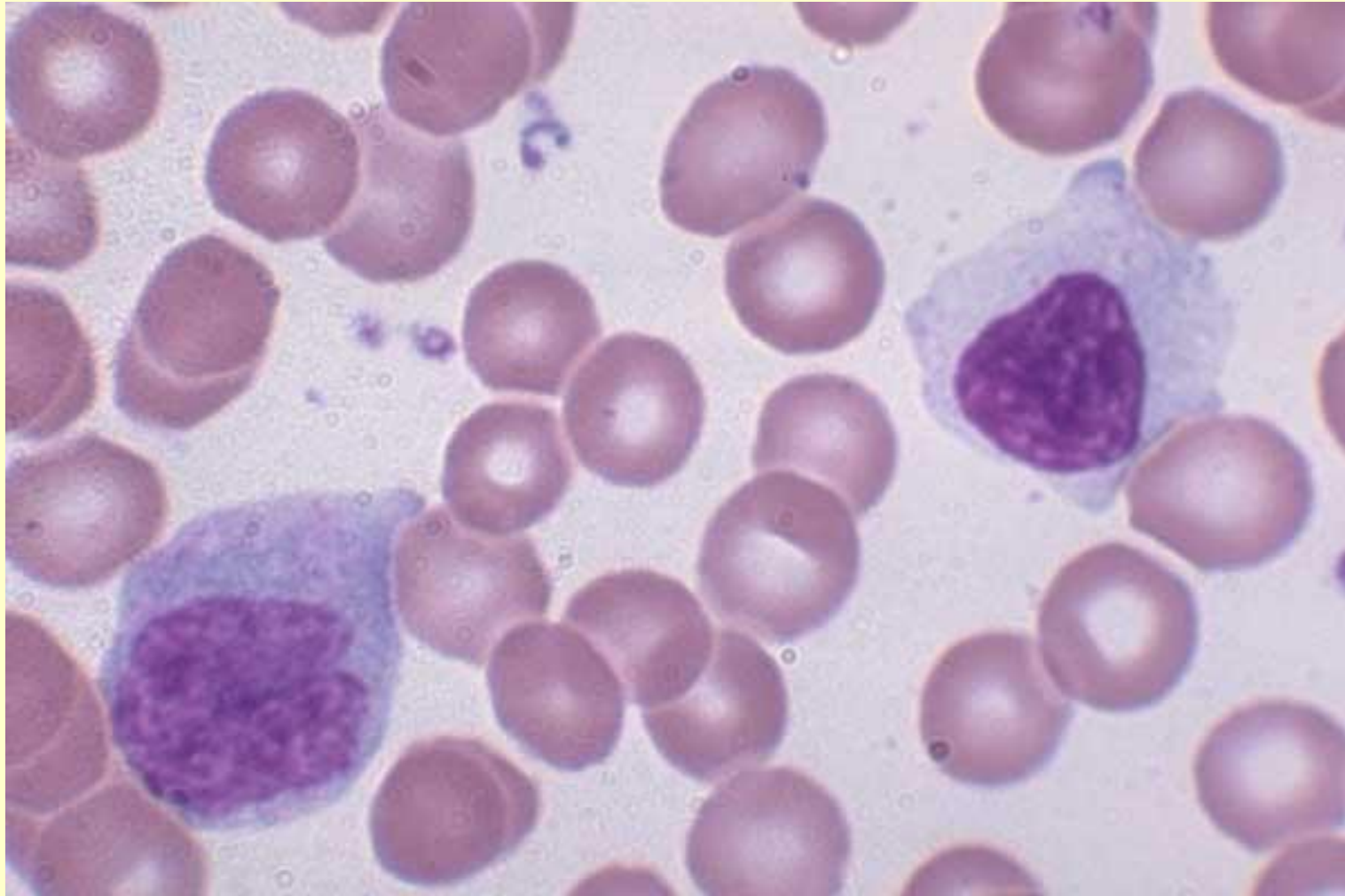Large reactive lymphocyte, normal blood

One very large lymphocyte (reactive); Normal blood - 100X

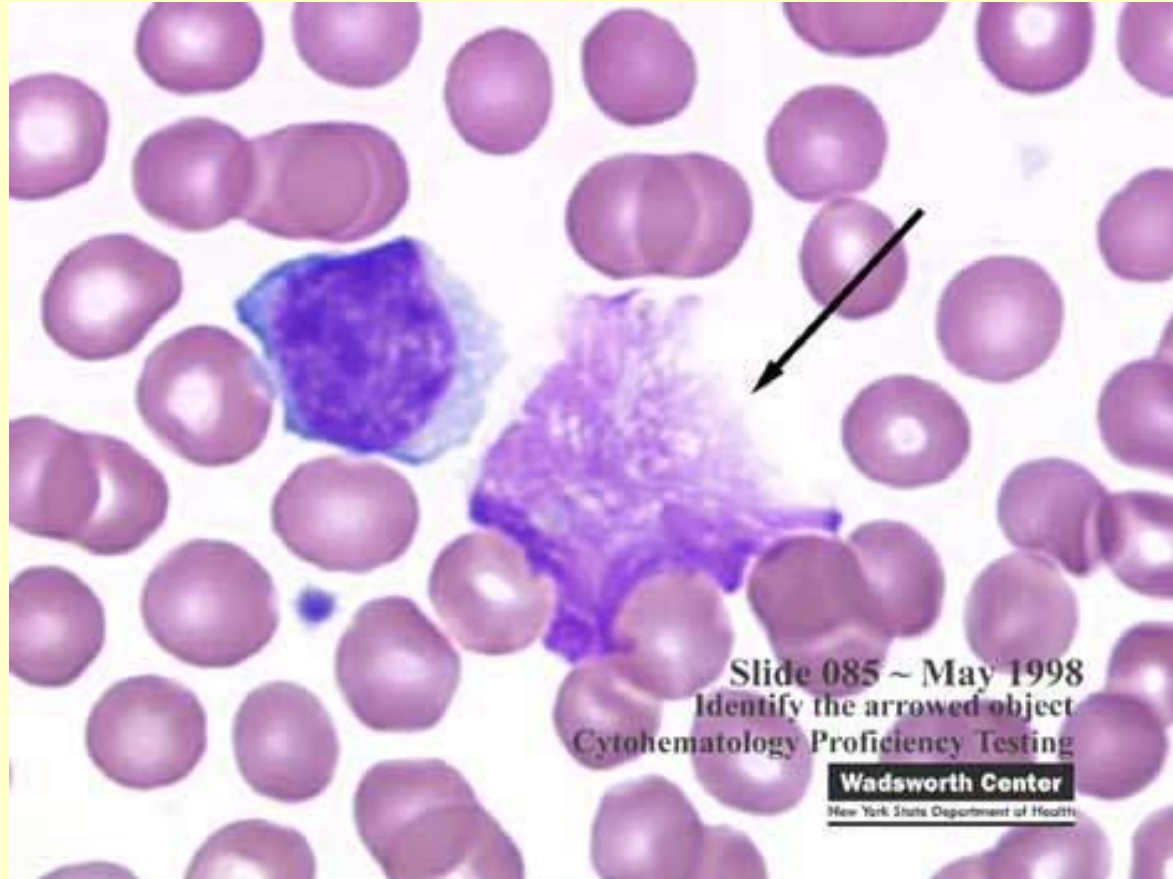


Monocyte, large lymphocyte, normal blood

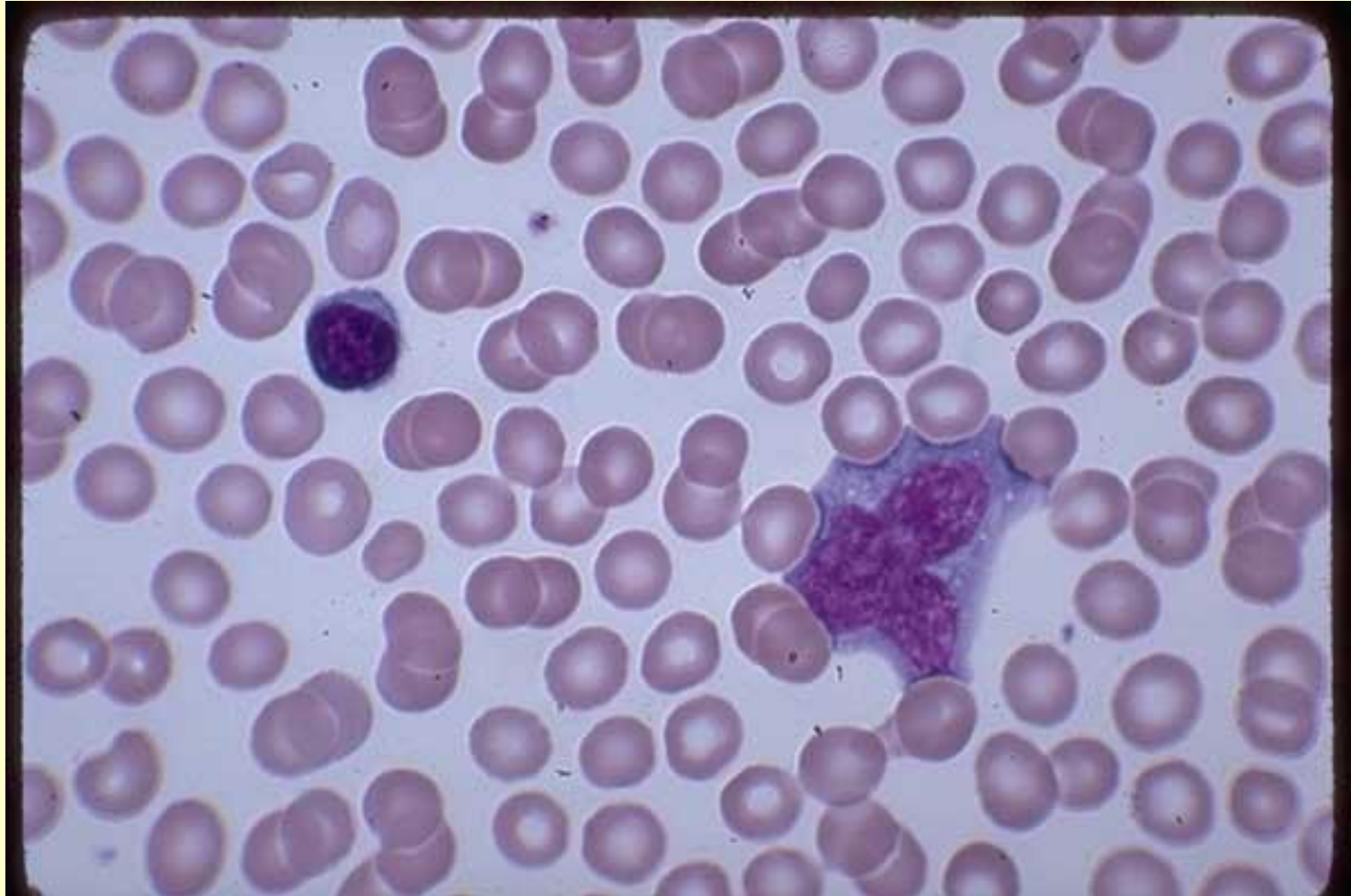
One monocyte (left), 1 large lymphocyte. Normal blood -
100X



КЛЕТКИ ЛЕЙКОЛИЗА



Plasmacytoid lymphoid, infectious mononucleosis blood
One small mature lymphocyte, 1 Plasmacytoid Lymphoid with a contorted nucleus. Infectious mononucleosis blood - 100X

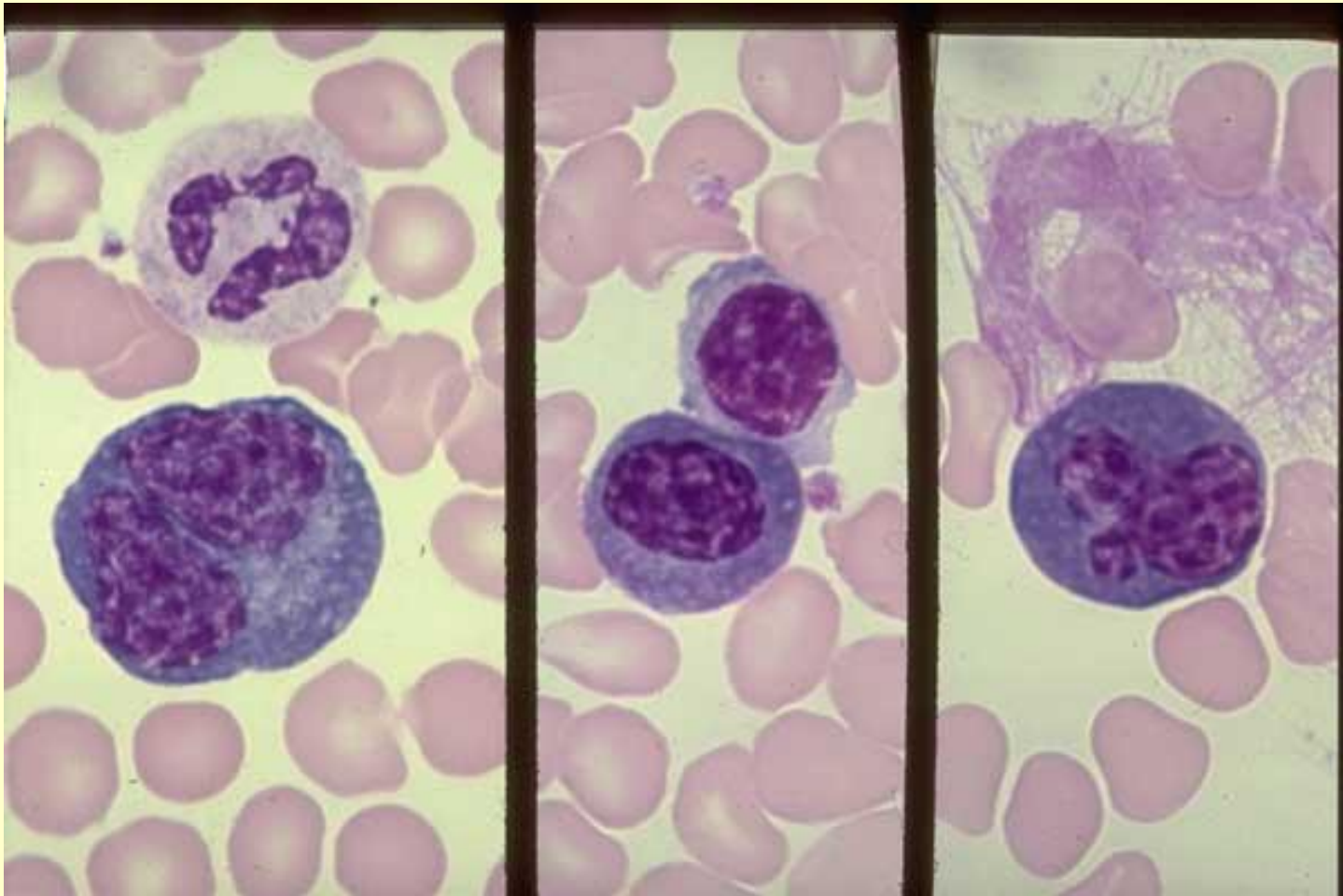


Plasmacytoid lymphocyte, severe arthritis with osteoporosis

Left frame: 1 Plasmacytoid Lymphocyte with a double nucleus, 1 mature neutrophil.

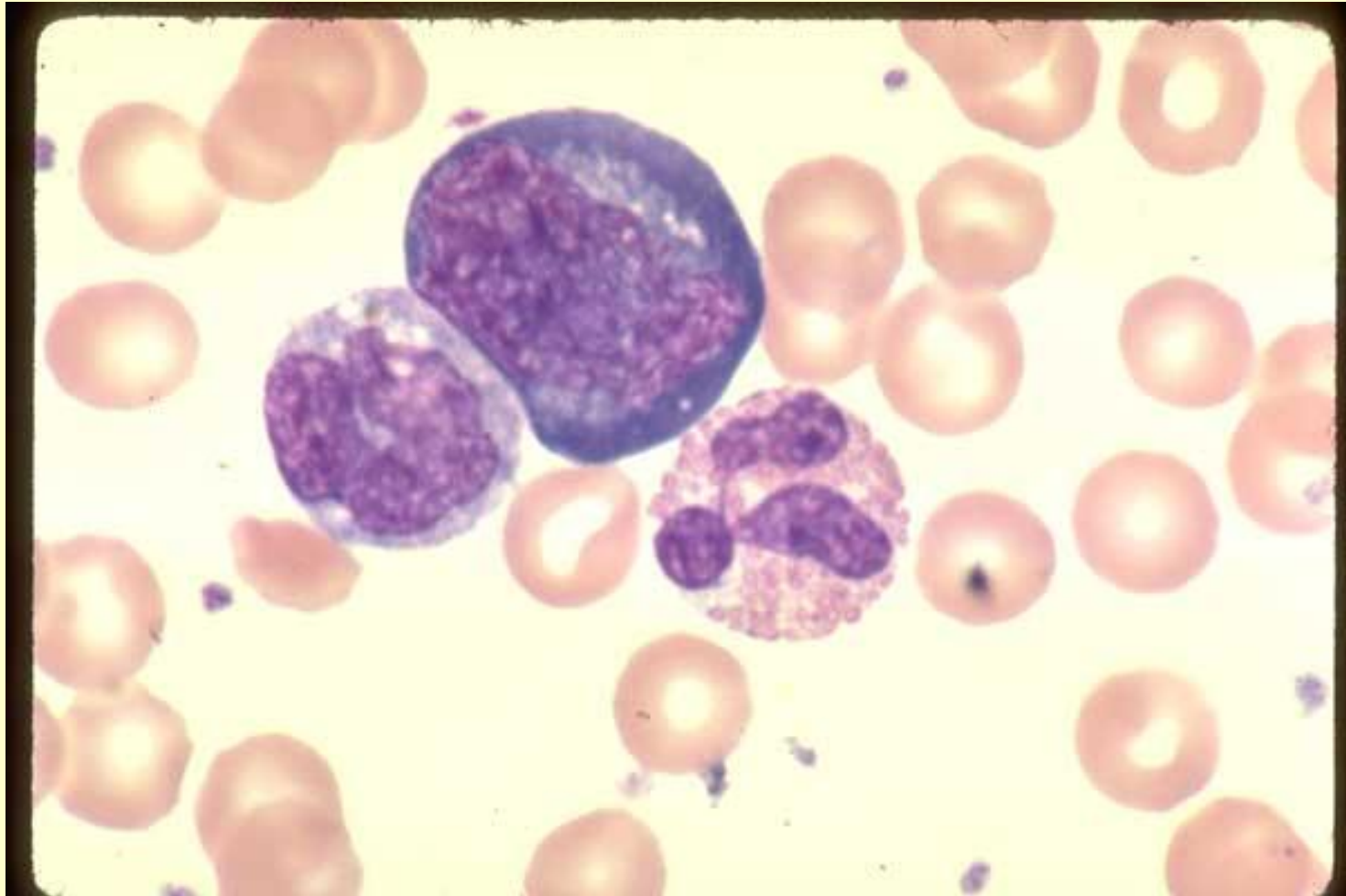
Center frame: 1 mature lymphocyte and 1 small Plasmacytoid Lymphocyte.

Right frame: 1 Plasmacytoid Lymphocyte with a contorted nucleus and 1 late smudged form.



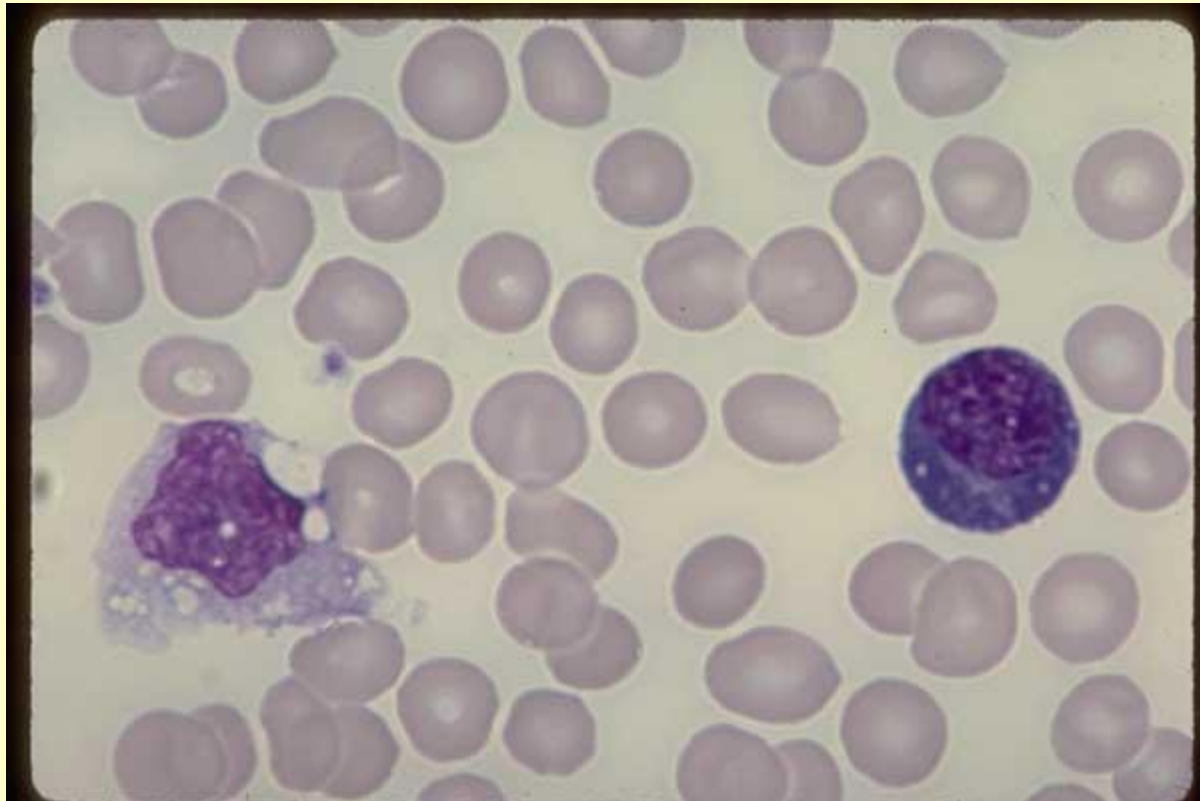
Monocyte, Plasmacytoid Lymphocyte, drug reaction buffy coat

One monocyte, 1 Plasmacytoid Lymphocyte and 1 eosinophil. Drug reaction buffy coat preparation - 100X



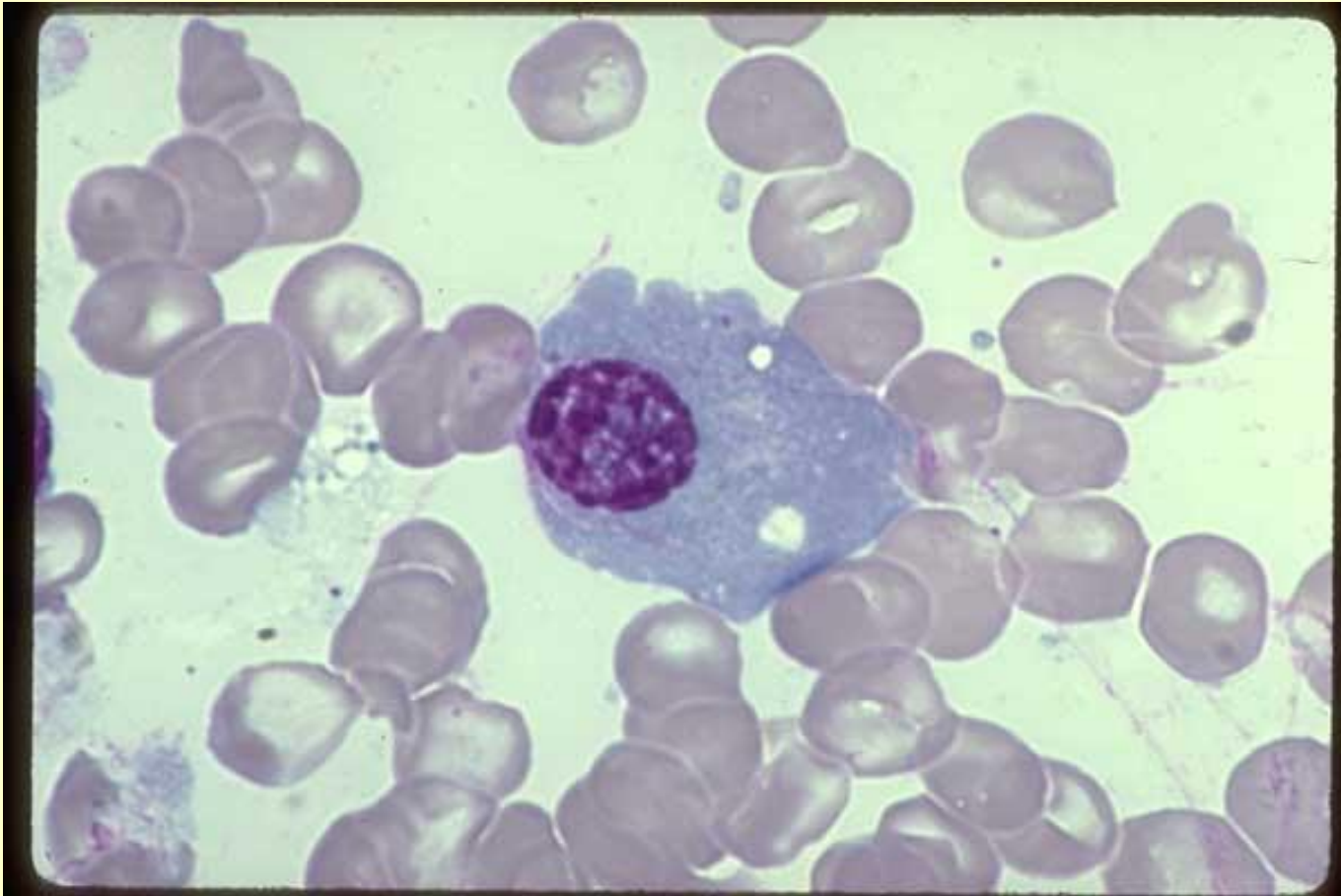
Plasma cell, alcoholic, liver disease

One monocyte at left edge and one Plasma Cell at right edge. The plasma cell is medium in size, has an eccentrically located nucleus which shows a dense chromatin with a few randomly located open areas. The abundant cytoplasm is very basophilic blue, contains a few vacuoles and shows an almost colorless area (Golgi) adjacent to the nucleus. Alcoholic with liver disease blood - 100X

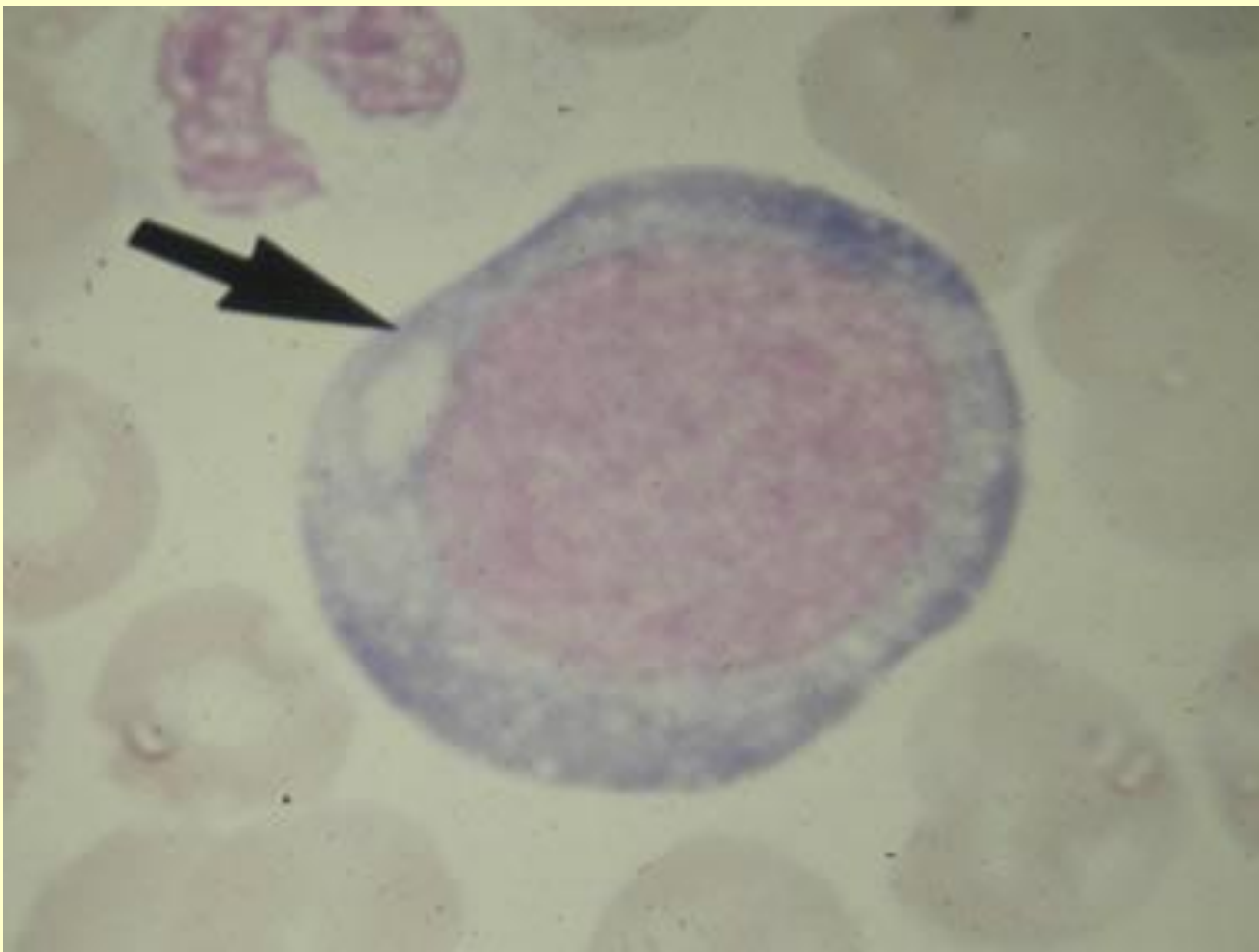


Plasma Cell

One large Plasma Cell, oval in shape, with an eccentrically located nucleus, a very low nuclear/cytoplasm ratio, a gray-blue cytoplasm containing several vacuoles of variable size. The nuclear chromatin is dense with several clear areas randomly distributed. Normal marrow - 100X

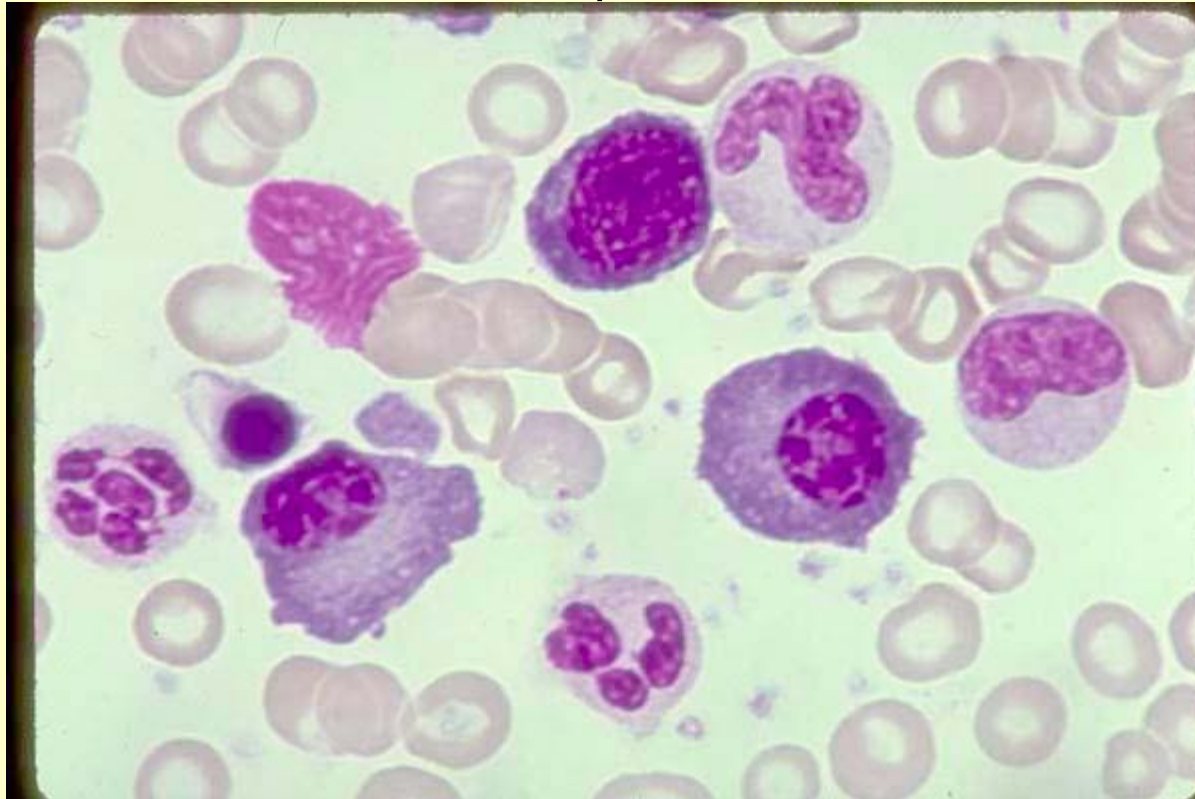


ЭРИТРОБЛАСТ



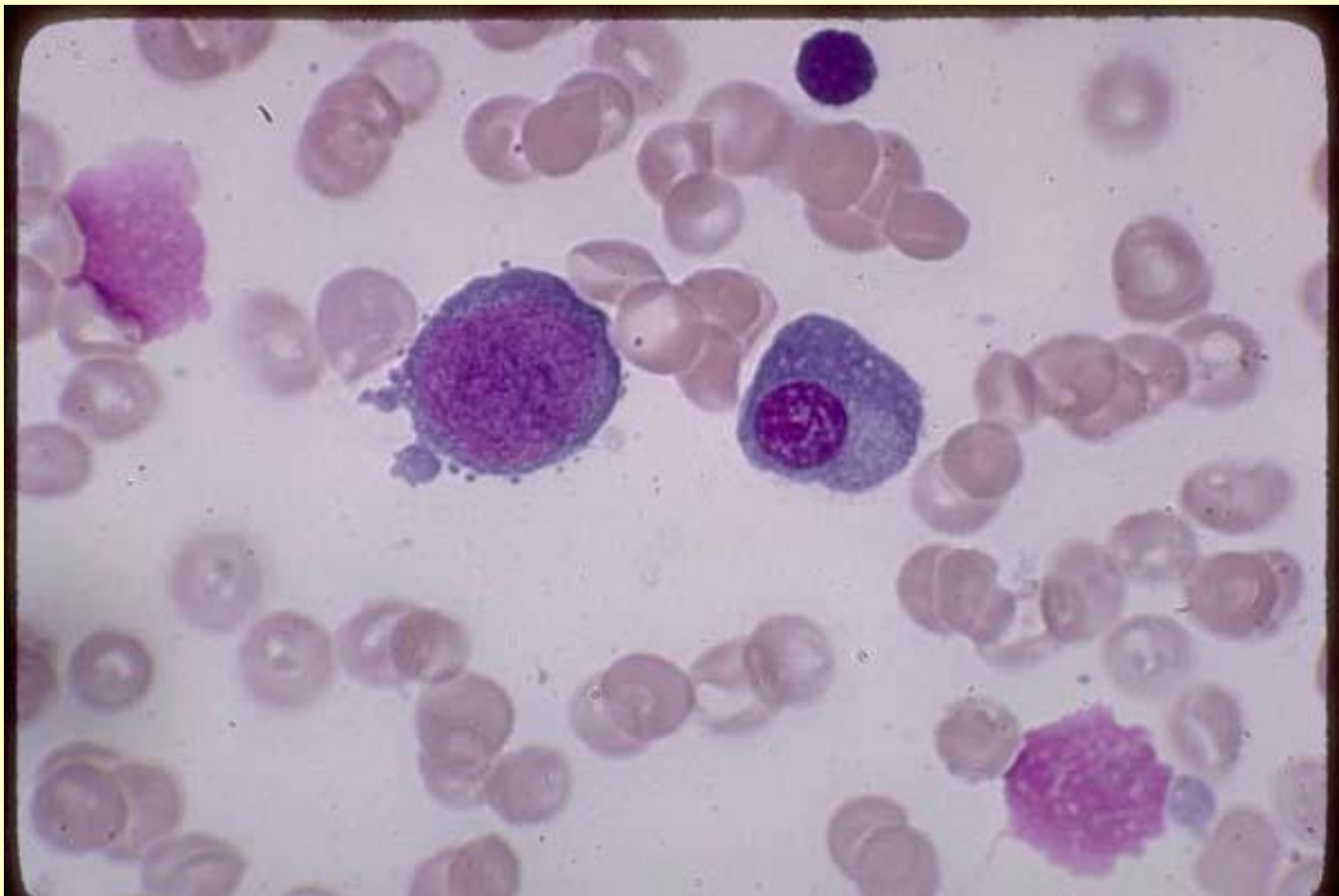
Two Plasma Cells with low nuclear/cytoplasmic ratio, deep basophilic

blue cytoplasm, distinct clear area adjacent to the nucleus and eccentrically located nucleus. At the center top edge is a Proerythroblast with a high nuclear/cytoplasmic ratio but deep basophilic blue cytoplasm and dense nuclear chromatin similar to the plasma cells. Its clear area (Golgi) adjacent to the nucleus is not as pronounced as in the plasma cells. 1 late NRBC is at left center as well as a 5-lobed mature neutrophil. Normal marrow - 100X

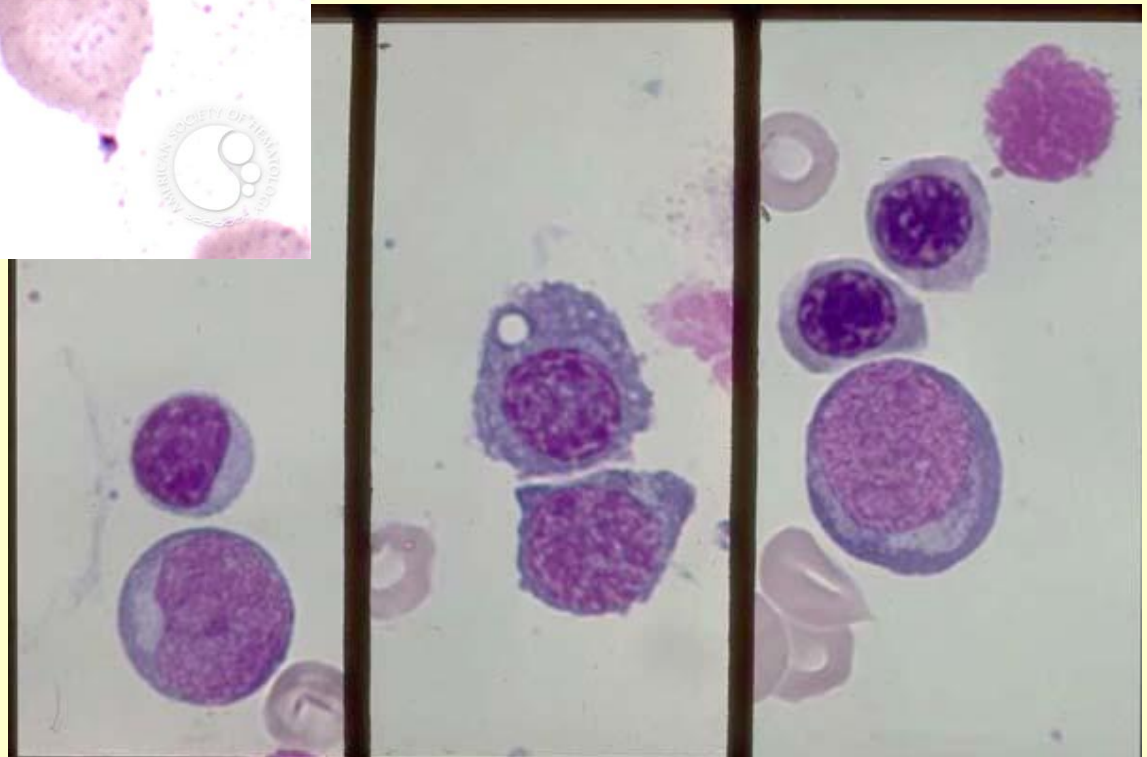
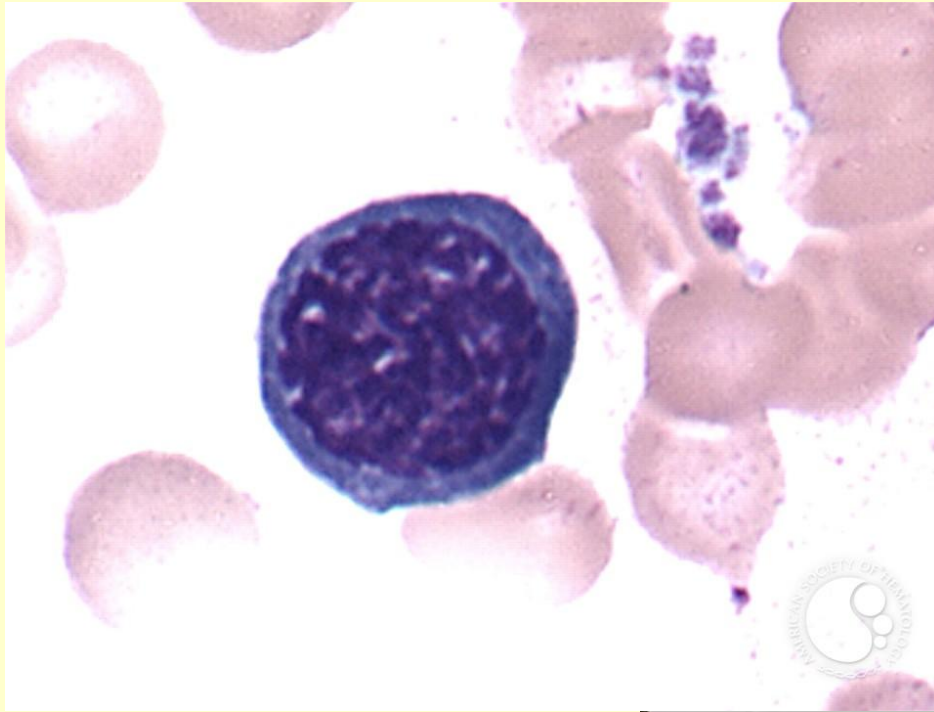


Plasma cell, proerythroblast

One Plasma Cell and 1 Proerythroblast. Early erythroblasts have a deep blue cytoplasm, and a coarse nuclear chromatin similar to plasma cells, but differ in having a high nuclear/cytoplasmic ratio and a centrally located nucleus in a round shaped cell. Also, they usually lack cytoplasmic vacuoles. Normal marrow - 100X



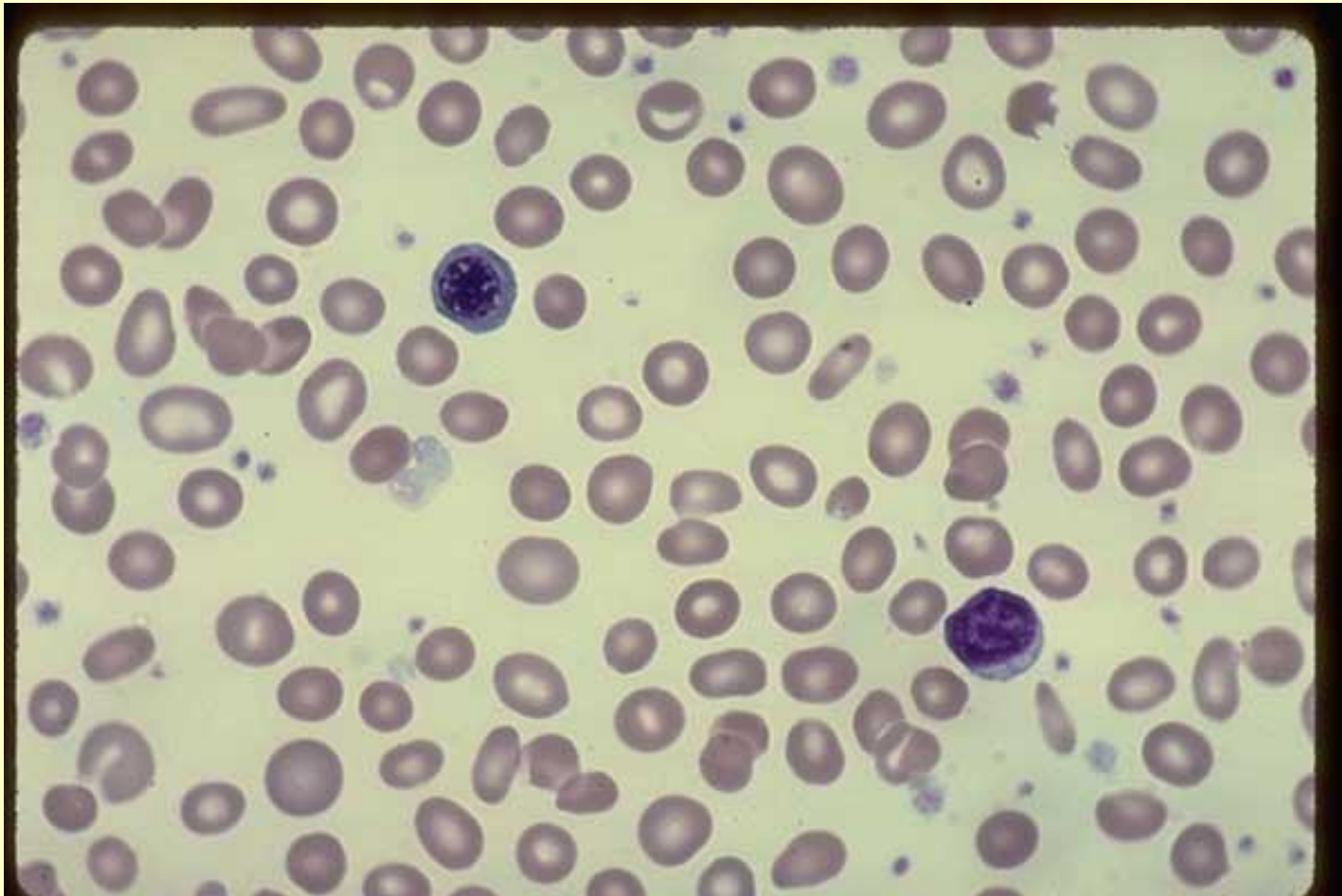
Mature lymphocyte, proerythroblast, basophilic erythroblast



Late NRBC, Mature Lymphocyte, AML

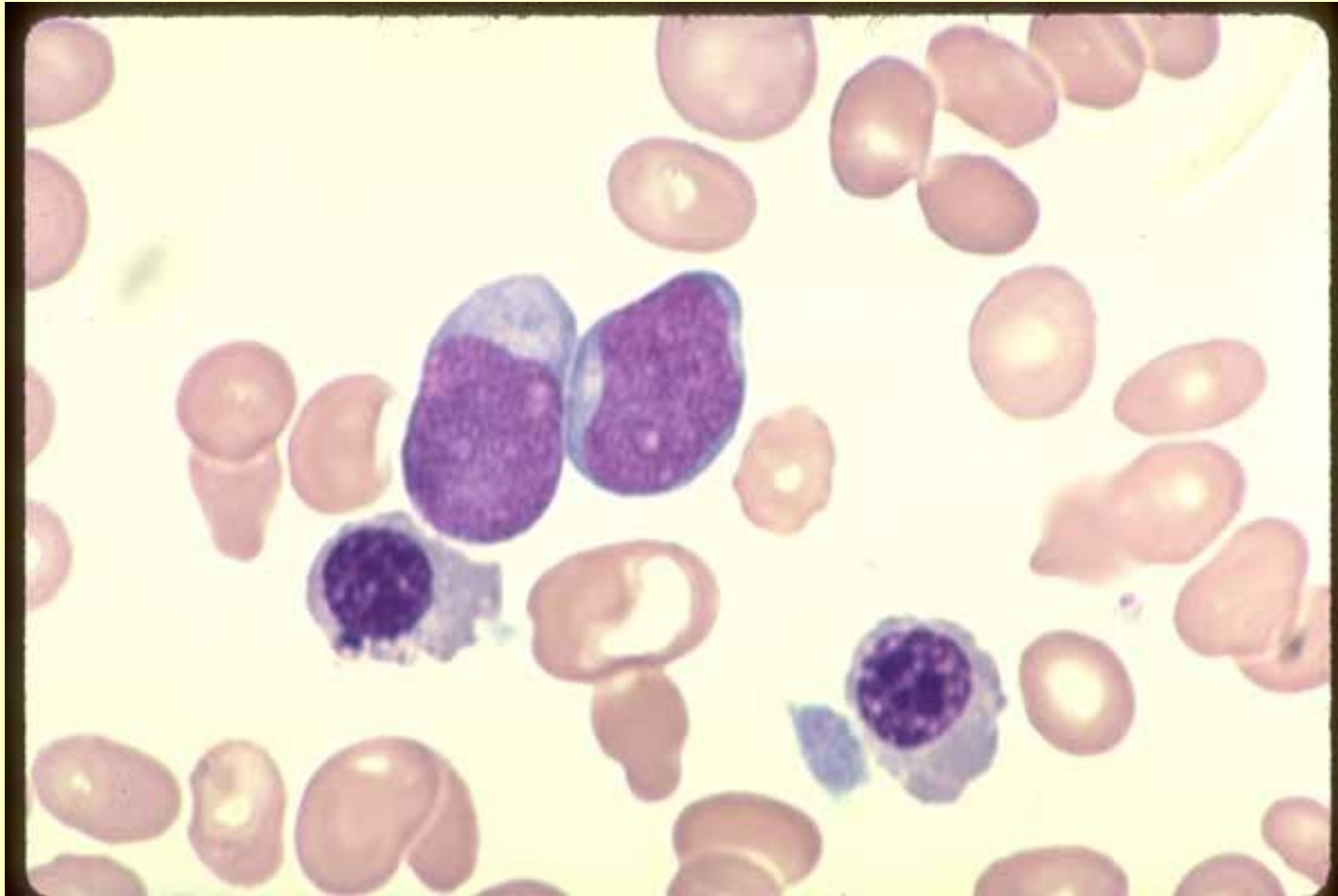
One Late NRBC at upper left and one Mature Lymphocyte at lower right. Many platelets are scattered throughout the field. An Abnormal Megathrombocyte, which is huge, irregular in shape and agranular, is at the left center. Acute Megakaryocytic Leukemia (M-7) untreated. Blood

- 50X



Blasts, polychromatic nrbc, acute megakaryocytic leukemia

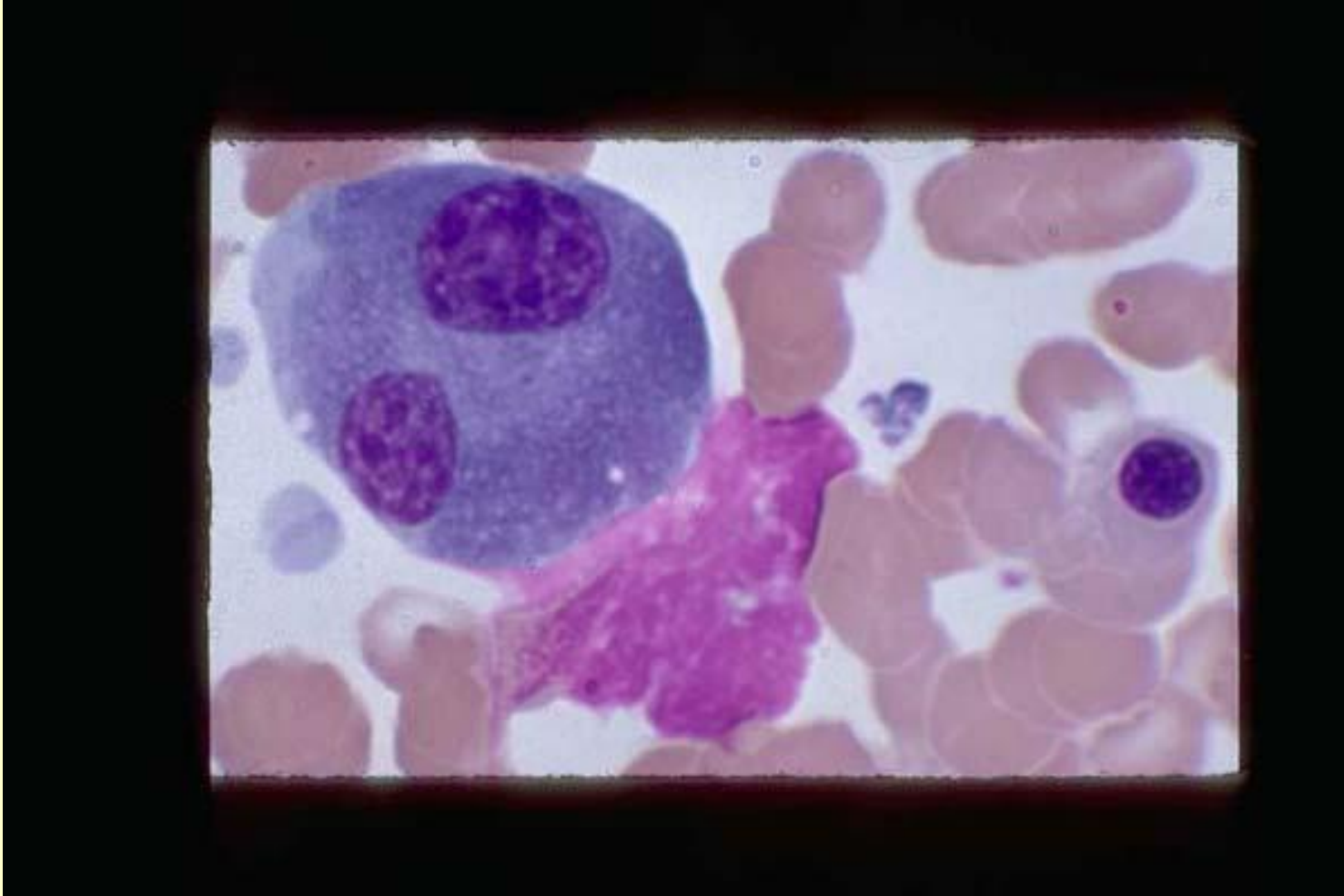
Two Blasts of medium size with fine nuclear chromatin, prominent nucleoli and light blue cytoplasm. Two Polychromatic stage NRBCs. Acute Megakaryocytic Leukemia (M-7). Marrow - 100X



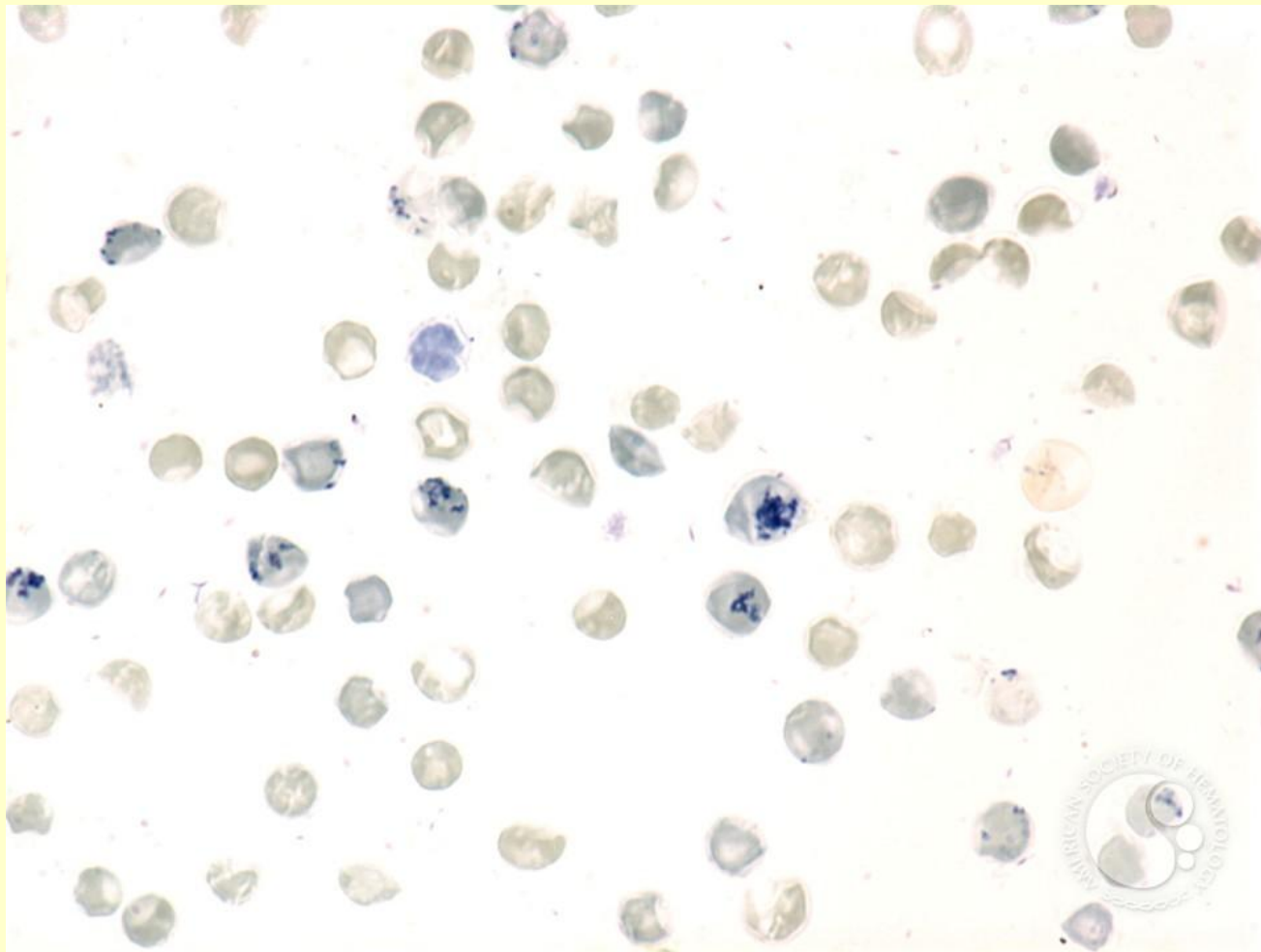
Binucleated Plasma Cell, orthochromatic NRBC

One Binucleated Plasma Cell. Compare its nuclear chromatin, which is typical for a plasma cell, with that in previous image. A smudge nuclear mass and an orthochromatic NRBC are in the field. Normal marrow -

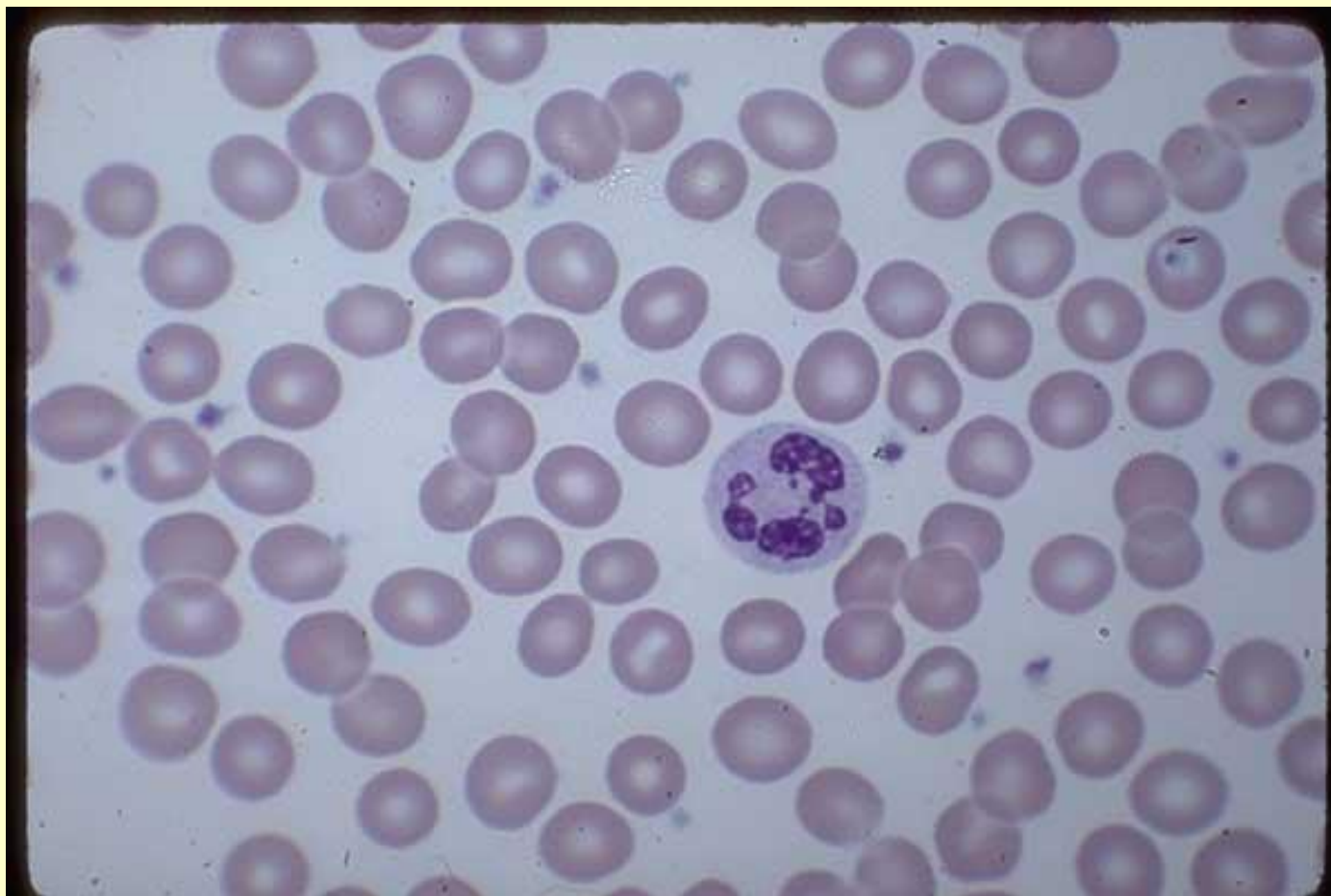100X



РЕТИКУЛОЦИТЫ

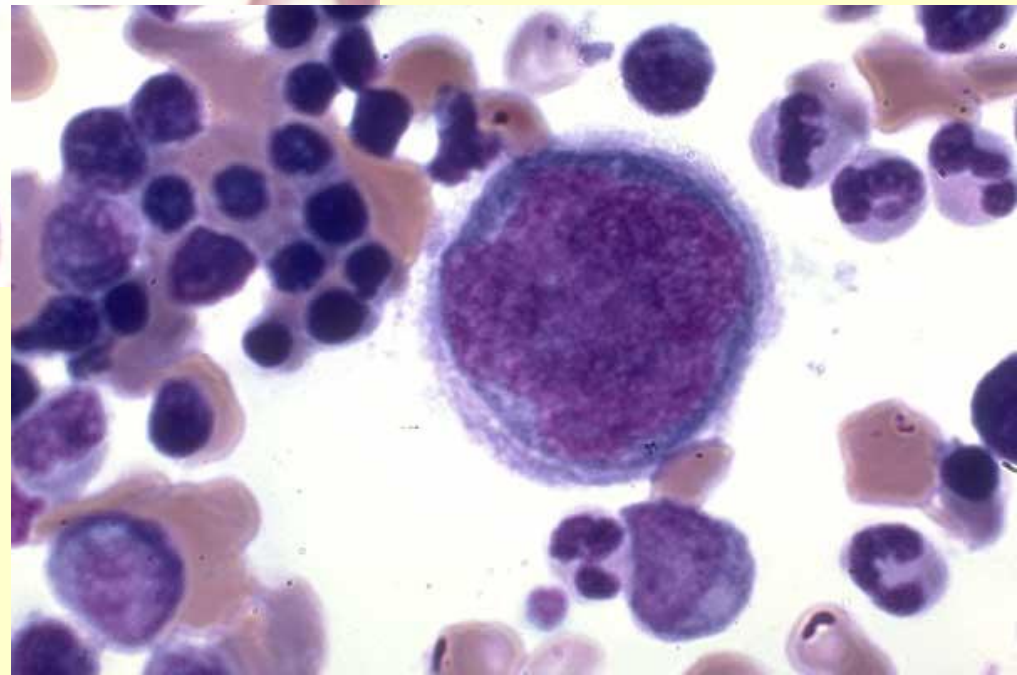
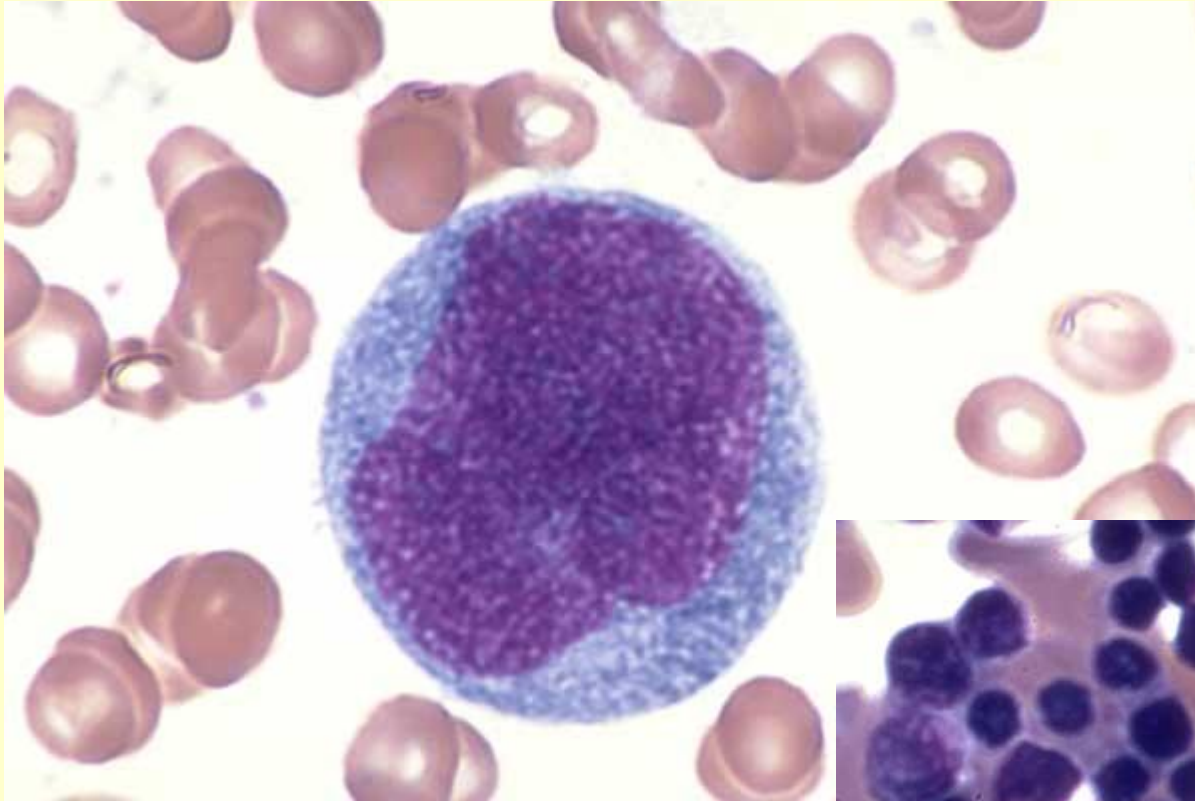


Эритроцит

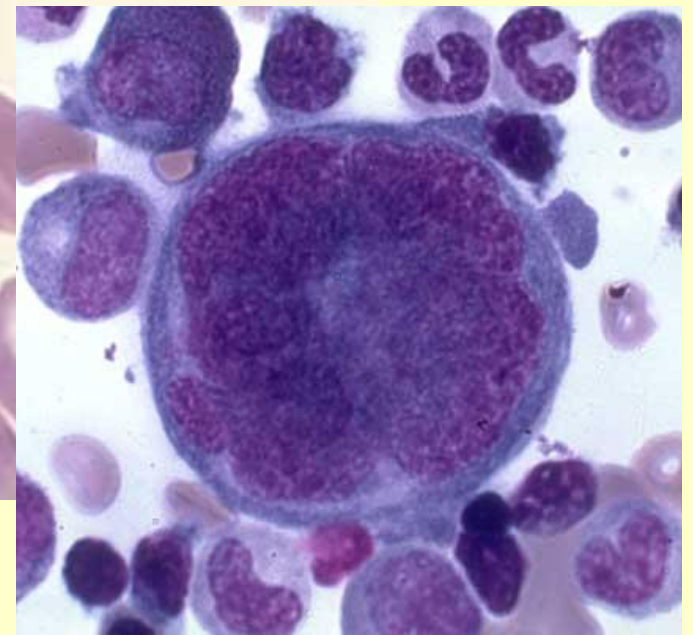
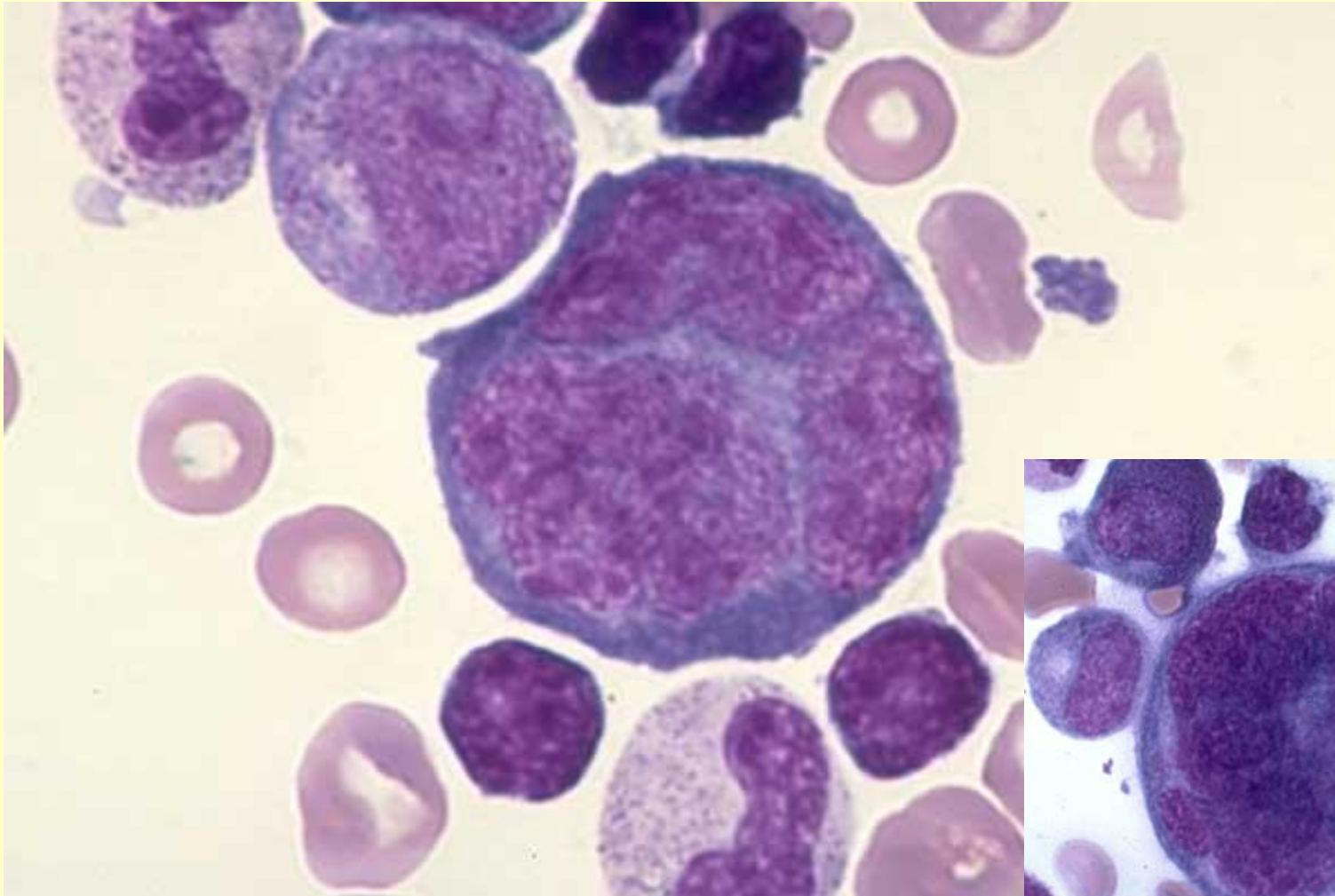


Megakaryoblast , fold in nucleus, normal marrow

One megakaryoblast with an apparent fold in the nucleus. Normal marrow - 100X



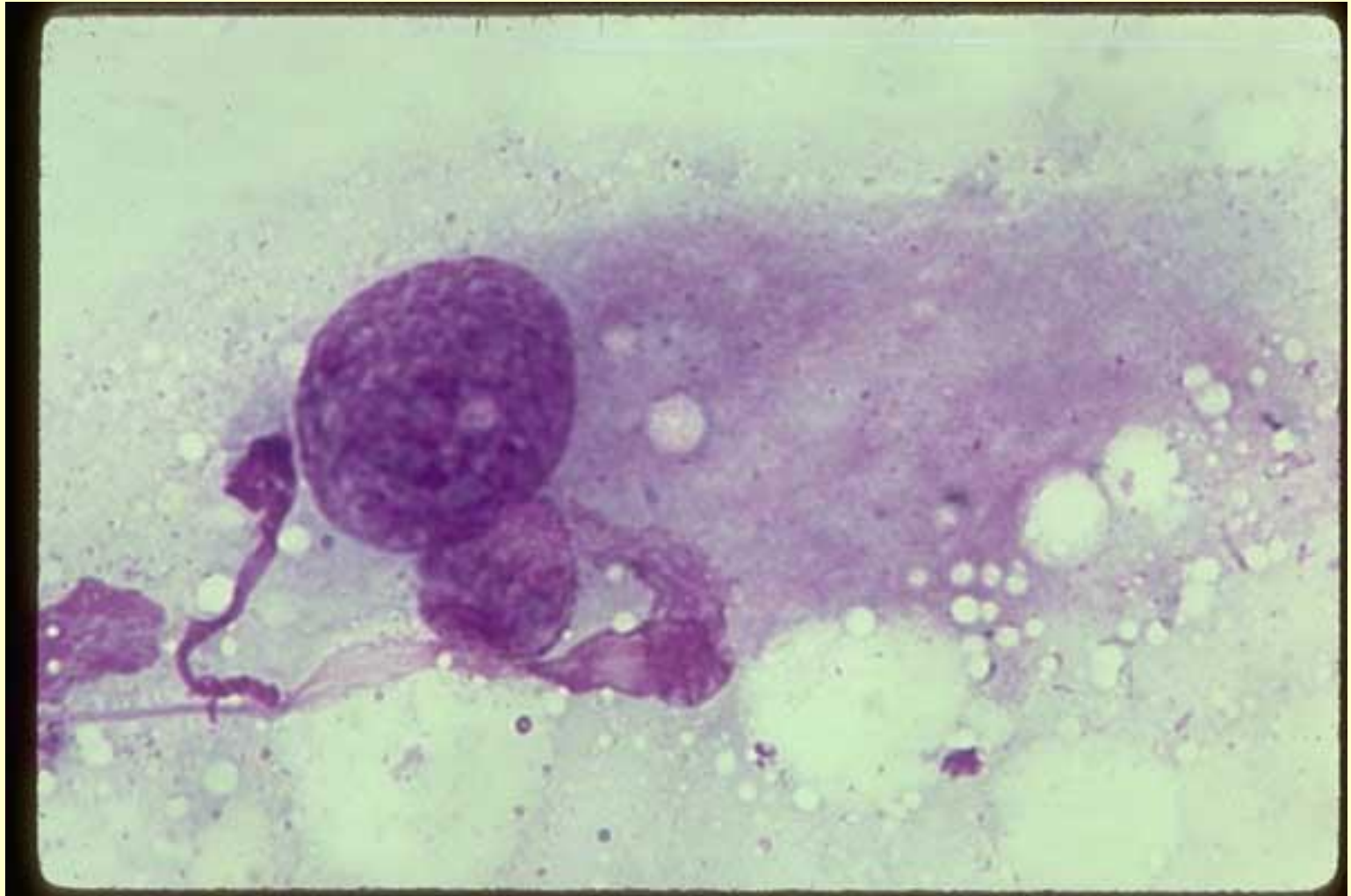
Promegakaryocyte with nuclear separation, normal marrow
One promegakaryocyte with nuclear separation and some nuclear lobulation. Normal marrow - 100X



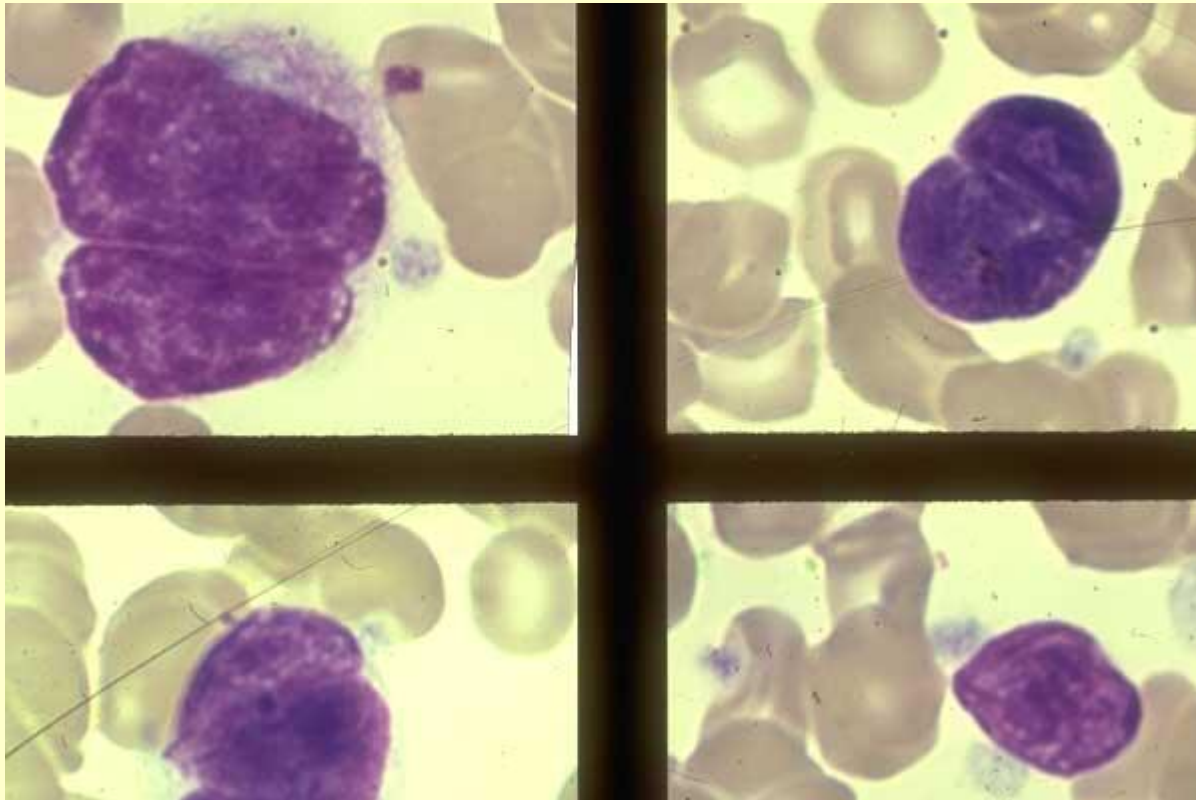
Abnormal megakaryocyte, Wright's-Giemsa stain, AML marrow

Mature Abnormal Megakaryocyte with two apparent nuclei; one is very large. Wright's-Giemsa stain. Acute Megakaryocytic Leukemia (M-7).

Imprint of marrow biopsy - 100X



- **Megakaryocyte and bare nuclei, megakaryocytic leukemia**
- Top left frame: Small mature megakaryocyte with lobulated nuclei and scant cytoplasm. Top right frame: Bare lobulated megakaryocyte nuclei. Lower left frame: Bare lobulated megakaryocyte nuclei. Lower right frame: Bare single megakaryocyte nucleus with a couple of cytoplasmic wisps still attached. Megakaryocytic leukemia (M-7) blood - 100X



Normal Platelets , Proper Thickness, Field to Examine

Normal Platelets scattered throughout the field. There are slightly fewer than in the previous fields, but within normal numbers. This is a Proper Thickness of a Field to Examine, where the red cells are just touching each other or barely overlapping. Count the number of platelets in at least 10 similar fields and figure the average number per field to derive a platelet estimate. The Red Cells are Normocytic, Normochromic. The white cell is a Normal Mature Neutrophil.

Normal blood - 100X.

