

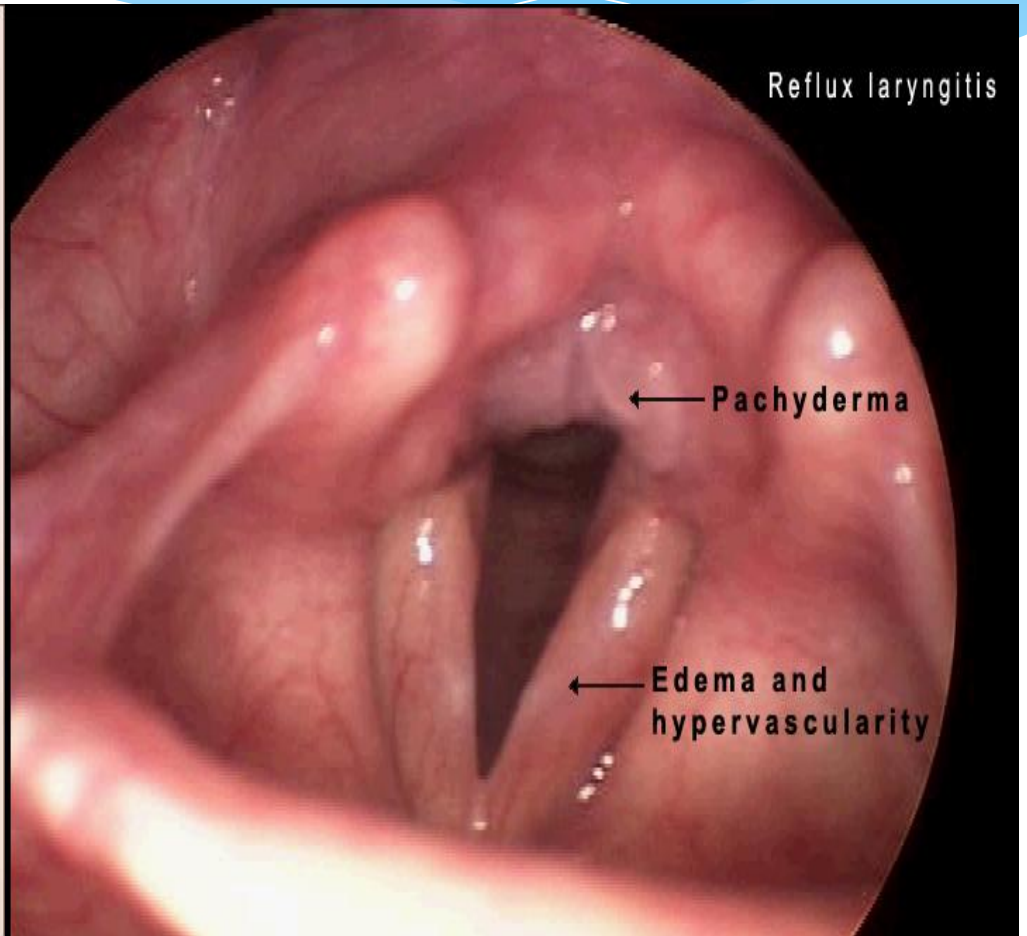
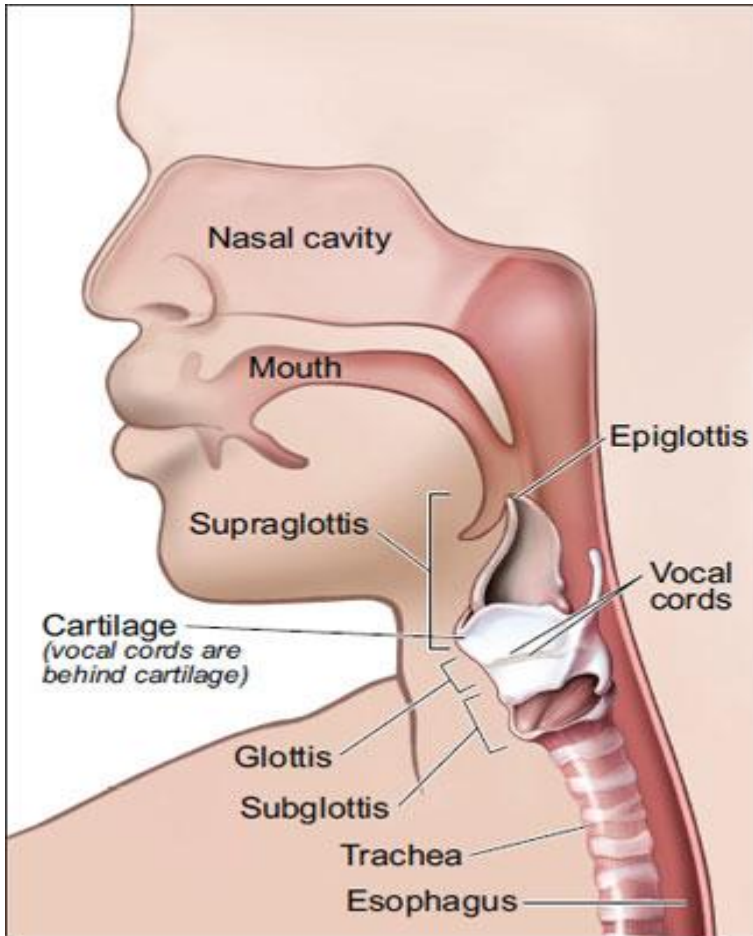
JSC “Astana medical University”

Theme: **Laryngeal edema and stenosis.**

Done by: Duisenova A.
407GM

Laryngeal edema

- * Laryngeal edema is a common cause of airway obstruction in the recently extubated intensive care unit (ICU) patient. Depending upon the severity of edema, patients may go on to develop “a high pitched noisy respiration” known as “stridor”
- * (1). Stridor has been documented to occur in 3.5-36.8% of the ICU population, depending on the definition used
- * (2). Stridor not only leads to anxiety for the patient and family, but may progress to acute respiratory failure requiring reintubation and resulting in increased mechanical ventilation days, ICU days, patient care costs, morbidity, and mortality.



Etiology

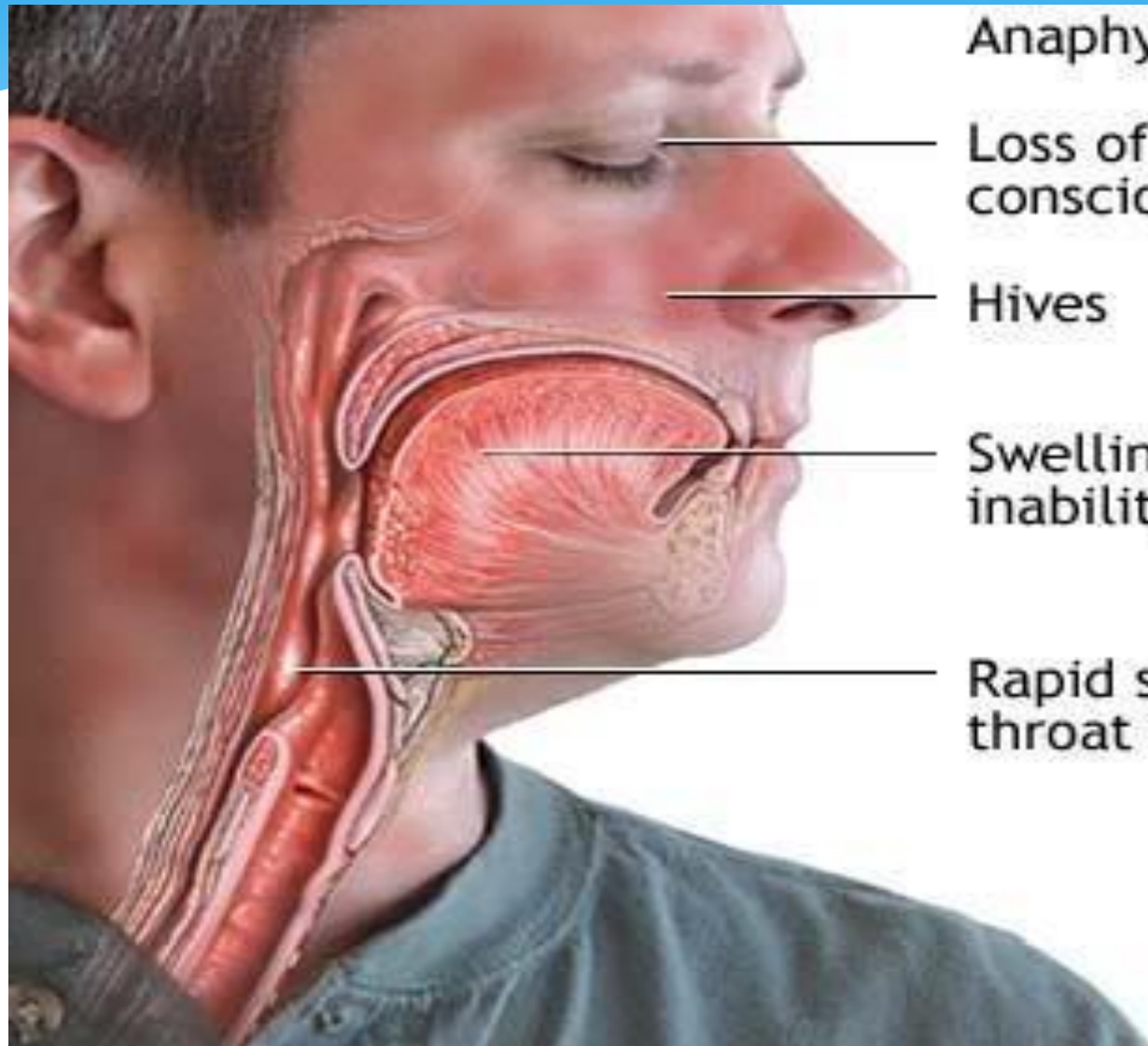
- * Infections:
epiglottitis, laryngo trachea bronchitis, tuberculosis or syphilis of larynx
- * Infections in neighbourhood
peritonsillar abscess, retropharyngeal abscess, Ludwig's angina
- * Trauma
surgery of tongue, laryngeal trauma, endoscopy, inhalation, irritant gases, thermal, chemical burns, intubation
 - Neoplasm Cancer of larynx or laryngopharynx
often associated with deep ulceration
- * Allergy
angioneurotic edema, anaphylaxis
- * Radiation: For cancer of larynx or pharynx.
- * Systemic disease : Nephritis, heart failure, or myxoedema.

Symptoms and signs

- * Airway obstruction
- * Inspiratory stridor

Diagnostics

- * Indirect laryngoscopy shows oedema of supraglottic or subglottic region. Children may require direct laryngoscopy.



Anaphylaxis

Loss of
consciousness

Hives

Swelling of tongue,
inability to swallow

Rapid swelling of
throat tissues

Management

- * Intubation/ tracheostomy
- * Steroids (thermal, chemical)
- * Adrenaline (1:1000) i/m 0,3-0,5ml repeated every 15 minutes

Steroids are useful in epiglottitis, laryngo- tracheo-bronchitis or oedema due to traumatic allergic or post-radiation causes.

Management

- * Level 1: Steroid therapy decreases post-extubation stridor and need for reintubation in patients at increased risk for extubation failure due to airway edema. Steroid therapy should be administered >6 hours prior to extubation to be effective in reducing airway edema.
- * Level 2: Patients at risk for laryngeal edema include: Traumatic intubation Female gender Prolonged intubation (>7 days) Traumatic injury Oversized endotracheal tubes Self extubation Failed cuff leak test The cuff leak test is an adequate test to assess for laryngeal edema.
- * Level 3: A leak of greater than 30% of the administered tidal volume upon deflation of the endotracheal tube cuff is suggestive of successful extubation. When steroids are administered to decrease post-extubation stridor, dexamethasone 4 mg IV q 6 hrs should be utilized.

Laryngeal stenosis

- * Laryngeal stenosis is a congenital or acquired narrowing of the airway that may affect the supraglottis, glottis, and/or subglottis. It can be defined as a partial or circumferential narrowing of the endolaryngeal airway and may be congenital or acquired. The subglottis is the most common site of involvement.

ETIOLOGY

1. Trauma:

- * External
 - * blunt
 - * penetrating
- * Internal
 - * intubation
 - * post tracheostomy
 - * post surgery
 - * post radiotherapy
 - * thermal/ chemical burns

ETIOLOGY

2. Chronic inflammatory disease

- * tuberculosis/ leprosy
- * sarcoidosis
- * scleroma
- * histoplasmosis
- * diphtheria
- * syphilis

3. Benign disorders

- * intrinsic
 - * papilloma/chondroma
 - * minor salivary gland / nerve sheath tumor
- * extrinsic
 - * Thyroid/ thymic tumors

ETIOLOGY

4. Malignant disorders

- * Intrinsic
 - * SCC/ minor salivary gland tumor
 - * sarcoma/ lymphomas
- * Extrinsic
 - * Thyroid malignancy

5. Collagen vascular disorders

- * Wegeners granulomatosis
- * Relapsing poly chondritis

PATHOPHYSIOLOGY

Knowledge of pathophysiology is essential that it gives idea regarding time/ frequency of intervention, surgical procedure required and its outcome.

- * **Endotracheal intubation**

- * ischemic necrosis (pressure)

- * mucosal ulcer+ inflammation = fibrosis

- * **others:** duration, composition/ size of tube, laryngeal movement.

- * primary site ; post glottis.

PATHOPHYSIOLOGY

External trauma

- * disruption of cartilagenous framework
- * hematoma/ mucosal disruption
- * hematoma:
 - * cartilage loss
 - * heals by fibrosis
 - * secondary infection
- * **OTHERS:**
 - * DM, CCF, stroke, GERD.
 - * idiopathic- females (estrogen- TGF β).

CLASSIFICATION

* COTTONS system of grading

GRADE	% OF STENOSIS
Grade 1	<50 %
Grade 2	50- 70 %
Grade 3	71- 99 % (minimal lumen)
Grade 4	complete obstruction

CLASSIFICATION

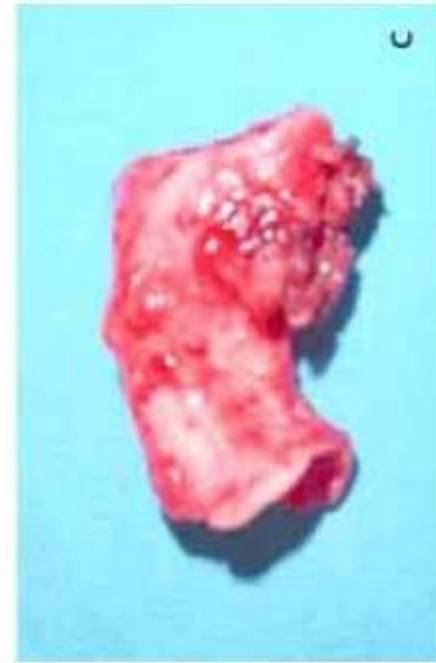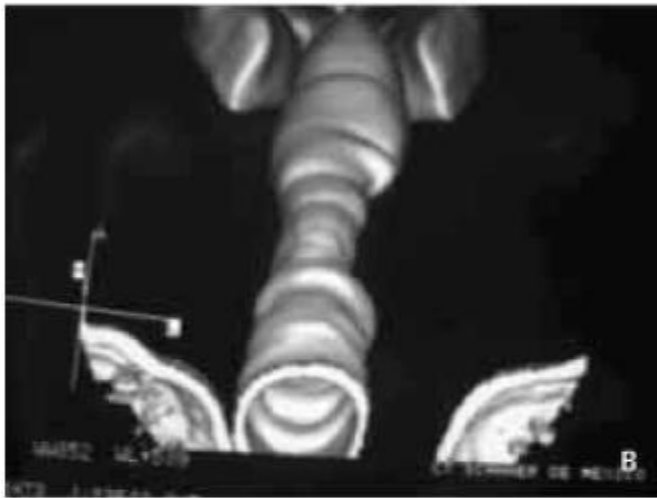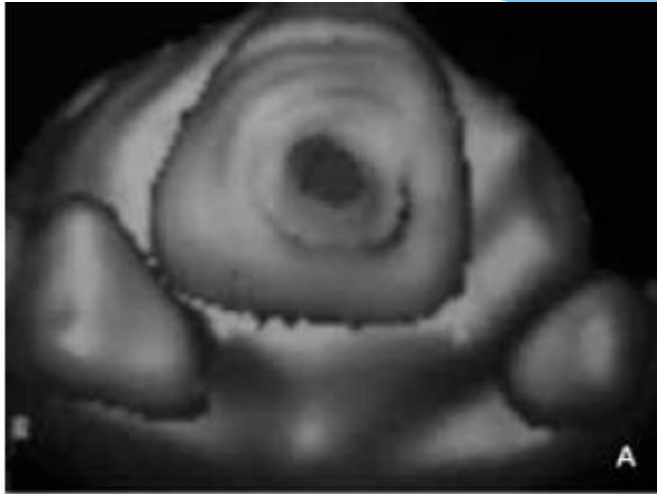
Post glottic stenosis (bogdasarin & olson)

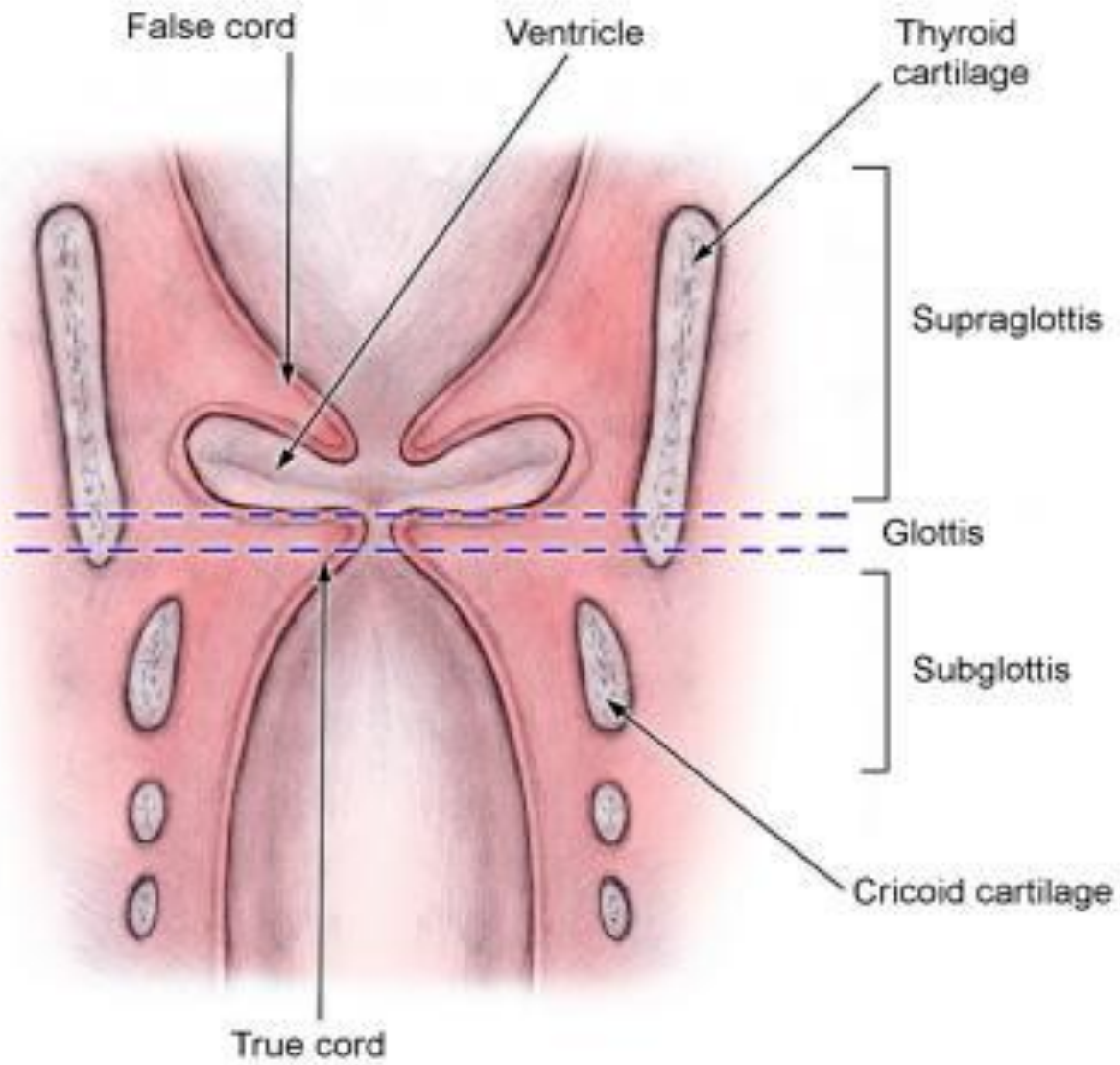
- * TYPE 1 vocal process adhesion
- * TYPE 2 post commissure stenosis with interarytenoid plane scarring.
- * TYPE 3 post commissure stenosis with ankylosis of unilat crico arytenoid joint
- * TYPE 4 post commissure stenosis with bilateral cricoarytenoid joint ankylosis.

CLASSIFICATION

Mc Caffery (clinical status)


- * GRADE 1-subglottic / tracheal stenosis <1cm long.
- * GRADE 2-subglottic stenosis <1 cm within cricoid ring without glottic / tracheal extension.
- * GRADE 3-subglottic lesion with extn upto upper trachea but no glottic involvement.
- * GRADE 4-glottic involvement with fixation/ paralysis of one/ both vocal folds.





Manifestation

- * Stridor is a common presenting sign in laryngeal obstruction. Supraglottic or glottic obstruction generally presents as inspiratory stridor, while narrowing between the glottis through the trachea is associated with biphasic stridor.
- * Other symptoms include episodes of apnea, suprasternal and subcostal retractions, tachypnea, and dyspnea. Hypoxia can result in cyanosis and anxiety. If the glottis is involved, symptoms of hoarseness or weak husky cry, aphonia, or dysphagia may be noted.

- 
- * The main symptoms of laryngeal stenosis relate to airway, voice, and feeding. Progressive respiratory difficulty is the prime symptom of airway obstruction with biphasic stridor, dyspnea, air hunger, and vigorous efforts of breathing with suprasternal, intercostal, and diaphragmatic retraction. Abnormal cry, aphonia, or hoarseness occurs when the vocal cords are affected. Dysphagia and feeding abnormality with recurrent aspiration and pneumonia can occur.

ASSESSMENT OF LTS

- * History : trauma, mode of onset, effect on airway, voice etc...
- * Indirect/ Direct laryngoscopy, Bronchoscopy, PFT
- * HRCT with 3-D reconstruction, virtual endoscopy
- * Timing of repair: granulomatous/autoimmune disorders require stabilisation of underlying disease process .

Diagnostics

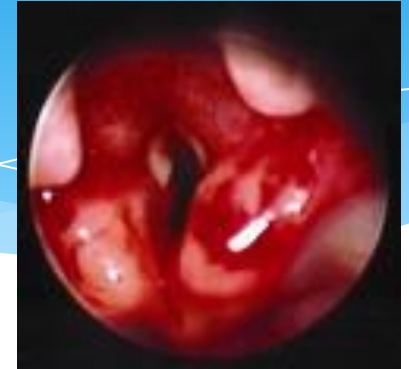- * Radiologic evaluation Radiologic evaluation is performed after stabilization of the airway. Radiography helps assess the exact site and length of the stenotic segment, especially for totally obliterated airways.
- * Endoscopy Indirect laryngoscopy alone is inadequate for diagnosis. Direct endoscopic visualization of the larynx is essential to study the stenosis carefully. Flexible fiberoptic endoscopy assesses the dynamics of vocal cord function and the upper airway, including the trachea (Vauthy and Reddy, 1980). In patients with severe burns with neck contractures, flexible endoscopy may be the only method to visualize the larynx. Flexible retrograde tracheoscopy through the tracheostomy site may add some useful information in some cases.
- * Psychoacoustic evaluation and acoustic analysis of the voice may be used to establish the degree of vocal abnormality before surgery and compare it after surgery (Dedo and Rowe, 1983; Zalzal et al, 1991). Videostrobolaryngoscopy helps in assessment of vocal cord function in adults. 12 Pulmonary function tests with either the spirometric maximum inspiration and expiration flow rates, flow volume loops, or pressure flow loops show characteristic changes in upper airway stenosis and can be used to compare the postoperative results with preoperative values (Brookes and Fairfax, 1982; Grahne et al, 1983; Hallenborh et al, 1982; Zalzal et al, 1990).

New Technology

- * Trans-nasal
“Esophagoscope”
- * Expanded diagnostic endoscopy
 - * Laryngoscopy
 - * Bronchoscopy
 - * Esophagoscopy
- * 2.0 mm Working Channel
 - * Biopsies
 - * Injections
 - * Procedures
 - * TEP



SURGICAL MANAGEMENT



SUPRA GLOTTIC STENOSIS ;

- * injury can be
 - * epiglottis adherent to post / lateral hypopharyngeal wall.
 - * hyoid # - displaced posteriorly with epiglottis = inlet stenosis.
 - * horizontal web of post hypo pharyngeal wall at level of superior aspect of epiglottis.
- * Approach; trans hyoid pharyngotomy.

NAME

AGE 67 09/07/2006

ID

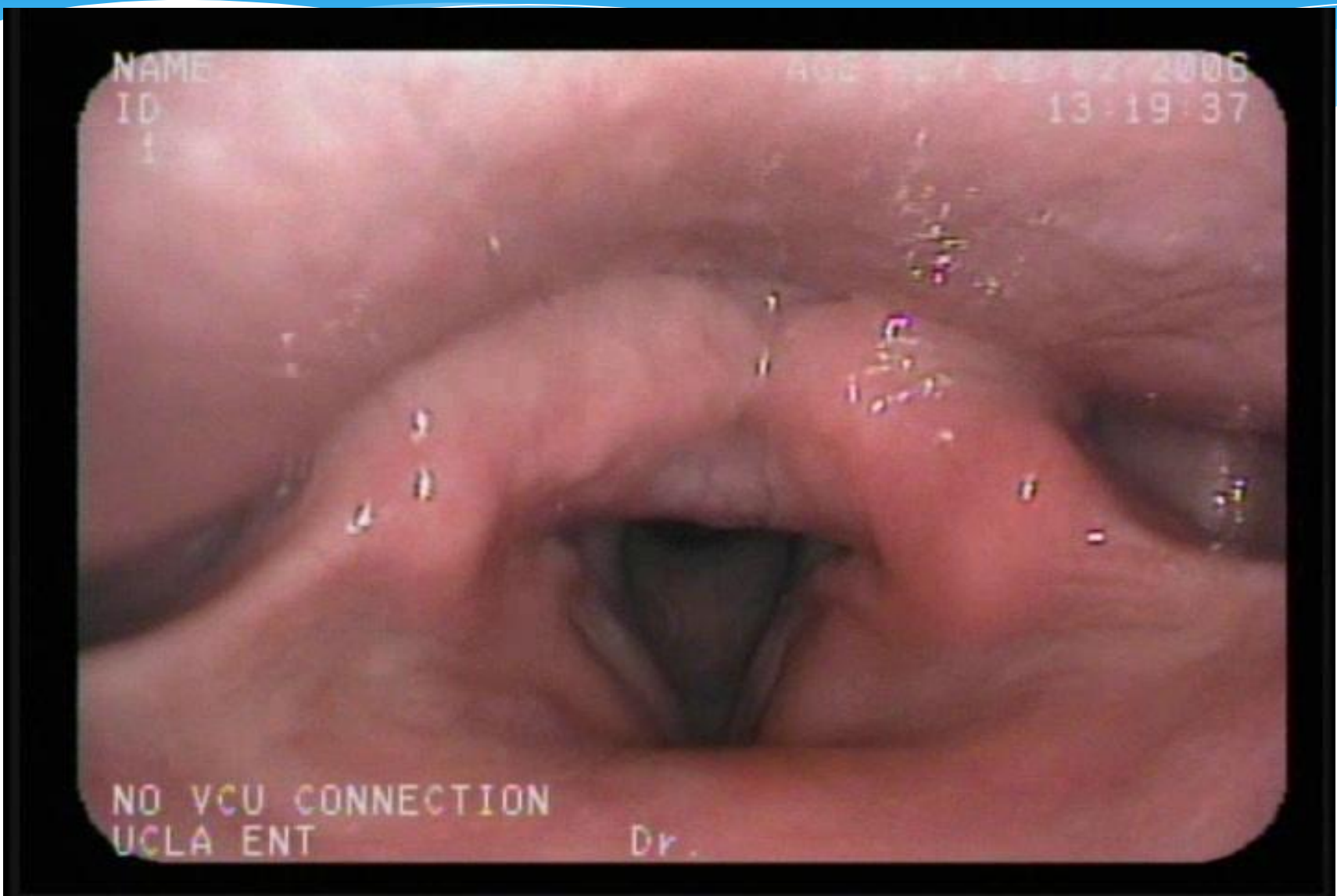
13:19:37

1

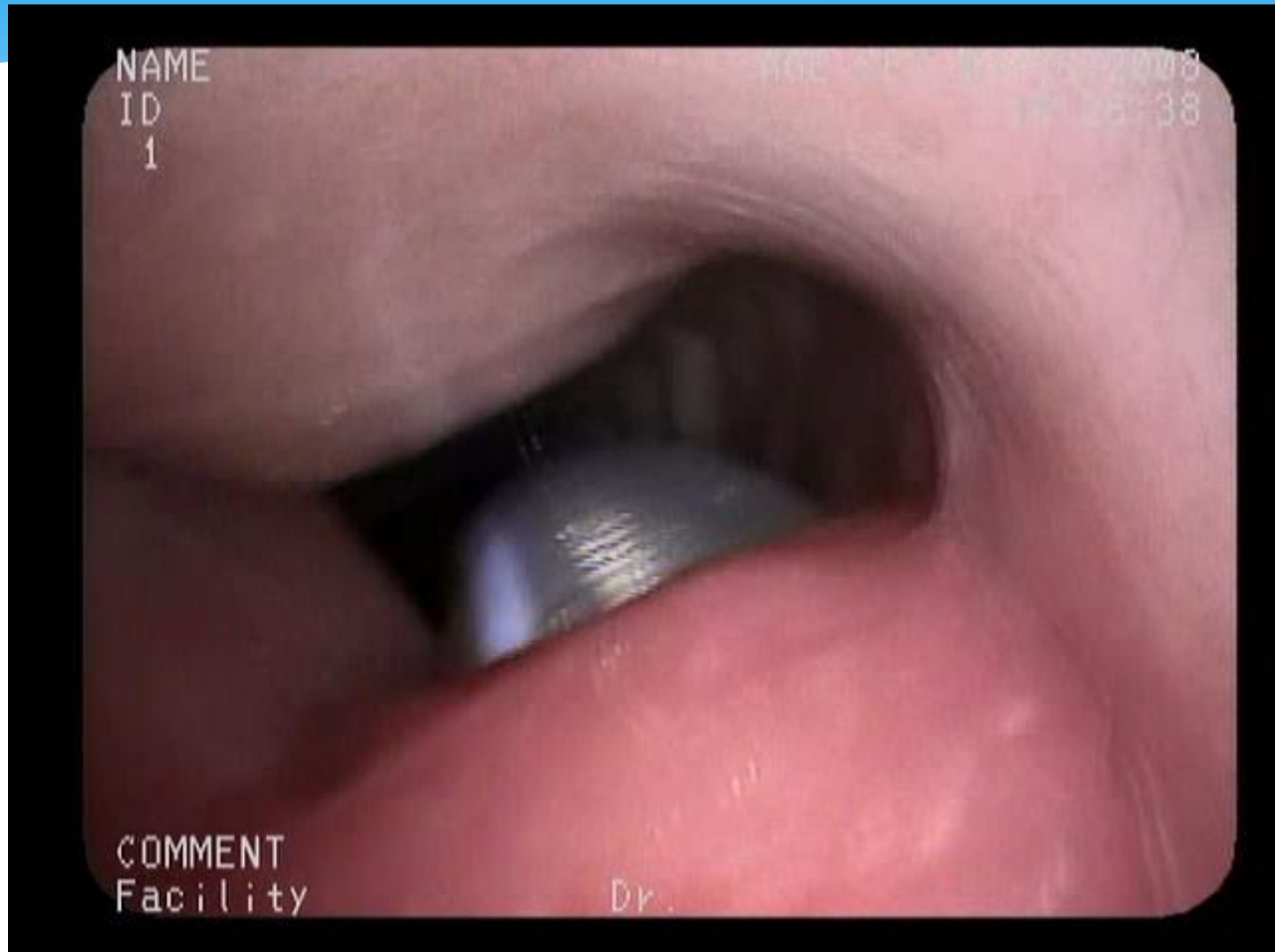
NO VCU CONNECTION

UCLA ENT

Dr.



Not all stenosis need to be treated!



Treatment of Laryngotracheal Stenosis

- * Endoscopic
 - * Laser
 - * Dilation
 - * ± Steroid injection, Mitomycin-C application
- * Open Surgical
 - * Primary resection and anastomosis
 - * Laryngotracheoplasty (LTP)
 - * Grafts (cartilage, mucosa)
 - * Stenting
 - * Single stage versus multistage

Supra glottic stenosis treatment

trans hyoid pharyngotomy;

- * horizontal skin incision(hyoid bone)
- * if hyoid # (reduced& fixed, removed)
- * vallecula entered.
- * adhesion of epiglottis to post / lat wall
 - * division along long axis.
 - * sub mucosal excision of scar.
 - * primary mucosal closure.
- * horizontal web
 - * vertical incision – scar excised.
 - * mucosal flaps undermined- horizontal line closure

Supra glottic stenosis treatment

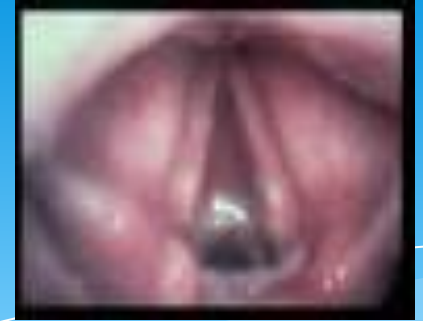- * In case of extensive mucosal defect – skin graft.
- * Full thickness loss – radial forearm flap.
- * In case of post displacement of hyoid/ epiglottic cartilage,
laryngofissure
 - * base of epiglottis identified.
 - * ant fascia, perichondrium ,& epiglottis incised inverted V shape.
 - * Mucoperichondrium of epiglottis elevated superiorly.
 - * Scar tissue ,base of epiglottis excised
 - * Mucoperichondrium incised & flaps turned outward and sewn to ant epiglottis
 - * Thyrotomy closed.

Glottic stenosis

Ant glottic stenosis;

- * external trauma/ post intubation.
 - * thyroid cartilage #/ mucosal disruption
- * two opposing raw surfaces heals by fibrosis
- * thin/ thick web – hoarseness/ airway compromise.
- * successful repair requires physical separation of opposing edge until epithelialization is complete.

Glottic stenosis



Ant glottic web ;

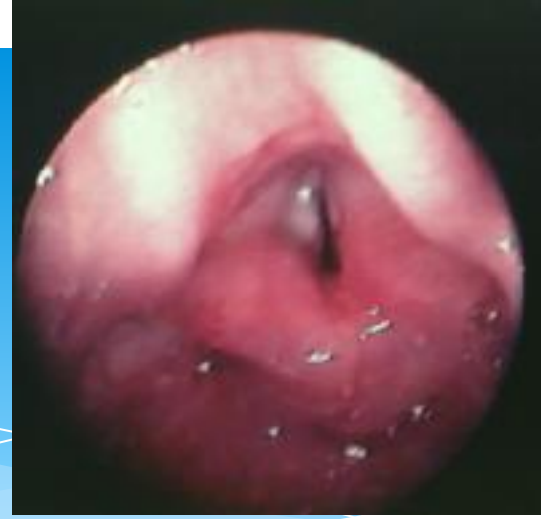- * MLS / CO₂ laser excision – keel insertion
- * keel inserted – endoscopically /mini cricho thyrotomy
- * Ideal keel ;
 - * stable, inert
 - * extension- cricho thyriod membrane to 2-3 mm above ant commissure.
 - * post wing at vocal process not in post commissure.
 - * if extends above petiole, angle should be 120[^].

Glottic stenosis

Ant glottic stenosis; external laryngo fissure

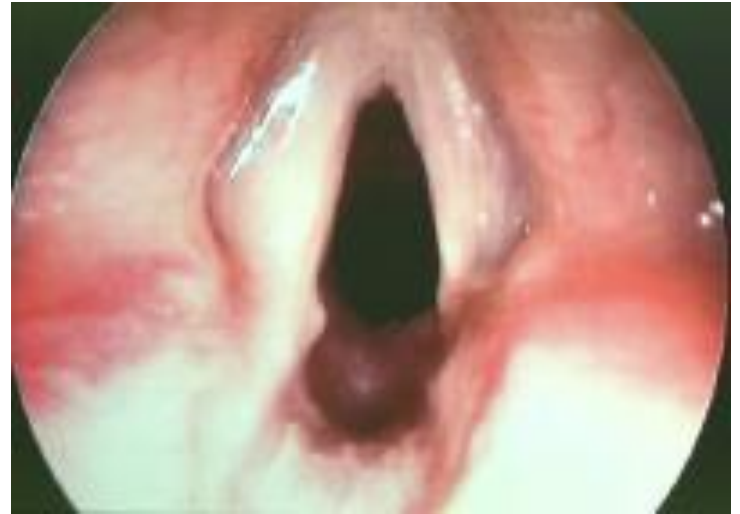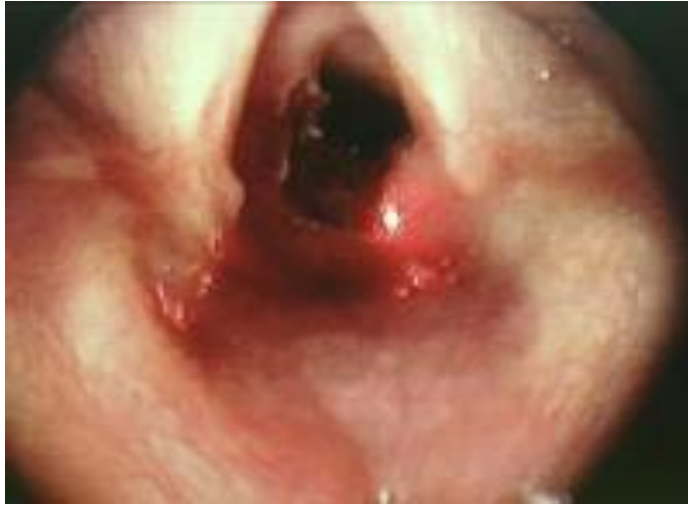- * indications;
 - * sub glottic extension >5 mm
 - * inlet stenosis.
 - * failed endoscopy.
- * scar excised preserving mucosa
- * mucoal defect- labial mucosal/ skin graft with short term stenting with montgomery tube/ Mc Naught tantalum keel.

Glottic stenosis



Post glottic stenosis;

- * cause – post intubation (most common)
 – cricho arytenoid joint arthritis.
- * repair
 - * endoscopic excision of web.
 - * Co2 laser.
 - * laryngofissure- submucosal excision of scar
 - * endoscopic laser arytenoidectomy (type 4)
 - * Post crichoid split with rib cartilage grafting.



Glottic stenosis

complete glottic stenosis;

- * laryngofissure (main stay of treatment)
 - * Stenosis divided at midline.
 - * scar excised preserving mucosa & developing mucosal flap from AEF.
 - * If extensive area is devoid of mucosa- grafting (buccal mucosa, septal mucosa, SSG,) is done.
 - * Graft sutured in place and stent kept.
 - * Stent removed at a later date.

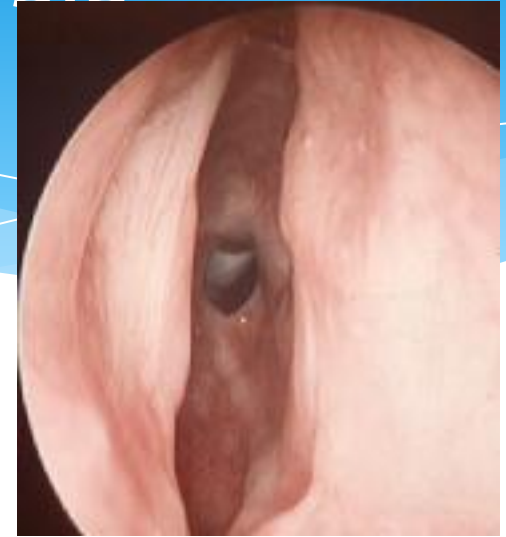
Glottic stenosis

Alternative approach;

Epiglottic flap

- * indication
 - * severe glottic stenosis with 50% reduction in A-P diameter of glottis.
- * midline thyrotomy
- * submucosal scar excision
- * base of epiglottis identified.
- * epiglottis pulled inferiorly to crichoid arch and sutured to thyroid (lat), crichoid (inferiorly).

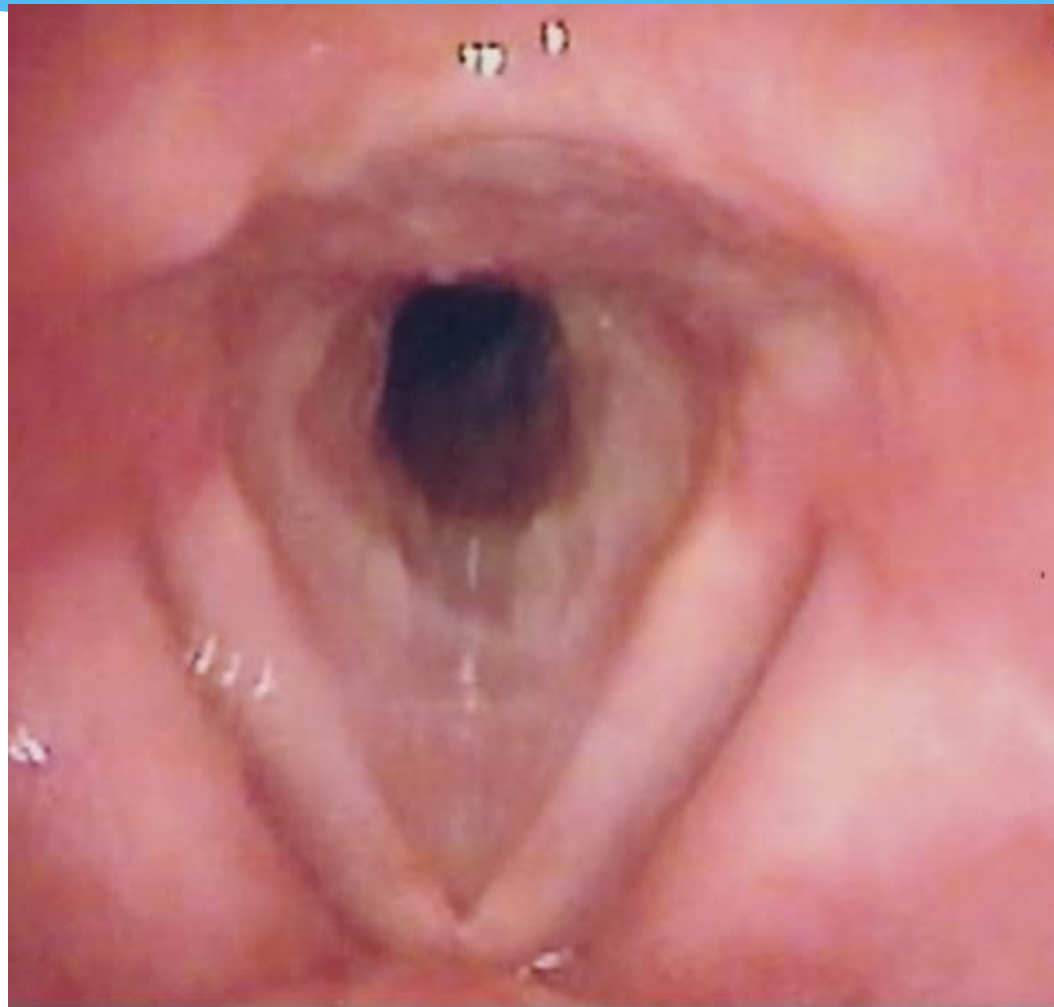
Subglottic stenosis



- * ENDOSCOPIC METHODS

- * Co2 laser
- * micro debrider.
- * Co2 laser excision and repair with micro trap door flap – circumferential sub glottic stenosis.
- * Radial incision at 12, 3, 6, 9 O' clock position – bronchoscopic dilatation.

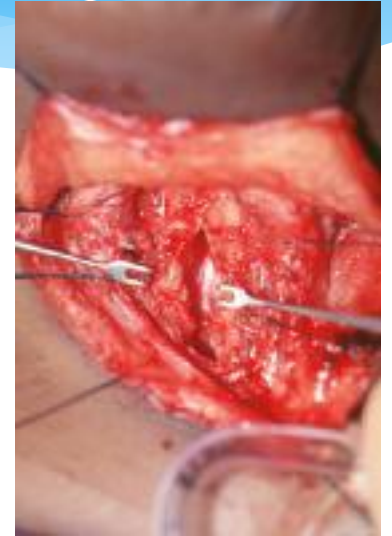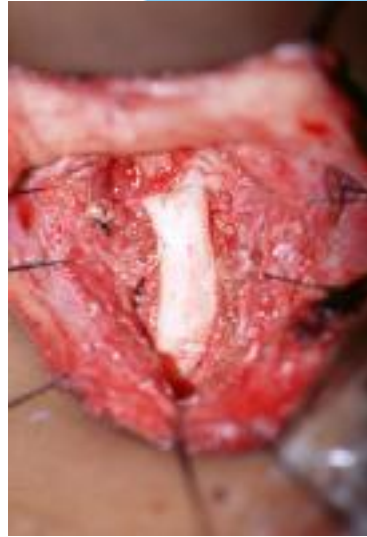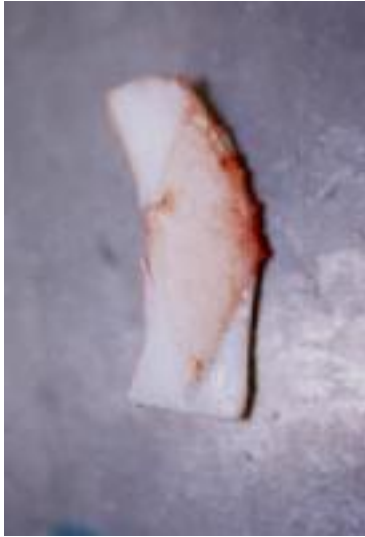Subglottic stenosis



Subglottic stenosis

EXTERNAL APPROACH;

- * scar resection and SSG grafting.
- * hyoid sterno hyoid muscle interposition graft .
- * thyroid sterno thyroid pedicle graft.
- * costal cartilage / septal cartilage grafting
- * post crichoid lamina split & internal rigid stenting.
- * partial cricoid resection with thyro tracheal anastomosis.
 - * risk RLN injury.
 - * need for laryngeal release.
 - * neck kept in complete flexion in post – op.



LTS IN PEDIATRIC AGE GROUP

ANATOMY;

- * situated at a higher level
- * funnel shape; midcricoid area 2-3 mm below cords narrowest.
- * small and narrow lumen.
- * mucosa has loose areolar tissue with abundant sub mucosal fluid.

LTS IN PEDIATRIC AGE GROUP

ETIOLOGY;

- * congenital
 - * cong sub glottic stenosis
 - * vocal cord paralysis
 - * sub glottic hemangioma
 - * laryngomalacia/ tracheomalacia.
- * acquired
 - * inflammatory
 - * neoplastic
 - * traumatic

LTS IN PEDIATRIC AGE GROUP

MANAGEMENT;

- * endoscopic
- * open techniques
 - * ant cricoid split
 - * laryngo tracheoplasty
 - * laryngo tracheal reconstruction
 - * crico tracheal resection and anastomosis

LTS IN PEDIATRIC AGE GROUP

POST OP MANAGEMENT;

- * antibiotic cover
- * anti reflux medication 6 wk
- * endoscopy- granulation removal
- * stent removal 6-8 wks

anastomotic complications;

- * granulations
- * stenosis
- * dehiscence

RESTENOSIS

PREVENTION;

- * steroids, mitomycin-c
- * anti reflux/ antibiotics
- * tissue engineering techniques
- * fetal fibroblasts transposition(IL6,8)
- * tissue engineered scaffolds (hyaluronic acid/ carboxy methyl cellulose)
- * marlex mesh tube covered with collagen sponge.

Thank you!
Jim

